Clinical and Experimental Rheumatology 2001; 19: 569-572.

Asymptomatic gastrocnemius muscle biopsy: An extremely sensitive and specific test in the pathologic confirmation of sarcoidosis presenting with hilar adenopathy

A.P. Andonopoulos
C. Papadimitriou
M. Melachrinou[1]
N. Meimaris
C. Vlahanastasi
A. Bounas
P. Georgiou

Department of Medicine and [1]Department of Pathology, University of Patras School of Medicine, Patras, Greece.

Andrew P.Andonopoulos, MD, FACP, Professor of Internal Medicine/ Rheumatology; Christos Papadimitriou, MD, Resident in Internal Medicine; Maria Melachrinou, MD, Assistant Professor of Pathology; Nicholas Meimaris, MD, Fellow in Rheumatology; Chrysavgi Vlahanastasi, MD, Fellow in Rheumatology; Andreas Bounas, MD, Attending Rheumatologist; Panagiotis Georgiou, MD, Attending Rheumatologist.

Please address correspondence and reprint requests to: Andrew P. Andonopoulos, MD, FACP, Professor of Internal Medicine and Rheumatology, University of Patras School of Medicine, Department of Medicine, Division of Rheumatology, 265 00 Rio, Patras, Greece.

Received on December 6, 2000; accepted in revised form on April 6, 2001.

© Copyright CLINICAL AND EXPERIMENTAL RHEUMATOLOGY 2001.

Key words: Sarcoidosis, gastrocnemius muscle biopsy, pulmonary function, serum angiotensin converting enzyme, erythema nodosum, gallium 67 scan.

ABSTRACT

Objective

To evaluate asymptomatic gastrocnemius muscle biopsy as a tool in the histologic confirmation of the diagnosis of sarcoidosis.

Methods

Twenty-two patients admitted over a 2-year period to our department with bilateral hilar adenopathy and a variety of symptoms compatible with sarcoidosis were studied prospectively. Besides a complete history and physical, serum angiotensin converting enzyme (SACE) determination, pulmonary function, slit lamp eye examination, PPD skin test, gallium 67 scan and gastrocnemius muscle biopsy were performed.

Results

The biopsy revealed non-caseating granuloma in all patients, confirming the diagnosis of sarcoidosis. No other patient in our department received this diagnosis over the 2-year period of the study. The procedure was well tolerated by all patients and almost zero morbidity was noted. Erythema nodosum was present in 68.2% of the patients, PPD was negative in all of them, SACE was elevated in 59.1% and pulmonary function was normal in the majority.

Conclusion

The impressive sensitivity of asymptomatic gastrocnemius muscle biopsy, its safety and ease of performance, along with the extreme rarity of muscle involvement by other granulomatous diseases included in the differential diagnosis, may render it the procedure of choice for the histologic confirmation of sarcoidosis presenting with hilar adenopathy.

Introduction

Although bilateral hilar adenopathy may be a classical initial presentation of sarcoidosis, a histologic confirmation of the diagnosis is still necessary in order to exclude with certainty the possibility of diseases such as lymphoma, tuberculosis, fungal infection, berylliosis and other conditions which may mimic this picture (1). Besides the lung, several other sites have been recommended as appropriate for obtaining biopsy tissue for the pathologic diagnosis of the disease (2), with various results regarding sensitivity and specificity.

In 1986, we proposed asymptomatic gastrocnemius muscle biopsy as a safe and easy procedure, offering a high diagnostic yield in cases of disease presenting with erythema nodosum and hilar adenopathy (3). However, this test has not gained the popularity that we had expected, not being mentioned in any major textbook dealing with this disease (1,4,5). Consequently, we decided to reiterate our proposal, since we are convinced that this biopsy site can offer a high yield at least equivalent to transbronchial biopsy, and much more sensitive and specific than the majority of other employed loci.

Materials and methods

Over a two-year period (May 1998 - April 2000), 22 patients were admitted to the Department of Medicine of our institution with bilateral hilar adenopathy on chest X-ray. They had been prompted to visit our outpatient clinic because of fever, dry cough, arthralgias, arthritis (mainly of the ankles), erythema nodosum or various combinations of these symptoms. One patient had presented with unilateral eye lid ptosis.

With the strong possibility of sarcoidosis as the most likely diagnosis, all of these patients, besides a complete history, physical examination and routine hematologic and biochemical profile, underwent a SACE determination, a tuberculin skin test, pulmonary function evaluation and slit lamp eye examination. A gallium 67 lung scan was done in 14 patients.

Gastrocnemius muscle biopsy, after informed consent, was performed in all the patients under local anesthesia. A vertical incision (~4 cm) was made at the middle of the calf and through that a piece of the gastrocnemius muscle (2-2.5 cm long and about 1 cm wide) was excised. Numerous sections at multiple levels of the muscle were employed.

The main parameters used for the evaluation of the respiratory function of the patients included FEV1 (i.e. forced expiratory volume in one second), FVC (forced vital capacity), the ratio FEV1/

Table I. The demographic and clinical features of the study population.

Pt.	Age	Sex	Fever	Cough	Palpable adenopathy	Erythma nodosum	Arthritis	Alkaline phosphatase	Ca	Serum globulin	PPD	Pulmonary function	Eye exam	Ga 67 scan	SACE	Additional biopsy
1	60	F	-	-	+	+	-	N	N	≠		N	N	+	N	LN (+)
2	30	F	-	-	-	-	+	N	N	N	-	N	N	+	N	ND
3	34	F	+	+	-	+	+	N	≠	≠	-	N	N	+	≠	ND
4	18	M	+	+	-	+	-	≠	N	≠	-	R	N	ND	≠	BM(-)
5	35	F	-	-	-	+	+	≠	N	≠	-	O	N	ND	N	ND
6	60	F	-	-	-	+	-	≠	N	≠	-	N	N	+	≠	Lip (-)
7	37	M	+	+	-	+	+	≠	N	≠	-	N	N	+	≠	ND
8	30	F	+	-	-	+	+	N	N	≠	-	N	N	ND	N	ND
9	46	F	-	-	-	+	+	N	N	≠	-	N	N	ND	≠	skin (+)
10	53	F	+	-	-	-	+	N	N	≠	-	N	N	+	≠	ND
11	53	F	+	+	+	+	+	≠	N	N	-	R	N	ND	≠	LN (+)
12	42	M	+	-	+	+	+	N	N	N	-	N	N	+	N	LN (+)
13	67	M	-	+	+	-	+	N	N	≠	-	O	N	+	≠	LN (+)
14	29	F	+	-	-	+	+	≠	N	N	-	N	N	ND	N	ND
15	35	F	-	+	-	+	+	N	N	N	-	R	N	ND	≠	BM(-) lung (+)
16	78	F	-	+	+	-	-	≠	N	≠	-	N	N	+	≠	LN (+)
17	69	F	+	+	-	-	+	N	N	≠	-	N	N	+	≠	Lip (-)
18	29	M	-	-	-	+	-	N	N	N	-	N	N	ND	N	ND
19	36	F	+	-	+	+	+	N	N	N	-	R	N	+	N	ND
20	44	M	+	-	-	+	+	N	N	≠	-	N	N	+	≠	ND
21	39	F	-	-	-	-	-	N	N	N	-	N	N	+	N	ND
22	65	M	-	-	-	-	+	N	N	N	-	N	N	+	≠	ND

F: female; M: male; N: normal, ND: not done, R: restrictive, O: obstructive, BM: bone marrow, LN: lymph node.

FVC, TLC (total lung capacity, by the helium dilution technique), and DLCO (carbon monoxide diffusing lung capacity, by the single breath method). Abnormal values were considered: FVC below 80% predicted, TLC below 80%, a DLCO below 70%, and an FEV1/FVC below 70% predicted. These were based on the recommendations of Owens *et al.* (6) and the American Thoracic Society, the only exception being the consideration of DLCO as abnormal when it was below 70% predicted rather than 80%, for reasons previously described (7,8). A combination of decreased TLC and FVC was suggestive of restrictive lung disease (6, 8), while a decreased FEV1/FVC was suggestive of obstructive disease (6).

Results

Our population consisted of 7 male and 15 female patients with a mean age 45.0 ± 15.9 years (range between 18 and 78 years). Their demographic and clinical features are summarized in Table I.

Fever was present in 11 patients (50.0%), ankle arthritis with swelling, pain, erythema and painful but complete range of motion in 16 (72.7%), and erythema nodosum in 15 (68.2%). Xerophthalmia and xerostomia were reported by 3 individuals (13.6%), and dry cough by 8 of them (36.4%). None of the patients reported dyspnea on exertion, probably because all of them had stage I disease radiologically. Fatigue was quite common in most of the patients. Cervical adenopathy was found in 6 patients (27.3%). Pulmonary function testing revealed mild restrictive disease in 4 (18.2%), mild obstructive disease in 2 (9.1%), and was normal in the remaining. Slit lamp eye examination showed no abnormality in the whole group. A tuberculin skin test was not reactive in any of the study individuals. Serum alkaline phosphatase was elevated in 7 patients (31.8%), calcium in one, whereas polyclonal hypergammaglobulinemia was seen in 14 patients (63.6%). Serum angiotensin converting enzyme was elevated (for the most part mildly) in 13 patients (59.1%). Gallium 67 scan was performed in 14 individuals and disclosed increased radioactive uptake in the hilar area bilaterally in all of these patients, and in the lacrimal and parotid glands in 3, despite the absence of clinically detectable enlargement of these glands.

Biopsy of the asymptomatic gastrocnemius muscle performed under local anesthesia disclosed non-caseating granuloma in all of the patients (100.0%), confirming the diagnosis of sarcoidosis (Fig. 1). It is worth noting that in two patients the biopsy was initially reported as negative, and after insistence by the clinician, recutting of the specimen, and the careful examination of deeper sections, the granuloma became apparent. It should be mentioned that all the patients tolerated the procedure very well, with only minor local discomfort initially, followed by prompt uneventful healing.

Ten of our patients had additional biopsies, as can be seen in the last column of Table I. All 5 of those obtained from palpable lymphnodes were positive for sarcoidosis, as were one of a sarcoid skin lesion and another from the lung transbronchially. In contrast, neither of

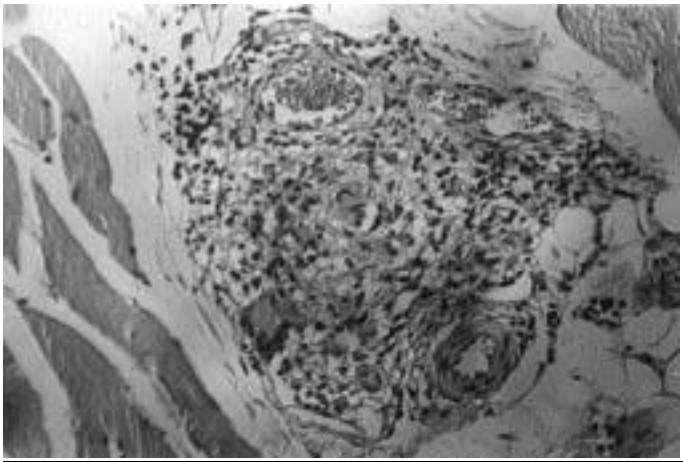

Fig. 1. Gastrocnemius muscle biopsy (HE x 200). Longitudinal section showing a sarcoid noncaseating granuloma, composed of an aggregate of epithelioid cells surrounded by small lymphocytes. A multinucleated giant cell is seen at the periphery of the sarcoid granuloma. Several small vessels are seen at the border of the lesion (case 2).

the biopsies obtained from bone marrow and neither of those from labial minor salivary glands disclosed granuloma.

Finally, we should mention that the diagnosis of sarcoidosis was not made in any other individual at our department during the entire 2-year study period.

Discussion

The diagnosis of sarcoidosis should be based on a compatible clinical picture and supplemented by the demonstration of non-caseating granuloma on biopsy material. Pathologic confirmation of the disease is necessary, since diseases such as lymphoma, tuberculosis, histoplasmosis and several others may produce similar clinical and radiologic findings (1).

It has been emphasized that tissue should be obtained preferentially from readily accessible lesions (2). This is not always easy, since the involved tissues may not be readily available for biopsy, requiring invasive procedures that may lead to significant morbidity and even mortality in rare cases (2). Biopsy of mediastinal lymphnodes or scalene fat biopsy may belong to this category, although they may disclose the granulomatous lesion in the majority of the cases (2, 9). On the other hand, other loci such as the bone marrow, conjunctiva and minor salivary glands offer little diagnostic yield (2, 10). Liver biopsy, although sensitive, may reveal granuloma in other diseases as well, such as tuberculosis, histoplasmosis and even Hodgkin's lymphoma (2). Transbronchial lung biopsy is positive in only 50-60% of patients who do not have roentgenographic evidence of parenchymal disease, the positivity increasing to 85-90% when radiologic parenchymal abnormalities are present (1), and may not always be the safest approach.

Several authors during the 1950s and 1960s reported their results of muscle biopsy from different sites in small numbers of patients (n = 1 to 5) with encouraging results (11-14). Wallace *et al.* in 1958 reported 19 positive muscle biopsies among 35 cases tested (15). In a previous study conducted by us in 1986 on 5 patients presenting with erythema nodosum and hilar adenopathy, we reported a positive result in 4 (3). The number of patients at that time was quite small, but we suggested that asymptomatic gastrocnemius muscle biopsy could be included in the list of the initial procedures to be employed for the pathologic confirmation of sarcoidosis.

In the present prospective study, all 22 of our patients with sarcoidodis manifesting as bilateral hilar adenopathy with other compatible clinical symptoms and signs, had a positive gastrocnemius muscle biopsy. The diagnostic yield of this procedure was impressively high in our series of patients in whom the disease manifested as bilateral hilar adenopathy, a very common mode of initial presentation in Caucasians (16), indicating the very high sensitivity of the test.

It need not be further emphasized here that the procedure is a very easy, simple and safe, with no morbidity.

Another important feature which enhances the specificity of this biopsy is the extreme rarity that other granulomatous diseases, which may mimic sarcoidosis clinically and radiologically, such as tuberculosis and fungal infections, involve the striated muscle (13, 14). Furthermore, caseation or other specific findings should be expected in these extremely rare cases, which should not be asymptomatic. Regarding lymphoma, primary muscle localization is very rare and symptomatic, but we are unaware of secondary asymptomatic muscle involvement by this group of malignant diseases, in which a muscle biopsy would be of help diagnostically. One could still argue that, in a typical case presenting with bilateral hilar adenopathy, a biopsy confirmation of sarcoidosis may not be necessary. This may be true for some asymptomatic patients, although even in them other diagnoses may be considered, necessitating pathologic confirmation (1). As a matter of fact, it has been clearly emphasized that "whether or not the presentation is classic, biopsy evidence of a mononuclear cell granulomatous inflammatory process is mandatory in order to make a definitive diagnosis of sarcoidosis" (5). In any case, our patients were not asymptomatic and it was because of their symptoms that they were studied in the hospital. Furthermore, although the aforementioned biopsy was employed only in patients who had presented with hilar adenopathy, we have no reason to believe that this procedure may not be helpful diagnostically in cases of the disease presenting in a different manner, and we recommend that it be performed.

Another point of extreme importance is the necessity to obtain numerous sections at multiple levels of the muscle in order not to miss the granuloma. As was mentioned, in 2 of our patients this could have happened if we had not insisted on detailed examination of the tissue. We would venture to say that the one out of the 5 patients in our initial report in 1986 with a negative biopsy might have had a positive result if we had examined the tissue specimen more closely. In order to give an idea of the importance of the above, it is worth

providing information about the size and incidence of the granulomatous lesions within the biopsy sections. In Figure 1, for example, the actual size of the muscle is 0.5 x 0.8 cm and, within this, two granulomas were detected, one measuring 0.234 mm (Fig. 1) and another 0.257 mm.

In conclusion, on the basis of its safety, ease of performance and very high sensitivity and specificity, we recommend asymptomatic gastrocnemius muscle biopsy as the initial procedure of choice for histologic confirmation of a diagnosis of sarcoidosis presenting with bilateral hilar adenopathy.

References

1. FANBURG BL, LAZARUS DS: Sarcoidosis. *In* MURRAY JF and NADEL JA (Eds.): *Textbook of Respiratory Medicine*. Philadelphia, W.B. Saunders 1994: 1873-88.
2. ISRAEL HL, SONES M: Selection of biopsy procedures for sarcoidosis diagnosis. *Arch Intern Med* 1964; 113: 255-60.
3. ANDONOPOULOS AP, ASIMAKOPOULOS G, MALLIORIS C, KARATZA C, SKOPA C: The diagnostic value of gastrocnemius muscle biopsy in sarcoidosis presenting with erythema nodosum and hilar adenopathy. *Clin Rheumatol* 1987; 6: 192-6.
4. PUERINGER RJ, HUNNIGHAKE GW: Sarcoidosis. *In* STEIN JH (Ed.): *Internal Medicine*. St Louis, Mosby 1994: 1692-7.
5. CRYSTAL RG: Sarcoidosis. *In* ISSELBACHER KJ, BRAUNWALD E,WILSON JD, MARTIN JB, FAUCI AS, KASPER DL (Eds.): *Harrison's Principles of Internal Medicine*. New York, McGraw Hill 1994: 1679-84.
6. OWENS GR, FINO GJ, HERBERT DL *et al.*: Pulmonary function in progressive systemic sclerosis. *Chest* 1983; 84: 546-50.
7. HYLAND RH,GORDON DA,BRODER I *et al.*: A systemic controlled study of pulmonary abnormalities in rheumatoid arthritis. *J Rheumatol* 1983; 10: 395-405.
8. ANDONOPOULOS AP, CONSTANTOPOULOS SH, GALANOPOULOU V, DROSOS AA, ACRITIDIS NC, MOUTSOPOULOS HM: Pulmonary function of non-smoking patients with systemic lupus erythematosus. *Chest* 1988; 94: 312-5.
9. MORGAN JW, SCOTT SM: A critical appraisal of scalene fat pad biopsies. *J Thorac Cardiov Surg* 1962; 43: 548-51.
10. GIOTAKI H, CONSTANTOPOULOS SH, PAPADIMITRIOU CS, MOUTSOPOULOS HM: Labial minor salivary gland biopsy: a highly discriminatory diagnostic method between sarcoidosis and Sjögren's syndrome. *Respiration* 1986; 50: 102-7.
11. MYERS GB, GOTTLIEB AM, MATTMAN PE, ECKLEY GM, CHASON JL: Joint and skeletal manifestations of sarcoidosis. *Am J Med* 1952; 12: 161-9.
12. POWELL LW JR: Sarcoidosis of skeletal muscle. Report of 6 cases and review of the literature. *Am J Clin Pathol* 1953; 23: 881-9.
13. PHILLIPS RW, PHILLIPS AM: The diagnosis of Boeck's sarcoid by skeletal muscle biopsy. *Arch Intern Med* 1956; 98: 732-6.
14. SILVERSTEIN A, SILTZBACH LE: Muscle involvement in sarcoidosis. *Arch Neurol* 1969; 21: 235-41.
15. WALLACE SL, LATTES R, MALIA JP, RAGAN C: Muscle involvement in Boeck's sarcoid. *Ann Intern Med* 1958; 48: 497-511.
16. JOHNS CJ: Sarcoidosis. *In* THORN GW, ADAMS RD, BRAUNWALD E, ISSELBACHER KJ, PETERSDORFRG (Eds.): *Harrison's Principles of Internal Medicine*. New York, McGraw-Hill 1977: 1119-24.