Case report

Synovial histology in three Behçet's disease patients with orthopedic surgery

Y. Nanke, S. Kotake, S. Momohara, M. Tateishi, H. Yamanaka, N. Kamatani

Institute of Rheumatology, Tokyo Women's Medical University, Tokyo, Japan.

Yuki Nanke, Shigeru Kotake, Shigeki Momohara, Mutsuto Tateishi, Hisashi Yamanaka and Naoyuki Kamatani.

Please address correspondence and reprint requests to: Dr. Yuki Nanke, Institute of Rheumatology, Tokyo Women's Medical University, 10-22 Kawada-cho, Shinjuku-ku, Tokyo 162-0054, Japan.
E-mail: ynn@ior.twmu.ac.jp

Received on October 12, 2001; accepted in revised form on February 14, 2002.

Clin Exp Rheumatol 2002; 20 (Suppl. 26): S35-S39.

© Copyright CLINICAL AND EXPERIMENTAL RHEUMATOLOGY *2002.*

Key words: Pathology, synovitis, Behçet's syndrome.

ABSTRACT

Specimens of synovial tissues from 5 affected joints of 3 patients with Behçet's disease were available for histopathological examination. All specimens were infiltrated by lymphocytes and neutrophils, and exhibited marked vascularity and infiltration of lymphoid cells among the vessels. Marked plasma cell infiltration and lymphoid follicle formation were found in one synovial tissue sample. There was no evidence of infection or vasculitis. These findings suggest that the histopathological characteristics of synovial tissue in Behçet's disease may have a wide range, some of which may even resemble the synovial tissue of rheumatoid arthritis.

Introduction

The joint symptoms of Behçet's disease have been well documented (1-3) although the pathology of the synovial tissue of Behçet's disease has only been described in a few cases (4-7). Here we report the pathological findings of synovial tissues from 5 affected joints of 3 patients: the knee, wrist, and elbow joints from one patient and the knee and ankle from 2 other patients, respectively. We demonstrate the pathological features of synovitis in synovial tissues from patients with Behçet's disesase.

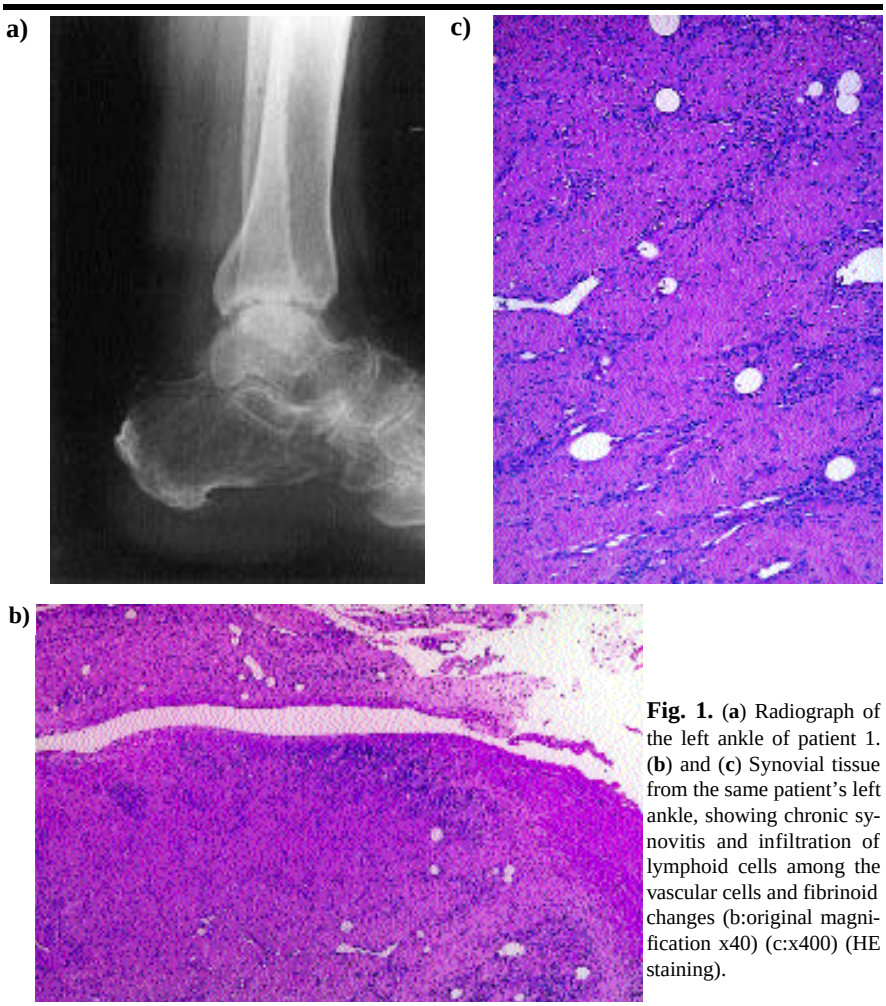

Fig. 1. (**a**) Radiograph of the left ankle of patient 1. (**b**) and (**c**) Synovial tissue from the same patient's left ankle, showing chronic synovitis and infiltration of lymphoid cells among the vascular cells and fibrinoid changes (b:original magnification x40) (c:x400) (HE staining).

Cases

Patient 1

A 51-year-old Japanese woman was admitted to our hospital for left ankle artherodesis in 1998. She had a history of oral and genital ulcers when she was 22 years old. In 1986, she presented bleeding from ulcers of the small intestine, and complained of polyarthralgia. She was finally diagnosed as having Behçet's disease (incomplete type) based on the Behçet's Disease Research Committee Criteria (8), and was treated with oral prednisolone (15 mg/day). In 1997 her arthralgia became worse. She developed intermittent claudication because of pain in the left ankle. During the clinical course there were no eruptions or ophthalmic complications.

On admission there were no ulcers, bleeding eruptions or neurological deficit. She had polyarthritis in the left ankle, both wrists and fingers. Laboratory studies revealed an erythrocyte sedimentation rate (ESR) of 23 mm in the first hour. The total white blood cell count (WBC) was 6,300/mm^3, hemoglobin 11.6 g/dl, liver and renal functions were normal. Serum CRP 0.3 mg/dl, rheumatoid factor and ANA were negative. HLA type are A2, A24 (9), B (7), B (46), CW (1), CW (7), DR (1), DR (8) and DQ (1). A radiograph of the left ankle revealed narrowing of the joint space (Fig. 1a). Artherodesis was performed. Histological studies of synovial tissue revealed non-specific chronic synovitis and infiltration of lymphoid cells among the vascular cells and fibrinoid changes. There was no sign of vasculitis. However, these findings were clearly different from the histological findings in synovial tissues from OA patients (Fig. 1 b,c) (HE staining).

Patient 2

A 33-year-old woman had been diagnosed as having Behçet's disease (incomplete type) (8) 12 years ago because of oral and genital ulcers and deep vein thrombosis. The patient had complained of polyarthritis and morning stiffness since 1984, and was treated with NSAIDs. In October 1989, she was diagnosed as having neuro-Behçet's disease based on glove-stocking type neuropathy and disorientation and was treated with Vitamin B12. She had neither eruptions nor ophthalmic complications. In July 1997 the patient underwent a Darrach's procedure in another hospital (Fig. 2a). Histopathological findings showed neither lymphoid follicle formation nor plasma cells, although some neutrophils and lymphocytes were detected (Fig. 2b,c) (HE staining).

On admission the patient presented with oral and genital ulcers, and polyarthritis involving the right wrist, left knee, right elbows and proximal interphalangeal joints of the fingers. Clinical data were as follows: ESR 51 mm/h, WBC 7980/mm^3, hemoglobin 11.2 g/dl, serum protein 7.9 g/dl (-globulin 22%), CRP 3.4 mg/dl, and normal liver and renal function. Rheumatoid factor and ANA were negative. Radiography revealed joint space narrowing of her right elbow (Fig. 3a) and left knee (Fig. 4a). She had been treated with loxoprofen sodium. Since the swelling of her elbow and knee continued, synovectomy of these joints was performed in July and August in 1998, respectively. Histological findings of the synovial tissue from the elbow showed hyperplasia of the synovial lining cells and infiltration with numerous lymphocytes and plasma cells. In addition, lymphoid follicle formation was also observed. There was no vasculitis (Fig. 3 b,c) (HE staining). Synovial tissue from the knee showed hyperplasia of the synovial lining cells, and infiltration of lymphoid cells along the vascular. There was no vasculitis seen. In addition, these findings differed from the histological features of OA patients (Fig. 4 b,c) (HE staining).

Patient 3

A 47-year-old woman had been diagnosed as having Behçet's disease 27 years earlier. At the age of 20 she had uveitis,and underwent surgery for peritonitis. At 34 years of age erythema nodosum and oral and genital ulcers appeared, and a pathergy test was positive. At 39 years of age she had arthritis of the left knee, proximal interphalangeal joints and hips. Clinical data were as follows: ESR 100 mm/h, WBC 7100/mm^{3,} hemoglobin 7.1 g/dl, serum protein 8.2 g/dl (-globulin 34%) and CRP 3.0 mg/dl; liver and renal function were normal. Rheumatoid factor and ANA were negative. Radiography revealed narrowing of the joint space and bone atrophy (Fig. 5a,b). Synovectomy was performed in the knee. Histopathological findings showed hyperplasia of the lining cells, infiltration of inflammatory cells and marked vascularity (Fig. 5 c,d) (HE staining).

Discussion

Joint manifestations are present in 40-75% of cases of Behçet's disease (1-3). According to the retrospective review of 340 cases by Benamour *et al.*, joint involvement is the first manifestation of Behçet's disease in 18.2% (1). The knees,ankles, wrist and elbows are frequently affected, while involvement of the small joints in the hands and feet is less common. Most cases are monoarthritis or oligoarthritis and usually run an acute or recurrent course (2,3,7). Polyarthritis and the chronic form are rare. In addition,the arthritis associated with Behçet's disease is usually non-deforming. Furthermore, it has been argued that permanent joint deformity is not seen even when arthritis has been present for many years (9, 10).

However, joint deformities and destruction have been reported in a few cases. Vernon-Roberts *et al.* reported that 2 of 6 patients with Behçet's disease had radiologically erosive change (4). In the current study, patient 1 had polyarthritis (both ankles, wrists and proximal interphalangeal joins) in 1976 and severe recurrent pain in the ankle for 20 years and had undergone surgery because of intermittent claudication. Radiographs of the ankle revealed sclerotic joint space and osteoporotic changes. Patient 2 also had polyarthritis in the right wrist and elbow, left knee and ankle and proximal interphalangeal joints for several years, i.e. the chronic form, and radiographs revealed joint space narrowing in the right hand and elbow and the left knee. Patient 3 also had chronic polyarthritis. Radiograph revealed bone atrophy and ankylosis of the left knee, erosive changes of the proximal interphalangeal joints, and bone destructive changes in the wrists. Thus, since all 3 patients had chronic poly-

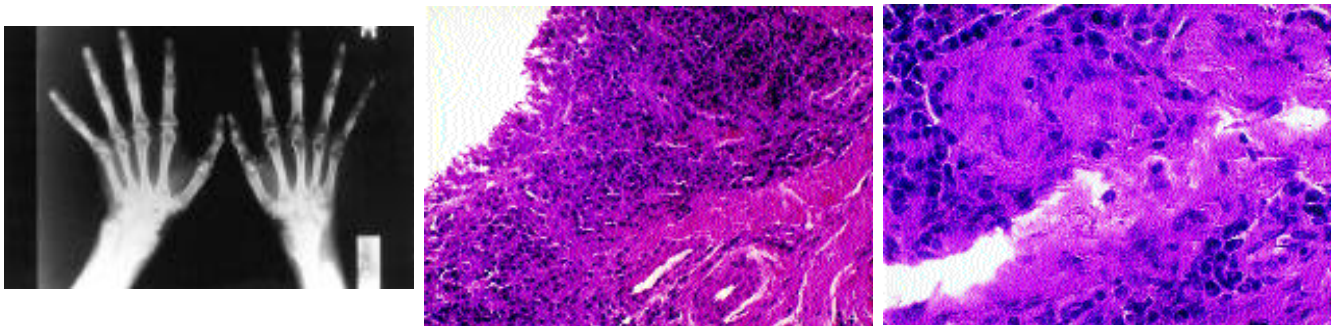

a) b) c)

Fig. 2. (**a**) Radiograph of the wrist in patient 2. (**b**) and (**c**) Synovial tissue from the patient's wrist; some neutrophils and lymphocytes can be seen. (b:x40) (c: x400) (HE staining).

a) b) c)

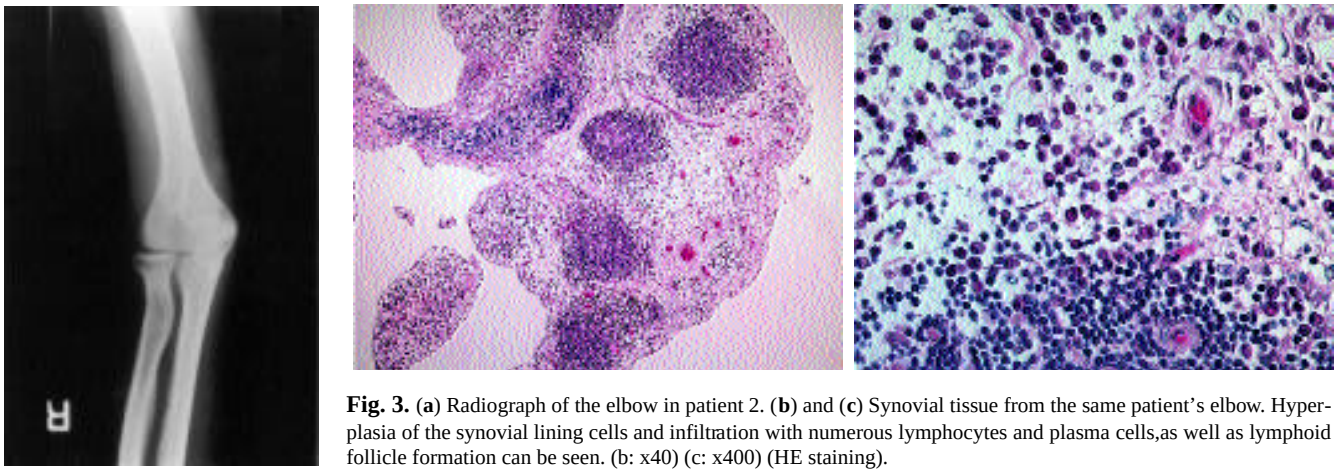

Fig. 3. (**a**) Radiograph of the elbow in patient 2. (**b**) and (**c**) Synovial tissue from the same patient's elbow. Hyperplasia of the synovial lining cells and infiltration with numerous lymphocytes and plasma cells,as well as lymphoid follicle formation can be seen. (b: x40) (c: x400) (HE staining).

a) b) c)

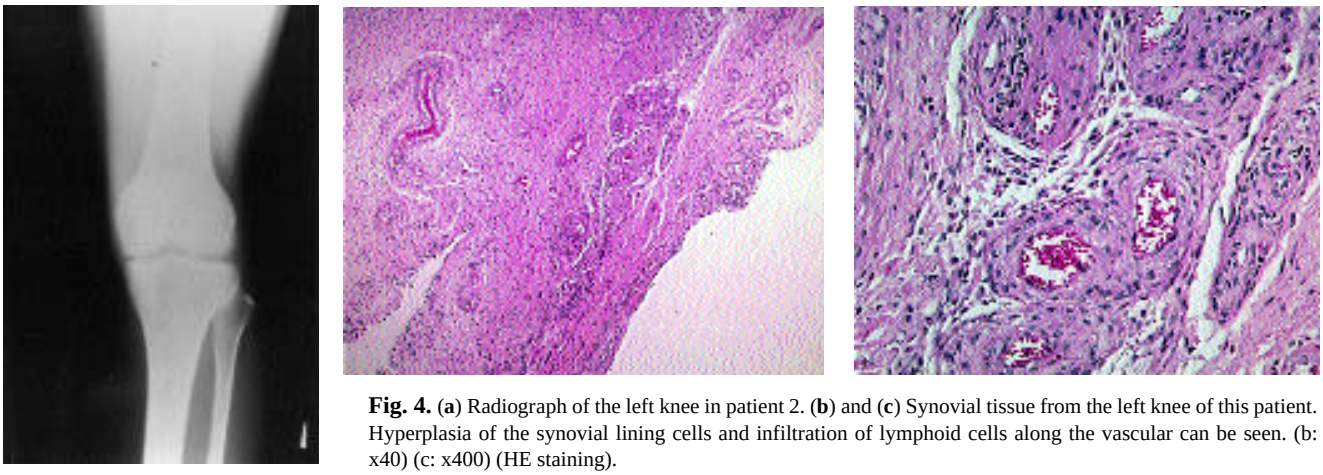

Fig. 4. (**a**) Radiograph of the left knee in patient 2. (**b**) and (**c**) Synovial tissue from the left knee of this patient. Hyperplasia of the synovial lining cells and infiltration of lymphoid cells along the vascular can be seen. (b: x40) (c: x400) (HE staining).

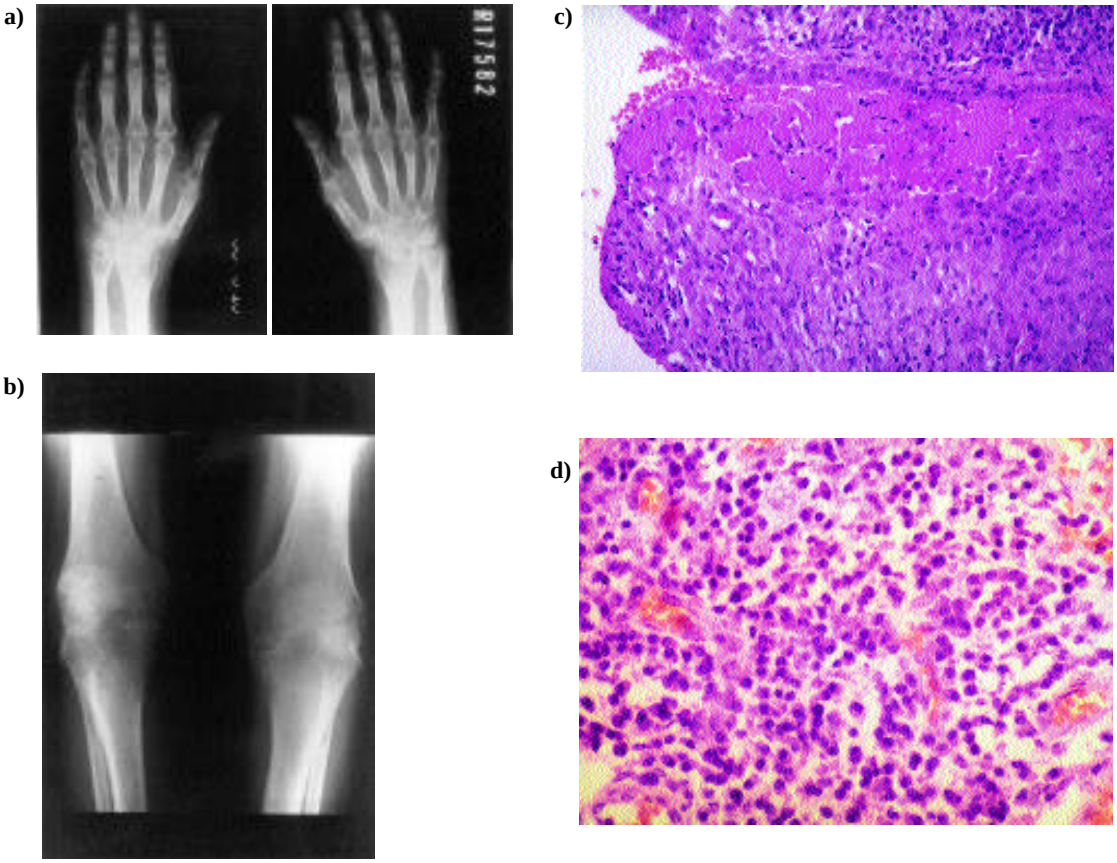

Fig. 5. (**a**) Radiograph of the hand in patient 3. (**b**) Radiograph of the patient's knee. (**c**) and (**d**) Synovial tissue from patient 3's knee. Hyperplasia of the lining cells,infiltration of inflammatory cells and marked vascularity can be seen. (b: x40) (c: x400) (HE staining).

arthritis and one of the 3 had destructive changes, the joint manifestations of these patients are unusual.

Clinical inflammatory changes were seen in all of the synovial tissue samples from 5 joints of the 3 patients with Behçet's disease. There have been a few reports on synovial histology in Behçet's disease (4-6). Yuradakul *et al.* reported loss of the superficial cell layer and replacement of synovial lining cells by granulation tissue (6). Vernon-Roberts *et al.* also indicated that only the superficial zones of the synovial tissue were affected and that 7 of 8 specimens were replaced by dense inflamed granulation tissue composed of lymphocytes mixed with macrophages, vascular elements, fibroblasts, and neutrophils (4). In addition, only 1 of 8 specimens demonstrated marked plasma cell infiltration and lymphoid follicle formation. They indicated that ulceration and replacement of the superficial zone of the synovial tissue by heavily inflamed granulation tissue, without involvement of the deeper layers and in the absence of infection, might be characteristics of Behçet's disease.

In our study not only the superficial zone, but also the deeper layer was affected by inflammatory changes; all specimens were infiltrated with lymphoid cells, and vascular elements were increased. In patient 2 synovial tissue from the elbow and knee demonstrated marked inflammatory changes, massive plasma cells and many lymphoid follicle formations which are usually seen in the synovial tissue of patients with rheumatoid arthritis. Yurdakul reported 5 instances of lymphoid follicle formation among 12 synovial tissue samples (6). In addition, Gibson *et al.* (5) noted that synovial changes in Behçet's disease may be similar to those ob-

Table I. Summary of presenting features and clinical signs.

Case	Sex	Age	Disease duration	Presenting feature	Mouth ulcer	Genital ulcer	Eye lesion	Skin lesion	Others
1	F	51	30 yrs	arthritis	+	+	-	-	ulcers in small intestine
2	F	33	14 yrs	arthritis	+	+	-	-	deep vein thrombosis mononeuro multiplex
3	F	47	27 yrs	arthritis	+	+	+	+	peritonitis

Table II. Summary of radiographic findings and HLA.

Case	Radiographic loss of cartilage	Bone erosion	Rheumatoid factor	HLA	Involving joints
1	+	-	-	B-42, B-7	lt ankle, both hands, PIP
2	+	-	-	B-51	rt elbow, lt knee, hand
3	+	+	-	ND	lt knee, rt hip, PIP

served in early rheumatoid arthritis; they could not illustrate any distinct features of Behçet's synovial tissues, although immunofluoresent studies indicated the consistent deposition of IgG 2 which might be characteristic.

The appearance of the synovial tissues from patient 2 was different between the different joints. The synovial tissue from the wrist of the patient 2 showed neither lymphoid follicle formation nor plasma cells, although some neutrophils were detected. The elbow and knee instead had marked inflammatory changes as indicated above. Thus, the histopathological characteristics of synovial tissue in Behçet's disease may have a wide range even in one patient.

In summary, we demonstrate here the features of synovial tissues from patients with Behçet's disease. All synovial tissues were infiltrated with neutrophils, some of which exhibited marked vascularity. One of the synovial tissue samples even exhibited lymphoid follicle formation and marked plasma cell infiltration, which are usually seen in rheumatoid synovial tissues. There was neither infection nor vasculitis. The histopathological characteristics of synovial tissue in Behçet's disease may show a wide range, and even resemble the characteristics of synovial tissue from rheumatoid arthritis patients.

References

1. BENAMOUR S, ZEROUAL B, ALAOUI FZ: Joint manifestations in Behçet's disease, a review of 340 cases. *Rev Rhum* 1998; 299-307l.
2. SAKANE T, TAKENO M, INABA G: Behçet's disease. *N Engl J Med* 1999; 341: 1284-91.
3. MASON RM, BARNES CG: Behçet's syndrome with arthritis. *Ann Rheum Dis* 1969;28:95-103.
4. VERNON-ROBERTS B, BARNES CG, REVELL PA: Synovial pathology in Behçet's syndrome. *Ann Rheum Dis* 1978; 37: 139-45.
5. GIBSON T, LAURENT R, HIGHTON J, WILTON M, DYSON M, MILLIS R: Synovial histopathology of Behçet's syndrome. *Ann Rheum Dis* 1981; 40: 376-81.
6. YURDAKUL S, YAZICI H,TUZUN Y *et al.*: The arthritis of Behçet's disease: A prospective study. *Ann Rheum Dis* 1983; 42: 505-15.
7. DAWES P, RAMAN D, HASLOCK I: Acute synovial rupture in Behçet's syndrome. *Ann Rheum Dis* 1983; 42: 591-2.
8. BEHÇET'S DISEASE RESEARCH COMMITTEE OF JAPAN: Behçet's disease:Guide to diagnosis of Behçet's disease. *Jpn J Ophthalmol* 1974; 18: 291-4.
9. JAWAD A,GOODWILL C: Behçet's disease with erosive arthritis. *Ann Rheum Dis* 1986; 45: 961-2.
10. BEN-DOV I,ZIMMERMAN J: Deforming arthritis of the hands in Behçet's disease. *J Rheumatol* 1982; 9: 617-8.