New approaches to imaging of early rheumatoid arthritis

P.G. Conaghan, D. McGonagle, R. Wakefield, P. Emery

Rheumatology and Rehabilitation Unit, University of Leeds, Leeds, UK.

Philip G. Conaghan, MBBS, FRACP, Senior Lecturer; Dennis McGonagle, MBBch, BAO, MRCPI, Lecturer; Richard Wakefield, BM, MRCP, Research Fellow; Paul Emery, BA, MA, MBBChir, MD, FRCP, ARC Professor of Rheumatology.

Please address correspondence and reprint requests to: Prof. Paul Emery, Rheumatology and Rehabilitation Research Unit, University of Leeds, 36 Clarendon Road, Leeds LS2 9NZ, UK.

Clin Exp Rheumatol 1999; 17 (Suppl. 18): S37-S42.

© Copyright Clinical and Experimental Rheumatology 1999.

Key words:
Early rheumatoid arthritis, magnetic resonance imaging (MRI), sonography, x-ray, ultrasonography (US), dual x-ray absorptiometry (DXA).

ABSTRACT
Conventional radiology (CR) is a major tool for the diagnosis and assessment of early arthritis. However, CR does not image the primary pathology of rheumatoid arthritis (RA), i.e. the synovium, and is insensitive for radiological erosions. New techniques, particularly magnetic resonance imaging (MRI) and ultrasonography (US) have shown their potential to improve on the sensitivity of CR. This article reviews the current status of this approach in early disease.

Introduction

Conventional radiography (CR) has traditionally provided the marker for both diagnosis and disease therapeutic modification in rheumatoid arthritis (RA): the radiographic bony erosion. However, there are problems with the parameter of erosion in disease measurement: it is present in less than 40% of cases of early RA at presentation (1) and therefore has limited diagnostic utility, and discordance has been reported between clinical disease activity and erosion progression (2). The introduction of newer, multiplanar imaging modalities, such as magnetic resonance imaging (MRI) and ultrasonography (US), that have the ability to image both soft tissue and bone, has resulted in increasing knowledge about both the pathogenesis and treatment response in early RA.

Magnetic resonance imaging

The technology

A number of features have contributed to the increased use of MRI in rheumatology, including better access to scanners, the improved resolution of scanners, and rapid developments in the sequences used for evaluating different tissues. The principles of MRI have been simply explained elsewhere (3), but a brief description follows. The hydrogen protons in human tissues align when placed in an external magnetic field; this is termed longitudinal magnetisation. When excited by an external electromagnetic pulse, they acquire energy or resonance, with a consequent decrease in longitudinal magnetisation and an increase in transverse magnetisation. When this pulse is turned off, the protons will return to their previous low-energy state. The net movement of protons results in an electric current measured as the MR signal.

The appearances of particular tissues depends on their hydrogen proton content. When using common MRI sequences, a T1-weighted (T1W) image results in fat-containing tissues such as bone marrow having a high signal (Fig. 1). On T2W images, both fat and fluid have a high signal. Modern techniques of fat suppression can eliminate this high signal from fat (Fig. 2), thereby making sites of fluid and inflammation easily visible (Fig. 3). One of the tools used for evaluating synovitis is the paramagnetic agent gadolinium-diethylenetriaminepentacidic acid (Gd-DTPA). This agent shortens the relaxation times of adjacent tissues, thereby improving contrast, and its uptake depends on tissue vascularity and capillary permeability, hence identifying the sites of inflammation.

When comparing MRI studies in RA, it is useful to examine the magnet strength (measured in Tesla), the sequences performed (including whether axial or coronal views were included), and the anatomic sites studied, as these all vary considerably. It is also important conceptually to realise that CR shows bright bone because of the calcium content, whereas bright bone on T1W MRI images represents the bone marrow hydrogen content. Thus, "MRI erosion" is not the same pathogenic entity as CR erosion, although, as will be discussed below, they likely represent the same lesion at different points in time.

MRI and bony damage

A number of studies have demonstrated the superior sensitivity of MRI over CR to detect bony damage. Many of these reports involved short duration or early

Fig. 1. Coronal view of a normal hand using a T1-weighted SE sequence.

Fig. 2. Coronal view of a normal hand using a T2 fat-suppressed sequence. Note the low signal from bone marrow.

Fig. 3. Coronal view of the hand (T2 fat-suppressed sequence) from a rheumatoid arthritis patient showing inflammation (high signal) in the second to fourth metacarpophalangeal heads (*).

RA patients. McQueen *et al.* examined the carpus in 42 patients with RA of a mean duration of 4 months and found CR erosions in 15%, but MRI bony lesions in 45% (4). Jorgensen *et al.* found MRI erosions in 4 of 15 wrists with normal CR and a similarly short disease duration (5). Forslind *et al.* (6) demonstrated a marked superiority of the MRI erosion count over the CR erosion count at the knee, but only a small difference at the fifth metatarsophalangeal (MTP) joints, in 30 patients with a mean disease duration of 8 months. Using fat suppression sequences, we have reported (in abstract form only) CR and MRI findings in the second to fifth metacarpophalangeal (MCP) joints of early RA patients (7). Ten radiographic erosions were found in 116 joints examined, whereas MRI demonstrated more than 100 bony abnormalities. This observation highlights the capacity of fat-suppressed MRI to demonstrate areas of bone oedema, which are also demonstrated at the wrist in longer-duration disease (8). Studies in longer-duration RA have also demonstrated the greater sensitivity of MRI at the wrist, finger, and shoulder joints (9-11).

These studies in early disease highlight the fact that most patients with RA have bony abnormalities on MRI scanning at presentation. We have also demonstrated that the described MRI bony changes are seen only infrequently in normal controls (12) and seem relatively specific for RA, being less frequent in patients with polyarthritis who have a good prognosis (13).

MRI and synovitis

Synovitis appears to be the primary inflammatory event in RA. The best method to detect synovitis using MRI employs the intravenous contrast agent Gd-DTPA mentioned above. Gd-DTPA synovitis has been correlated with microscopic changes of inflammation in the RA knee, including cellular infiltrates, fibrin deposition, and vascular proliferation (14-16). One of these studies using arthroscopy also found correlations with macroscopic synovitis (15).

Different methods may be applied for quantitating synovitis, although again one must be careful when comparing studies using different measurement tools. Assessments may be performed either manually or using semi- or fully-automated software packages. Synovitis may be calculated from the total synovial volume (using multiple sections), from a single section, or from pharmacokinetic parameters such as the rate of Gd-DTPA enhancement or maximal Gd-DTPA enhancement (17-19).

MRI synovial volumes may be used to monitor the response to therapy. In the short term, studies of intraarticular corticosteroids in the knee indicate that MRI volumes are a sensitive measure of change in clinical disease activity (18, 20, 21). Similarly, we have demonstrated for early RA that MRI detects reductions in the MCP joint synovial volume after intraarticular corticosteroids (22). Newer studies have demonstrated the usefulness of MRI in the long-term follow-up of treatment (23).

MRI in the diagnosis and prognosis of RA

With studies demonstrating that Gd-enhanced MRI is more sensitive than clinical examination for both early RA (6, 7) and RA of longer duration (24), the possible role for MRI in the screening of early arthritis populations has been raised. There are few published studies in this area, however. One report indicated that addition of the MRI criteria of contrast-enhancing joints in both hands of RA (duration not stated) and non-RA patients to the classification tree format of the American College of Rheumatology criteria resulted in sensitivity and negative predictive values of 100% (25). Importantly, observations based on MRI have suggested two subgroups of inflammatory arthritis: a primary intrasynovial group and an entheseal-based group (26). The consequences of these findings will be relevant in defining MRI-based disease criteria.

Although CR-based studies have suggested an uncoupling of synovitis and bony damage, our MRI studies of early RA have suggested a more direct relationship with bone oedema secondary to synovitis detected as the earliest MRI bone change (12). This observation is supported by recent contrast-enhanced MRI studies demonstrating that baseline synovitis scores were highly correlated with subsequent CR damage at 6 and 12 months in both early (27) and more established disease (23, 28). These longer-term studies highlight the usefulness of MRI in assessing treatment response and raise questions regarding the definition of true remission.

Ultrasonography

The technology

Like MRI, changes in ultrasound technology have increased interest in this field for rheumatology, as reflected in recent editorials (29-31). US provides multiplanar imaging with real-time examination and a lack of ionising radiation - all-important advantages over CR. Improved microprocessors, faster digital imaging systems, and high-frequency (7.5 - 20 MHz) transducers have resulted in the clearer visualization of both bone and soft tissues.

The transducer is particularly important in image quality: in principle, the higher the frequency of the sonographic wave, the greater the resolution of image, but at the cost of reduced tissue penetration. Linear-array transducers are the most suited for examining linear structures because they emit parallel sonographic waves which, when applied perpendicularly to the structure, allow for maximum reflection. Importantly, the development of new, smaller transducers has allowed better access to the small joints. In general, musculoskeletal pathology results in reduced echogenicity within the target structure (see Figs. 4 and 5).

Ultrasonographic studies of RA

There are few published studies on US in RA (let alone early RA), and this lack of peer-reviewed studies, together with a lack of recognised guidelines for standardised joint examination and training, have hindered the more widespread use of US. However, recent abstracts presented at international meetings suggest that the area is developing rapidly.

In earlier studies, US was found to detect more synovial and bony pathology in established RA when compared to normal wrist and MCP joints (32, 33). Recent studies have concentrated on the validation of the technique and have compared US with arthroscopic and MRI findings. Rubaltelli *et al.* compared US

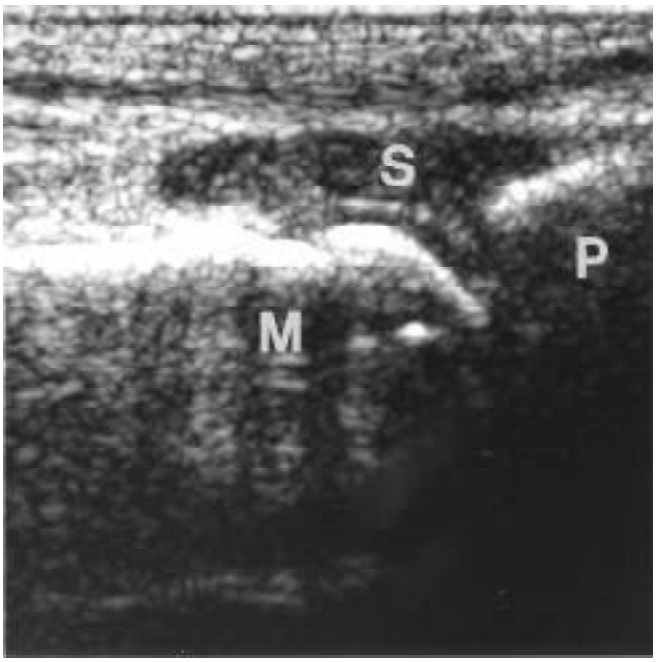

Fig. 4. Longitudinal section through a second metacarpophalangeal joint (**M** = metacarpal head, **P** = phalanx) showing synovitis (**S**) over the dorsal aspect of the joint.

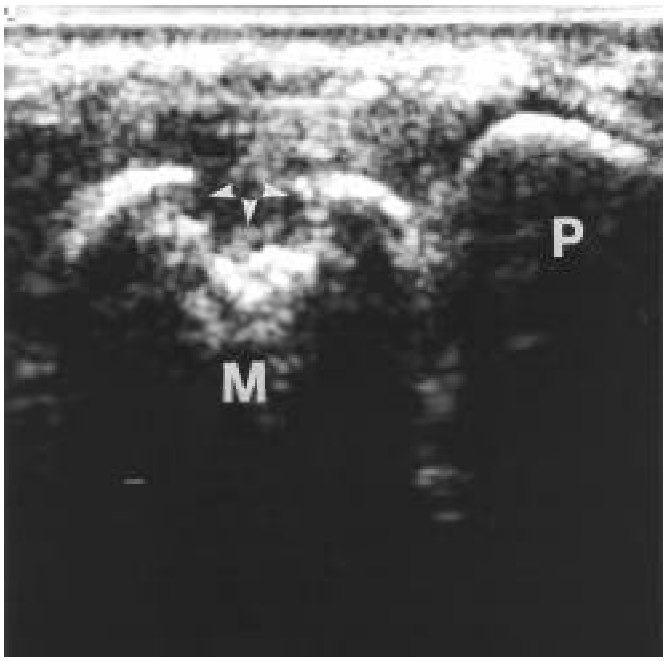

Fig. 5. Longitudinal section through a second metacarpophalangeal joint (**M** = metacarpal head, **P** = phalanx) showing a large erosion (**small arrowheads**) on the radial aspect of the metacarpal head.

synovial thickness with arthroscopic findings in 13 RA (and 14 psoriatic arthritis) knees and found good correlations for the suprapatellar and medial recess compartments (34). A Finnish group compared CR, MRI, computerised tomography (CT) and US for the detection of humeral head erosions, again in longstanding RA (35). They found MRI, CT, and US all to be more sensitive than CR, with MRI and US being superior to CT in detecting small erosions. US was the most sensitive tool for detecting erosions of the greater tuberosity, highlighting once again the benefits of multiplanar access.

In a recent report, Backhaus *et al.* have compared CR, MRI, scintigraphy, and US in the finger joints of 60 inflammatory arthritis patients, 36 of whom had RA (36). This study confirmed the sensitivity of MRI for detecting bony pathology and found that both US and MRI had high sensitivity for detecting synovitis. Ultrasonography was found to be more sensitive than MRI for the detection of synovitis, in contrast to other studies (7, 37). We have studied the MCP joints of early RA patients, comparing MRI and US, and found them to be equally sensitive in the detection of inflammatory changes (7).

The potential use of US in the evaluation of the therapeutic response remains exciting, but again there are little published data. Uncontrolled studies of small numbers of inflamed knees of established RA patients have demonstrated that US is useful in detecting longitudinal changes in both synovial thickening and effusions (38-40). Preliminary reports suggest that power Doppler, which can assess tissue hyperaemia more effectively than standard colour Doppler techniques, may also be useful for assessing longitudinal changes in synovial inflammation (41, 42). The sensitivity of power Doppler may be further enhanced by intravascular bubble contrast agents (43).

Other imaging modalities

Imaging modalities other than MRI and US may also have a role in early RA diagnosis and treatment monitoring. Hand bone mineral density (BMD) studies performed using dual x-ray absorptiometry (DXA) have demonstrated significant correlations between this and other sites, with loss of hand BMD occurring before systemic disease (44). Early loss of hand BMD in RA may be predictive of long-term BMD and functional outcome (45). Recent work from our group has suggested that loss of hand BMD may be specific to RA when compared with patients who have limited hand synovitis or arthralgias (46).

Preliminary reports suggest the usefulness of positron emission tomography (PET) scans in assessing the response to treatment in the knee and wrist joints of RA patients (47, 48). The latter of these reports, although describing only 2 patients, found a good correlation between the reduction in MRI synovial volume (post-corticosteroid) and a reduction in synovial metabolism as measured by PET with 18F-fluoro-2-deoxyglucose. Another area of modern imaging that offers great promise is the use of radiopharmaceuticals. A radiolabelled anti-E-selectin monoclonal antibody has been reported to localise to the inflamed joints of RA patients (49).

Conclusions

Imaging technology continues to change and is improving rapidly. New hardware, new software, and falling costs will enhance the usefulness and availability of both MRI and US. Automated synovitis estimations and the development of dedicated extremity scanners (50) will improve the usefulness of MRI to clinicians and clinical trialists. Well-designed vali-

dation studies are delineating the role for US in the diagnosis and monitoring of early RA, and its real-time advantages make it ideally suited for use in outpatient settings. The application of new imaging techniques to the early diagnosis and evaluation of the treatment response heralds an era in which rheumatologists will be able to better target and reduce synovitis and consequently improve RA patient outcomes.

References

1. PAIMELA L, HEISKANEN A, KURKI P, HELVE T, LEIRISALO-REPO M: Serum hyaluronate level as a predictor of radiologic progression in early rheumatoid arthritis. *Arthritis Rheum* 1991; 34: 815-21.
2. KIRWAN JR: The relationship between synovitis and erosions in rheumatoid arthritis. *Br J Rheumatol* 1997; 36: 225-8.
3. SCHILD HH: *MRI made Easy*. Berlin, H. Heenemann GmbH & Co, 1990.
4. MCQUEEN F, STEWART N, CRABBE J, ROBINSON E, YEOMAN S, TAN PL, MCLEAN L: Magnetic resonance imaging of the wrist in early rheumatoid arthritis reveals a high prevalence of erosions at four months after symptom onset. *Ann Rheum Dis* 1998; 57: 350-6.
5. JORGENSEN C, CYTEVAL C, ANAYA JM, BARON MP, LAMARQUE JL, SANY J: Sensitivity of magnetic resonance imaging of the wrist in very early rheumatoid arthritis. *Clin Exp Rheumatol* 1993; 11: 163-8.
6. FORSLIND K, LARSSON EM, JOHANSSON A, SVENSSON B: Detection of joint pathology by magnetic resonance imaging in patients with early rheumatoid arthritis. *Br J Rheumatol* 1997; 36: 683-8.
7. CONAGHAN PG, WAKEFIELD RJ, O'CONNOR P, GIBBON W, BROWN C, EMERY P: The metacarpophalangeal joints in early rheumatoid arthritis: A comparison of clinical, radiographic, MRI and ultrasonographic findings. *Ann Rheum Dis* 1999 (Suppl.): 28.
8. NAKAHARA N, UETANI M, HAYASHI K, KAWAHARA Y, MATSUMOTO T, ODA J Gadolinium-enhanced MR imaging of the wrist in rheumatoid arthritis: Value of fat suppression pulse sequences. *Skeletal Radiol* 1996; 25: 639-47.
9. GILKESON G, POLISSON R, SINCLAIR H, VOGLER J, RICE J, CALDWELL D, SPRITZER C, MARTINEZ S: Early detection of carpal erosions in patients with rheumatoid arthritis: A pilot study of magnetic resonance imaging. *J Rheumatol* 1988; 15: 1361-6.
10. CORVETTA A, GIOVAGNONI A, BALDELLI S *et al.*: MR imaging of rheumatoid hand lesions: Comparison with conventional radiology in 31 patients. *Clin Exp Rheumatol* 1992; 10: 217-22.
11. ALASAARELA E, SURAMO I, TERVONEN O, LAHDE S, TAKALO R, HAKALA M: Evaluation of humeral head erosions in rheumatoid arthritis: A comparison of ultrasonography, magnetic resonance imaging, computed tomography and plain radiography. *Br J Rheumatol* 1998; 37: 1152-6.
12. MCGONAGLE D, CONAGHAN PG, O'CONNOR P *et al.*: The relationship between synovitis and bone changes in early untreated rheumatoid arthritis - A controlled MRI study. *Arthritis Rheum* 1999; 42:1706-11.
13. MCGONAGLE D, GIBBON W, O'CONNOR P, PEASE C, GREEN M, RIDGWAY J, EMERY P: An anatomical explanation for good prognosis rheumatoid arthritis. *Lancet* 1999; 353: 123-4.
14. GAFFNEY K, COOKSON J, BLAKE D, COUMBE A, BLADES S: Quantification of rheumatoid synovitis by magnetic resonance imaging. *Arthritis Rheum* 1995; 38: 1610-7.
15. OSTERGAARD M, STOLTENBERG M, LOVGREEN-NIELSEN P, VOLCK B, JENSEN CH, LORENZEN I: Magnetic resonance imaging-determined synovial membrane and joint effusion volumes in rheumatoid arthritis and osteoarthritis: Comparison with the macroscopic and microscopic appearance of the synovium. *Arthritis Rheum* 1997; 40: 1856-67.
16. TAMAI K, YAMATO M, YAMAGUCHI T, OHNO W: Dynamic magnetic resonance imaging for the evaluation of synovitis in patients with rheumatoid arthritis. *Arthritis Rheum* 1994; 37: 1151-7.
17. OSTERGAARD M: Different approaches to synovial membrane volume determination by magnetic resonance imaging: Manual versus automated segmentation. *Br J Rheumatol* 1997; 36: 1166-77.
18. CLUNIE G, HALL-CRAGGS MA, PALEY MN, KING A, WILKINSON ID, ELL PJ, EDWARDS JCW: Measurement of synovial lining volume by magnetic resonance imaging of the knee in chronic synovitis. *Ann Rheum Dis* 1997; 56: 526-34.
19. VEALE DJ, REECE RJ, PARSONS W *et al.*: Intra-articular primatised anti-CD4: Efficacy in resistant rheumatoid knees. A study of combined arthroscopy, MRI and histology. *Ann Rheum Dis* 1999; 58: 342-9.
20. OSTERGAARD M, STOLTENBERG M, GIDEON P, SORENSEN K, HENRIKSEN O, LORENZEN I: Changes in synovial membrane and joint effusion volumes after intraarticular methylprednisolone. Quantitative assessment of inflammatory and destructive changes in arthritis by MRI. *J Rheumatol* 1996; 23: 1151-61.
21. CREAMER P, KEEN M, ZANANIRI F *et al.*: Quantitative magnetic resonance imaging of the knee: A method of measuring response to intra-articular treatments. *Ann Rheum Dis* 1997; 56: 378-81.
22. CONAGHAN PG, WAKEFIELD R, O'CONNOR P *et al.*: Reversal of bony damage in early rheumatoid arthritis patients treated with IA corticosteroids and methotrexate: An MRI and ultrasonographic study. *Ann Rheum Dis* 1999 (Suppl.): 75.
23. OSTERGAARD M, HANSEN M, STOLTENBERG M *et al.*: Magnetic resonance imaging-determined synovial membrane volume as a marker of disease activity and a predictor of progressive joint destruction in the wrists of patients with rheumatoid arthritis. *Arthritis Rheum* 1999; 42: 918-29.
24. JEVTIC V, WATT I, ROZMAN B *et al.*: Contrast enhanced Dd-DTPA magnetic resonance imaging in the evaluation of rheumatoid arthritis during a clinical trial with DMARDs. A prospective two-year follow-up study on hand joints in 31 patients. *Clin Exp Rheumatol* 1997; 15: 151-6.
25. SUGIMOTO H, TAKEDA A, MASUYAMA J, FURUSE M: Early-stage rheumatoid arthritis: diagnostic accuracy of MR imaging. *Radiology* 1996; 198: 185-92.
26. MCGONAGLE D, GIBBON W, EMERY P: Classification of inflammatory arthritis by enthesitis. *Lancet* 1998; 352: 1137-40.
27. MCQUEEN FM, STEWART N, CRABBE J, ROBINSON E, YEOMAN S, TAN PLJ, MCLEAN L: Magnetic resonance imaging of the wrist in early rheumatoid arthritis reveals progression of erosions despite clinical improvement. *Ann Rheum Dis* 1999; 58: 156-63.
28. JEVTIC V, WATT I, ROZMAN B *et al.*: Prognostic value of contrast enhanced Gd-DTPA MRI for development of bone erosive changes in rheumatoid arthritis. *Br J Radiol* 1996; 35 (Suppl.): 26-30.
29. WAKEFIELD RJ, GIBBON WW, EMERY P: The current status of ultrasonography in rheumatology. *Rheumatol* 1999; 38: 195-201.
30. GRASSI W, CERVINI C: Ultrasonography in rheumatology: An evolving technique. *Ann Rheum Dis* 1998; 57: 268-71.
31. BALINT P, STURROCK RD: Musculoskeletal ultrasound imaging: A new diagnostic tool for the rheumatologist? *Br J Rheumatol* 1997; 36: 1141-2.
32. GRASSI W, TITARELLI E, PIRANI O, AVALTRONI D, CERVINI C: Ultrasound examination of the metacarpophalangeal joints in rheumatoid arthritis. *Scand J Rheumatol* 1993; 22: 243-7.
33. LUND PJ, HEIKAL A, MARICIC MJ, KRUPINSKI EA, WILLIAMS CS: Ultrasonographic imaging of the hand and wrist in rheumatoid arthritis. *Skeletal Radiol* 1995; 24: 591-6.
34. RUBALTELLI L, FIOCCO U, COZZI L *et al.*: Prospective sonographic and arthroscopic evaluation of proliferative knee joint synovitis. *J Ultrasound Med* 1994; 13: 855-62.
35. ALASAARELA E, SURAMO I, TERVONEN O, LAHDE S, TAKALO R, HAKALA M: Evaluation of humeral head erosions in rheumatoid arthritis: A comparison of ultrasonography, magnetic resonance imaging, computed tomography and plain radiography. *Br J Rheumatol* 1998; 37: 1152-6.
36. BACKHAUS M, KAMRADT T, SANDROCK D *et al.*: Arthritis of the finger joints. A comprehensive approach comparing conventional radiography, scintigraphy, ultrasound, and contrast-enhanced magnetic resonance imaging. *Arthritis Rheum* 1999; 42: 1232-45.
37. ALASAARELA E, TAKALO R, TERVONEN O, HAKALA M, SURAMO I: Sonography and MRI in the evaluation of painful arthritic shoulder. *Br J Rheumatol* 1997; 36: 996-1000.
38. SPIEGEL TM, KING W, WEINER SR, PAULUS HE: Measuring disease activity: Comparison of joint tenderness, swelling, and ultrasonography in rheumatoid arthritis. *Arthritis Rheum* 1987; 30: 1283-8.
39. VAN HOLSBEECK M, VAN HOLSBEECK K, GEVERS G *et al.*: Staging and follow-up of rheumatoid arthritis of the knee. Comparison

of sonography, thermography, and clinical assessment. *J Ultrasound Med* 1988; 7: 561-6.
40. FIOCCO U, COZZI L, RUBALTELLI L *et al.*: Long-term follow-up of rheumatoid and psoriatic proliferative knee joint synovitis. *Br J Rheumatol* 1996; 35: 155-63.
41. NEWMAN JS, LAING TJ, MCCARTHY CJ, ADLER RS: Power Doppler sonography of synovitis: assessment of therapeutic response - Preliminary observations. *Radiology* 1996; 198: 582-4.
42. STONE M, WHELAN B, BERGIN D, MAHER M, MURRAY J, MCCARTHY CJ: Power Doppler ultrasonography in metacarpophalangeal joint synovitis. *Ann Rheum Dis* 1999 (Suppl.): 29.
43. BLOMLEY M, COSGROVE D: Microbubble echo-enhancers: A new direction for ultrasound? *Lancet* 1997; 349: 1855-6.
44. DEVLIN J, LILLEY J, GOUGH A *et al.*: Clinical associations of dual-energy x-ray absorptiometry measurement of hand bone mass in rheumatoid arthritis. *Br J Rheumatol* 1996; 35: 1256-62.
45. DEODHAR AA, BRABYN J, PANDE I, STANLEY E, WOOLF AD: A five years longitudinal study of hand bone densitometry in early rheumatoid arthritis. *Arthritis Rheum* 1998; 41 (Suppl.): S52.
46. GREEN MJ, PROUDMAN S, STEWART S *et al.*: Serial hand bone densitometry with Lunar-XL Expert Densitometer in the assessment of patients with very early inflammatory arthritis. *Br J Rheumatol* 1998; 37 (Suppl. 1): 104.
47. DANFORS T, BERGSTROM M, FELTELIUS N, AHLSTROM H, WESTERBERG G, LANGSTROM B: Positron emission tomography with 11C-D-deprenyl in patients with rheumatoid arthritis. Evaluation of knee joint inflammation before and after intra-articular glucocorticoid treatment. *Scand J Rheumatol* 1997; 26: 43-8.
48. POLISSON RP, SCHOENBERG OI, FISCHMAN A *et al.*: Use of magnetic resonance imaging and positron emission tomography in the assessment of synovial volume and glucose metabolism in patients with rheumatoid arthritis. *Arthritis Rheum* 1995; 38: 819-25.
49. CHAPMAN PT, JAMAR F, KEELAN ET, PETERS AM, HASKARD DO: Use of a radiolabelled monoclonal antibody against E-selectin for imaging of endothelial activation in rheumatoid arthritis. *Arthritis Rheum* 1996; 39: 1371-5.
50. PETERFY CG, ROBERTS T, GENANT HK: Dedicated extremity MR imaging. An emerging technology. *Radiol Clin North America* 1997; 35: 1-20.