Clinical and Experimental Rheumatology 2005; 23: 100-102.

Cytomegalovirus-associated hemophagocytic syndrome in a patient with adult onset Still's disease

M. Amenomori[1], K. Migita[4], T. Miyashita[1], S. Yoshida[2], M. Ito[3], K. Eguchi[5], H. Ezaki[1]

[1]Department of General Medicine, [2]Department of Hematology, [3]Dept. of Pathology, and [4]Clinical Research Center, National Nagasaki Medical Center, Omura; [5]First Department of Internal Medicine, Nagasaki University School of Medicine, Nagasaki, Japan

Misato Amenomori, MD; Kiyoshi Migita, MD; Taichiro Miyashita, MD; Shinichiro Yoshida, MD; Masahiro Ito, MD; Katsumi Eguchi, MD; Hironori Ezaki, MD.

Please address correspondence and reprint requests to: Kiyoshi Migita, MD, Clinical Research Center, National Nagasaki Medical Center, Kubara 2-1001-1, Omura 856-8652, Japan. E-mail: migita@nmc.hosp.go.jp

Received on April 2, 2004; accepted in revised form on November 4, 2004.

© Copyright CLINICAL AND EXPERIMENTAL RHEUMATOLOGY 2005.

Key words: Adult onset Still's disease, cytomegalo-virus, virus-associated hemophagocytic syndrome.

ABSTRACT

Reactive hemophagocytic syndrome (HPS) is characterized by hemophagocytosis by activated histiocytes, resulting in pancytopenia and liver dysfunction. We describe a patient with adult onset Still's disease (AOSD) in whom HPS developed.

An 80-year-old Japanese woman with high fever, arthralgia, skin rash, and pleuritis was admitted to our hospital for further examination. She was diagnosed with AOSD and steroid therapy was initiated. During the course of steroid therapy, a re-elevation of serum ferritin levels and a marked increase in serum transaminase were observed. Bone marrow aspiration revealed an increase in the number of histiocytes with hemophagocytosis and cytomegalovirus (CMV)-positive leukocytes were detected. At this time we diagnosed the patient as having virus-associated hemophagocytic syndrome (VAHS) and elevated levels of trasaminase and ferritin were normalized by ganciclovir treatment.

Reactive HPS occurs in cases of active AOSD. However, it should be noted that HPS may be accompanied by opportunistic infections during immunosuppressive therapy requiring prompt antibiotic therapy.

Introduction

Adult onset Still's disease (AOSD) is a systemic inflammatory disorder characterized by spiking fever, rash, and polyarthralgia (1). In patients with AOSD, hyperferritemia appears to be a hallmark of disease activity (2). Since elevated serum ferritin levels may reflect activation of macrophages and reticuloendothelial systems (3), it is possible that the activation of reticuloendothelial systems is involved in the pathogenesis of AOSD (3). Hemophagocytic syndrome (HPS), which is also characterized by exaggerated histiocyte proliferation and activation, sometimes occurs in association with autoimmune diseases (4). Here, we report a case of cytomegalovirus (CMV)-associated HPS which occurred in a patient with AOSD during the course of steroid therapy.

Case report

An 80-year-old Japanese woman with a sore throat, high spiking fever, and polyarthralgia was admitted to our department. Her body temperature was 39.0ºC. Physical examination revealed skin rash on the anterior chest, and swelling of both wrists and ankles. On admission, the patient's blood cell count showed elevated white blood cells (WBC; 37.0 x 10^9/L; normal 35.0-91.0 x 10^9/L, 90% granulocytes), and platelets (47.8 x 10^9/L; normal 13.1-36.2 x 10^9/L). Mild liver dysfunction was present (AST 55 IU/L; normal 12-37 IU/L, ALT 68 IU/L; normal 6-37 IU/L). The erythrocyte sedimentation rate (ESR) and C-reactive protein (CRP) levels were elevated (90 mm/hr; normal 3-15 mm/hr, and 27.88 mg/dl; normal <0.30 mg/dl, respectively). Anti-nuclear antibodies (ANA) and rheumatoid factor (RF) were negative. The serum ferritin level was increased to 7394 ng/ml (normal 5-100 ng/ml). Repeated blood cultures were negative and antibiotic therapy was not effective for her spiking fever (Fig.1). There was no serological evidence of recent infection with either Epstein-Barr virus (EBV) or parvovirus B19. The patient's chest computed tomography demonstrated massive effusion. Analysis of the pleural effusions was negative for tumor cells and microorganisms.

This patient fulfilled the AOSD diagnostic criteria determined by Yamaguchi *et al*. (5) and a diagnosis of AOSD was made. Oral administration of prednisolone (30 mg daily) and methyprednisolone (250 mg/day) was administered for consecutive 3 days on the 10th day from the start of steroid therapy. Clinical symptoms were alleviated by these treatments. On the 20th day from the start of steroid therapy, the patient relapsed with fever and re-elevated serum ferritin levels (21,250 ng/ml) were observed. In addition, the patient had elevated serum transaminase levels. During the course of the relapse, leukopenia (WBC 2.1 x 10^9/L) was also observed (Fig. 1). Bone marrow aspiration showed benign-appearing histiocytes scattered throughout the marrow, indicating phagocytosis of erythrocytes, leukocytes and platelets (Fig. 2).

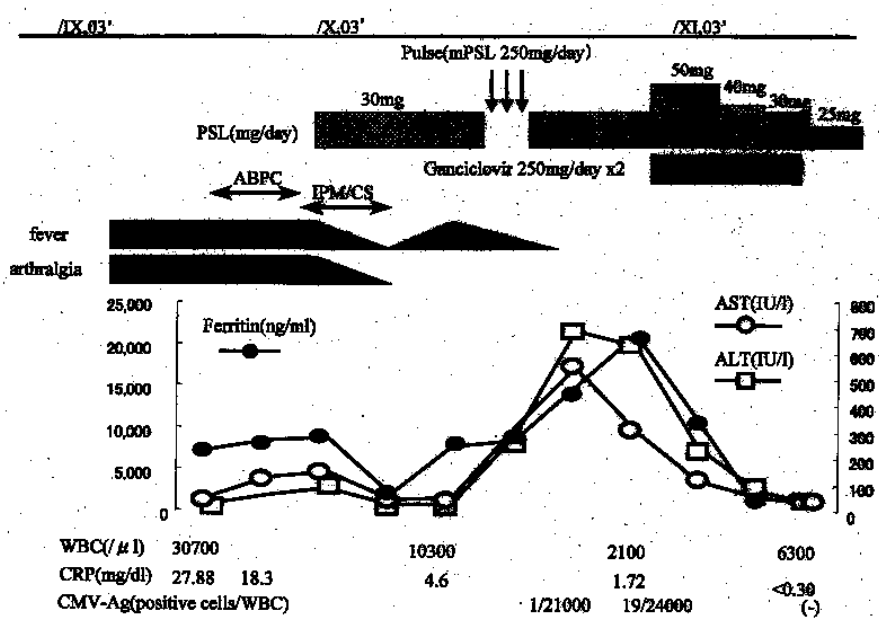

Fig. 1. Clinical course. PSL: prednisolone, mPSL: methyl-prednisolone, ABPC: ampicillin sodium, IPM/CS: imipenem/cilastatin, CMV-Ag: cytomegalovirus antigen.

Although the titers of CMV-IgM were within normal limits, the number of CMV-antigen-positive leukocytes in the peripheral blood was 19 per 21,000 leukocytes.

We considered this case to be a virus-associated hemophagocytic syndrome (VAHS) caused by CMV infection, and ganciclovir (250 mg twice per day) treatment was administered. After 14 days of ganciclovir treatment, the hyperferritinemia and elevated transaminase levels were normalized and the patient was discharged from the hospital (Fig. 1).

Discussion

AOSD is a form of polyarthritis associated with systemic manifestations such as a spiking fever and sore throat (1). Among the laboratory findings in cases of AOSD, hyperferritinemia appears to be a differential indicator of disease activity (2). It has been reported that activated macrophages release ferritin, and elevated ferritin levels may reflect the activation of macrophages (3). Although the exact etiology of AOSD is still unknown, considerable evidence has shown that the activation of macrophages seems to be one of the important clinicopathological findings in patients with AOSD (3).

In this report, we describe a case of AOSD with reactive HPS. HPS is characterized by the activation of histiocytes and macrophages and HPS shares many clinical features with AOSD, such as high fever, liver dysfunctions and coagulation abnormalities (6). Several diseases, including infection and lymphoproliferative diseases, are known to cause HPS (7).

Recently, it has been demonstrated that HPS can be associated with autoimmune disease (4). Although the mechanisms causing autoimmune-associated HPS remain unknown, autoantibody or immune complex (IC)-mediated mechanisms have been suggested, in which the deposition of circulating IC on marrow hematopoietic cells may result in hemophagocytosis via the activation of complement receptors on histiocytes (8). In addition to macrophage activation, uncontrolled cytokine productions might play a role in inducing HPS (9). In patients with active HPS, high levels of TH1 cytokines such as IFN-γ, IL-12, and IL-18 have been demonstrated. IL-18 seems to play an important role in HPS, since this cytokine induces IFN-γ and IL-12 secretion and correlates positively with the disease activity of HPS (10). HPS may occur in autoimmune systemic inflammatory diseases such as SLE, AOSD, and juvenile idiopathic arthritis (11). The occurrence of HPS in AOSD might result from the increased IL-18 levels, since IL-18 also plays a prominent role in AOSD by triggering macrophage activation (12).

The HPS observed with AOSD in our case was initially thought to be due to the AOSD itself. However, a large number of CMV antigen-positive leukocytes were found in the peripheral blood, and we concluded that this case of HPS was due to CMV infection. It should be noted in this context that a

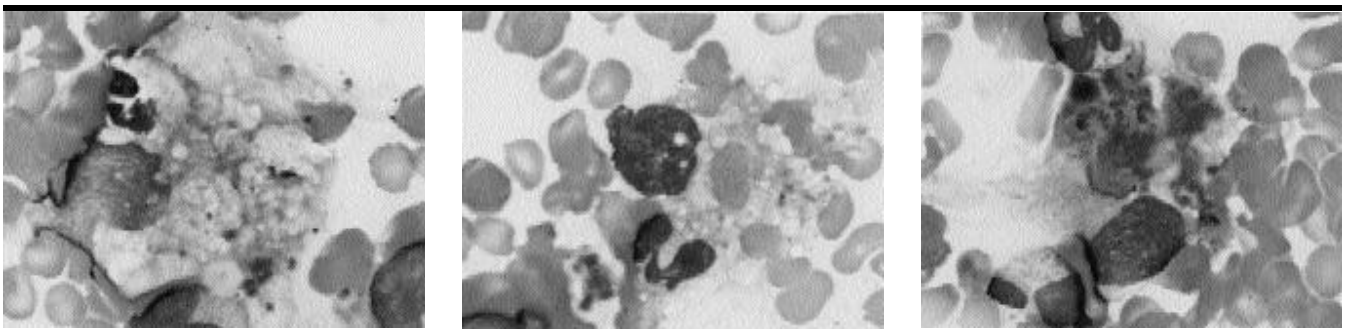

(a) (b) (c)

Fig. 2. Hemophagocytosis in bone marrow. The activated histiocytes showed marked phagocytosis of various hematopoietic cells including granulocytes (**a**), erythrocytes (**b**), and platelets (**c**). (May-Gimsa stain: original magnification x1,000)

successful response to HPS was obtained by ganacyclovir treatment. Infection is a major source of morbidity and mortality in patients with autoimmune diseases (13). CMV infection is usually subclinical in healthy populations (14), but in immunocompromised hosts CMV can induce a spectrum of illnesses such as hepatitis, interstitial pneumonia, and enteritis. CMV is also reported to be an etiological agent of HPS and the prognosis of CMV-induced HPS is not always favorable (15). HPS could be associated with both infections and ongoing systemic inflammatory diseases (11). Therefore, it is difficult to conclude that HPS was completely attributable to CMV infection in this case, since we increased the steroid dose (prednisolone 30 mg/day to 50 mg/day) in addition to the ganciclovir treatment.

When HPS occurs secondary to viral infection in immunocompromised patients with an autoimmune disease, prompt anti-viral therapy should be initiated. Moreover, it is important to recognize that, in addition to underlying disease activity, infections can also trigger HPS in patients with autoimmune diseases and precise tests for microorganisms are required.

References

1. SANCHEZ LORIA DM, MORENO ALVAREZ MJ, MALDONADO COCCO JA, SCHEINES EJ, MESSINAOD: Adult onset Still's disease: clinical features and course. *Clin Rheumatol* 1992; 11: 516-20.
2. AKRITIDIS N, GIANNAKAKIS I, GIOUGLIS T: Ferritin levels and response to treatment in patients with Adult Still's disease. *J Rheumatol* 1996; 23: 201-2.
3. LAMBOTTE O, CACOUB P, COSTEDOAT N, LE MOEL G, AMOURA Z, PIETTE JC: High ferritin and low glycosylated ferritin may also be a marker of excessive macrophage activation. *J Rheumatol* 2003; 30: 1027-8.
4. DHOTE R, SIMON J, PAPO T *et al.*: Reactive hemophagocytic syndrome in adult systemic disease: report of twenty-six cases and literature review. *Arthritis Rheum* 2003; 49: 633-9.
5. YAMAGUCHI M, OHTA A, TSUNEMATSU T *et al.*: Preliminary criteria for classification of adult Still's disease. *J Rheumatol* 1992; 19: 424-30.
6. REINER AP, SPIVAK JL: Hematophagic histiocytosis. A report of 23 new patients and a review of the literature. *Medicine* 1988; 7: 369-88.
7. JANKA G, IMASHUKU S, ELINDER G, SCHNEIDER M, HENTER JI: Infection- and malignancy-associated hemophagocytic syndromes. Secondary hemophagocytic lymphohistiocytosis. *Hematol Oncol Clin North Am* 1998; 12: 435-44.
8. KUMAKURA S, ISHIKURA H, UMEGAE N, YAMAGATA S, KOBAYASHI S: Autoimmune-associated hemophagocytic syndrome. *Am J Med* 1997; 102: 113-5.
9. LAY JD, TSAO CJ, CHEN JY, KADIN ME, SU IJ: Upregulation of tumor necrosis factor-alpha gene by Epstein-Barr virus and activation of macrophages in Epstein-Barr virus-infected T cells in the pathogenesis of hemophagocytic syndrome. *J Clin Invest* 1997; 100: 1969-79.
10. LARROCHE C, MOUTHON L: Pathogenesis of hemophagocytic syndrome (HPS). *Autoimmun Rev* 2004; 3:69-75.
11. DHOTE R, SIMON J, PAPO T, DETOURNAY B *et al.*: Reactive hemophagocytic syndrome in adult systemic disease: report of twenty-six cases and literature review. *Arthritis Rheum* 2003; 49: 633-9.
12. KAWASHIMA M, YAMAMURA M, TANIAI M *et al.*: Levels of interleukin-18 and its binding inhibitors in the blood circulation of patients with adult-onset Still's disease. *Arthritis Rheum* 2001; 44:550-60.
13. JUAREZ M, MISISCHIA R, ALARCON GS: Infections in systemic connective tissue diseases: systemic lupus erythematosus, scleroderma, and polymyositis/dermatomyositis. *Rheum Dis Clin North Am* 2003; 29: 163-184.
14. ADLER SP: New insights into human cytomegaloviral infections. *Prog Med Virol* 1990; 37: 136-55.
15. SAKAMOTO O, ANDO M, YOSHIMATSU S, KOHROGI H, SUGA M, ANDO M: Systemic lupus erythematosus complicated by cytomegalovirus-induced hemophagocytic syndrome and colitis. *Intern Med* 2002; 41: 151-5.