Superior vena cava thrombosis and chylothorax in a young patient

Sirs,

Behçet'sdisease (BD) is a systemic vasculitis with oral and\or genital ulcers. Superficial thrombophlebitis, deep vein thrombosis (DVT), arterial thrombosis with pseudoaneurysms are well known features of BD. We report a patient with superior vena cava (SVC) thrombosis and chylothorax as a presenting symptom of BD.

A 22-year-old Arab female was admitted because of progressive neck and arm edema for 3 weeks. The patient denied photosensitivity, rashes, joint pain, and use of oral contraceptives. She noted recurrent episodes of painful oral but not genital ulcers. Physical examination revealed dyspnea (24/min), tachycardia (110/min), prominent congestion of cervical vein and bilateral arm edema. A single oral ulcer was found. The rest of physical examination was unremarkable. A pathergy test was negative. Complete blood count showed reduced hemoglobin 10.9g/%, and mild thrombocytosis (480 x 10^3/mcrl). Biochemistry tests, urinalysis, and coagulation studies including prothrombin time, activated partial prothrombin time (aPTT), lupus anticoagulant, antithrombin III, protein C, protein S, and homocystein were within normal limits. Tests for antinuclear, anti-ds-DNA, anticardiolipin antibodies, and HLA B51 were negative. Doppler ultrasound (DUS) revealed complete SVC occlusion confirmed by chest computer tomography (CT). CT also showed small amount of pleural effusion. There was neither mediastinal lymphadenopathy nor evidence of thoracic duct rupture.

Despite high doses of intravenous heparin (aPTTtwice control value) the patient's respiratory condition deteriorated in the next two weeks due to progressive fluid accumulation in pleural cavities (Fig. 1). On pleurocenthesis the fluid was sterile chylotic exudate (pH 7.32, protein 3.5 g/dl, lactatedehydrogenase 580 U, cholesterol 380 mg/dl, triglycerides 180 mg\dl, leukocyte count 2 x 10^3/mcrl). Pleural effusion re-accumulated and required repeated drainage.

Prednisone 60 mg/daily, azathioprine 100 mg/daily, and colchicine 1.0 mg/daily were added to ongoing anticoagulation. The pleural effusion regressed and finally disappeared after 3 months. Warfarin replaced heparin and the prothrombin time was maintained at an international ratio 2.8-3.0. Prednisone was gradually tapered to 5 mg/daily. Two years of follow up was unremarkable except for recurrent oral ulcerations.

Venous and arterial occlusions, arterial aneurysms, pulmonary artery-to-venous fistula, cerebral vasculitis, and uveitis are well-known vascular complications of established BD (1). None of the known thrombophilic abnormalities was found in BD. Endothelial dysfunction is believed to be responsible for the hyper-coagulation state (2). An increased incidence of thrombosis was associated with HLA-B51 class I alleles, male gender, and a positive pathergy test (3,4). Among venous lesions, DVTof the low extremities was the most common (up to 57%), followed by thrombosis of inferior and superior vena cava (8-18%), hepatic veins (3-4%), and sagittal sinus (1, 5,6). Blockage of the lymphatic circulation due to SVC thrombosis may occasionally lead to chylothorax (7, 8).

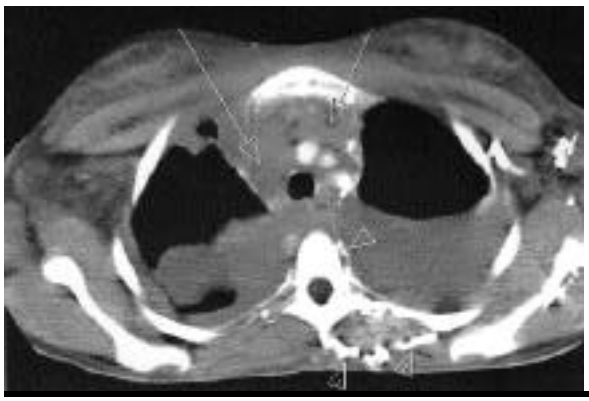

Fig. 1: Axial chest CT scan at the level of 5 vessels (mediastinal window): a large amount of bilateral pleural effusion is seen, left brachiocephalic vein and superior vena cava are not opacified (arrows) due to thrombosis, multiple collateral vessels are shown (arrowheads).

DUS, CT and magnetic resonance angiography are used to evaluate thoracic vascular involvement (1). Biopsies from arterial specimens obtained during invasive procedures confirmed the presence of vasculitis, perivasculitis and secondary thrombosis in BD (9). The standard treatment for DVT in BD is anticoagulation with heparin or low molecular weight heparin followed by warfarin. Life-long anticoagulation is required to prevent thrombosis recurrence but could be insufficient in cases of large vessel involvement, probably because of underlying inflammation (2, 5-7). Combined anticoagulation and immunosuppression (corticosteroids, cyclophosphamide, azathioprine, and cyclosporine) should be considered in BD patients with large vein occlusion to prevent the recurrence of thrombosis (9, 10).

SVC thrombosis complicated by chylothorax, as a presenting symptom of BD, is rare. In the absence of coagulation abnormalities, SVC thrombosis in young Arab patient with the history of oral ulcers raises the possibility of BD. Occasionally vascular thrombosis may be the only manifestation of the disease (incomplete BD) despite the fact that this feature is not included among the International Study Group criteria of BD. Aggressive anti-inflammatory treatment on top of ongoing life-long anticoagulation should be considered in management of BD patients with large vessel occlusion.

A. BALBIR-GURMAN, *MD*[1]
L. GURALNICK, *MD*[2]
L.A. BEST, *MS*[3]
A.M. NAHIR, *MD, PhD*[1]

[1]B. Shine Dept. of Rheumatology; [2]Department of Diagnostic Imaging; [3]Department of Thoracic Surgery, Rambam Medical Center, Haifa, Israel.

Address correspondence to: Alexandra Balbir-Gurman, MD, B. Shine Dept. of Rheumatology, Rambam Medical Center, Bat Galim, Haifa, 31096, Israel. a_balbir@rambam.health.gov.il

References

1. KO GY, BYUN JY, CHOI BG, CHO SH: The vascular manifestations of Behçet's disease: angiographic and CT findings. *Br J Radiol* 2000; 73: 1270-4.
2. ESPINOSA G, FONT J, TASSIES D *et al.*: Vascular involvement in Behçet's disease: relation with thrombophilic factors, coagulation activation, and thrombomodulin. *Am J Med* 200; 112: 37-43.
3. KAYA TI, DUR H, TURSEN U, GURLER A: Association of class I HLAantigens with the clinical manifestations of Turkish patients with Behçet's disease. *Clin Exp Dermatol* 2002; 27: 498-501.
4. AMES PR, STEUER A, PAP A, DENMAN AM: Thrombosis in Behçet's disease: a retrospective survey from a single UK centre. *Rheumatology* (Oxford). 2001; 40: 652-5.
5. THOMAS I, HELMOLD ME, NYCHAY S: Behçet's disease presenting as superior vena cava syndrome. *J Am Acad Dermatol* 1992; 26: 863-5.
6. ROGUIN A, EDELSTEIN S, EDOUTE Y: Superior vena cava syndrome as a primary manifestation of Behçet's disease. *Angiology* 1997; 48: 365-8.
7. BOUSLAMA A, AOUINA H, MUSTAPHA R, CHAABANE M, LADEB MF, GANT A: Chylothorax caused by thrombosis of the superior vena cava due to Behçet's disease. *Rev Mal Respir* 1987; 4: 177-9.
8. COPU L, EMRI S, SELCUK ZT *et al.*: Life threatening chylous pleural and pericardial effusion in a patient with Behçet's disease. *Thorax* 1992; 47: 64-5.
9. CHAJEK T, FAINARU M: Behçet's disease. Report of 41 cases and a review of the literature. *Medicine (Baltimore)* 1975; 54: 179-96.
10. OZEREN M, MAVIOGLU I, DOGAN OV, YUCELE: Reoperation results of arterial involvement in Behçet's disease. *Eur J Vasc Endovasc Surg* 2000; 20: 512-9.