Feet nailfold capillaroscopy is not useful to detect the typical scleroderma pattern

Sirs,

Raynaud's phenomenon (RP) is one of key symptoms of several rheumatic autoimmune diseases (1). Although in general it involves the fingers, often toes, ears, nose and tongue can be affected. Nailfold capillaroscopy (NFC) is a simple and non-invasive method to analyse the capillary morphology (2). It is a fast, cheap and useful tool to distinguish between primary and secondary RP in clinical practice (3, 4).

The aim of the study was to compare quantitative and semi-quantitative NFC parameters (cutaneous transparency, venous plexus, length, disorganisation of the microvascular array, capillary ramifications, micro-haemorrhages, angiogenesis, ectasia, micro-aneurisms, giant capillaries, blood flow velocity, loss of capillaries or avascular areas) observed in the hands and feet of patients with systemic sclerosis (SSc) and 3 different non-SSc, control groups, and to identify the usefulness of the feet NFC in routine clinical practice (5). NFC was performed in a total of 61 subjects [16 fulfilling the American College of Rheumatology criteria for SSc (6) (16 F, mean age 67.8 years, range 54–89 years, mean disease duration 8.5 years and late stage of the disease), 15 with primary RP (15 F, mean age 44 years, range 20–60, mean disease duration 7 years), 15 with rheumatoid arthritis (15 F, mean age 54.3 years, range 34–76, mean disease duration 10 years) and 15 healthy controls without any history of connective tissue diseases or smoking habits (15 F, mean age 25 years, range 21–43)]. Videocapillaroscopy of II, III, IV and V fingers of the hands and I, II, III, IV toes of the feet – because the fifth are too small for the examination as suggested by the international guidelines – was performed in all patients using "Video Cap" (DS MEDICA with 100x optical probe) and the results were evaluated according to the current guidelines (7, 8). Statistical analysis (95% and 99% confidence intervals) was performed with the χ^2 test. Probability (p) values less than 0.05 were considered statistically significant.

Comparing the results of the hands and the feet of non-SSc patients, NFC findings were found similar both in hands and feet, except cutaneous transparency (χ^2=4,444 p=0.035), blood flow velocity (χ^2=16,576 p<0.005) and tortuosity (χ^2=6,429 p=0.011).

Analysing SSc patients, significant differences were observed comparing hands and feet NFC in micro-haemorrhages (χ^2=7.385 p=0,007), micro-aneurisms (χ^2=13,333 p<0,005) and giant capillaries (χ^2=18,286 p<0,005) (Table I). Using videocapillaroscopy of the feet of SSc patients, giant capillaries were detected only in one of them and no micro-haemorrhages were found (Fig. 1).

According to the current guidelines the most important parameters to define a "scleroderma pattern" are: avascular areas, giant capillaries and micro-haemorrhages (5).

This work demonstrated that NFC of the feet is less sensitive than NCF of the hands to recognise giant capillaries and micro-haemorrhages (active pattern of the disease) in scleroderma patients, a possible explanation of this result will be related to the number of the trauma that involves the feet and make difficult to distinguish these lesions from those disease related. In conclusion, for this reason we do not suggest it as a valid anatomic site in clinical practice.

Table I. χ^2 test hands *vs*. feet in scleroderma patients.

	Systemic sclerosis (16)					
	Normal (0)		Abnormal (1,2,3)			
	Hand	Feet	Hands	Feet	χ^2	p-value
Cutaneous transparency	14	13	2	3	0.237	0.626
Venous plexus	5	6	11	10	0.139	0.71
Length	3	4	13	12	0.183	0.669
Blood flow velocity	1	0	15	16	1.032	0.310
Microvascular array disorganisation	3	3	13	13	0	1
Capillary ramifications	0	0	16	16	0	1
Micro-haemorrhages	10	16	6	0	7.385	0.007*
Neo angiogenesis	0	0	16	16	0	1
Ectasia	0	3	16	13	3.310	0.069
Micro-aneurisms	15	5	1	11	13.333	<0.005**
Giant capillaries	3	15	13	1	18.286	<0.005**
Avascular areas	1	3	15	13	1.143	0.285

**p-value <0.05.

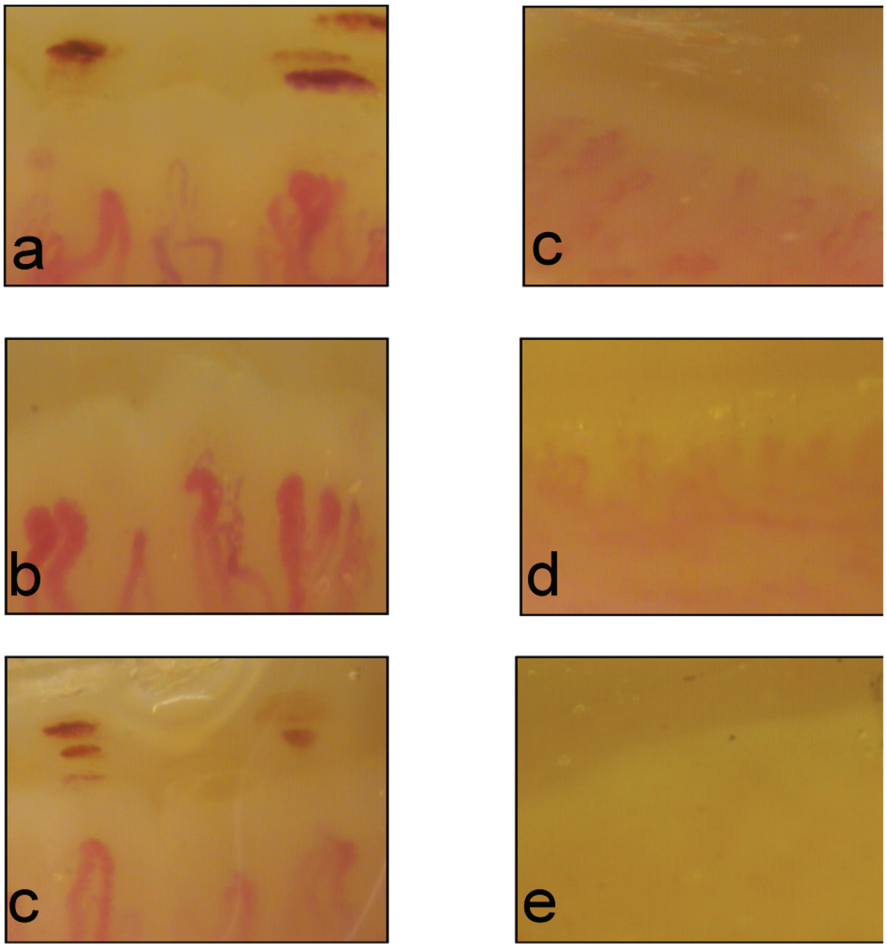

Fig. 1. Hands capillaroscopy in systemic scleroderma patients showed micro-haemorragies, giant capillaries and loss of capillaries (a, b, c). Feet capillaroscopy of the same patients confirmed the avascular areas but not the presence of micro-haemorrages and giant capillaries (c, d, e).

A. BATTICCIOTTO[1]
F. ATZENI[1,2]
S. FOGLIA[3]
M. ANTIVALLE[1]
A. SERAFIN[3]
P. SARZI-PUTTINI[1]

[1]Rheumatology Unit, L. Sacco University Hospital, Milan; [2]William Harvey Research Institute, Barts and the London School of Medicine, London, United Kingdom; [3]Podology Unit, University of Milan, Milan, Italy.

Address correspondence to:
Piercarlo Sarzi-Puttini, MD,
Rheumatology Unit, Ospedale L. Sacco,
20127 Milano, Italy.
E-mail: sarzi@tiscali.it
and: atzenifabiola@hotmail.com

Competing interests: none declared.

References

1. CUTOLO M, GRASSI W, MATUCCI CERINIC M: Raynaud's phenomenon and the role of capillaroscopy. *Arthritis Rheum* 2003; 42: 3023-30.
2. CUTOLO M, PIZZORNI C, SECCHI ME, SULLI A: Capillaroscopy. *Best Pract Res Clin Rheumatol* 2008; 22: 1093-108.
3. CORTES S, CUTOLO M: Capillaroscopic patterns in rheumatic diseases. *Acta Reumatol Port* 2007; 32: 29-36.
4. LAMBOVA SN, MÜLLER-LADNER U: The role of capillaroscopy in differentiation of primary and secondary Raynaud's phenomenon in rheumatic diseases: a review of the literature and two case reports. *Rheumatol Int* 2009; 29: 1263-71.
5. SULLI A, SECCHI ME, PIZZORNI C, CUTOLO M: Scoring the nailfold microvascular changes during the capillaroscopic analysis in systemic sclerosis patients. *Ann Rheum Dis* 2008; 67: 885-7.
6. LONZETTI LS, JOYAL F, RAYNAULD JP, ROUSSIN A, GOULET JR, RICH E: Updating the American College of Rheumatology preliminary classification criteria for systemic sclerosis: addition of severe nailfold capillaroscopy abnormalities markedly increases the sensitivity for limited scleroderma. *Arthritis Rheum* 2001; 44: 735-6.
7. SATO LT, KAYSER C, ANDRADE LE: Nailfold capillaroscopy abnormalities correlate with cutaneous and visceral involvement in systemic sclerosis patients. *Acta Reumatol Port*. 2009; 34: 219-27.
8. MURRAY AK, MOORE TL, MANNING JB, TAYLOR C, GRIFFITHS CE, HERRICK AL: Non invasive imaging techniques in the assessment of scleroderma spectrum disorders. *Arthritis Rheum* 2009; 61: 1103-11.