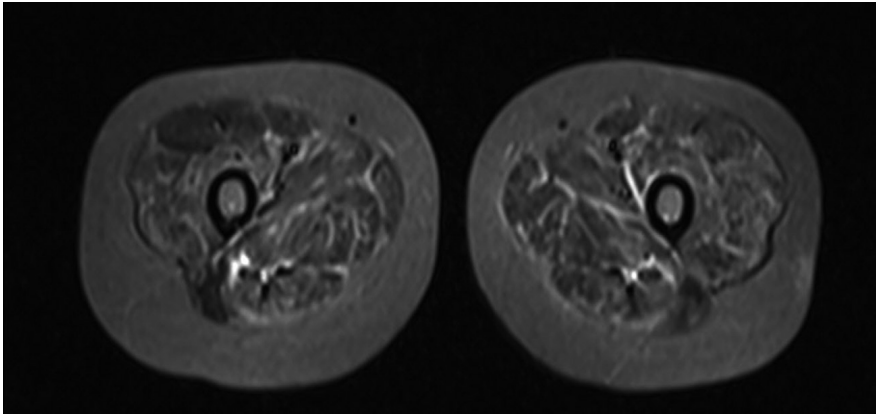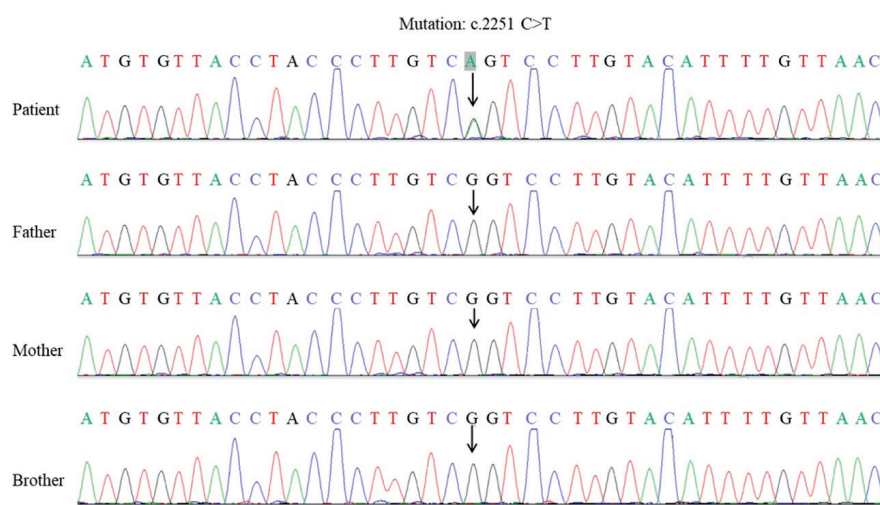


Supplementary Fig. S1. Magnetic resonance imaging of both thighs revealed diffusely increased signal throughout all the muscles of both thighs on T2 -weighted short-tau inversion recovery (T2w-STIR) imaging.



Supplementary Fig. S2. Genetic testing. The patient was carrying NM_004012.4: c.2251C>T (NP_004003.2: p. Arg751Ter) nonsense mutation. It is a *de novo* mutation, which was classified as pathogenic according to ACMG guideline.