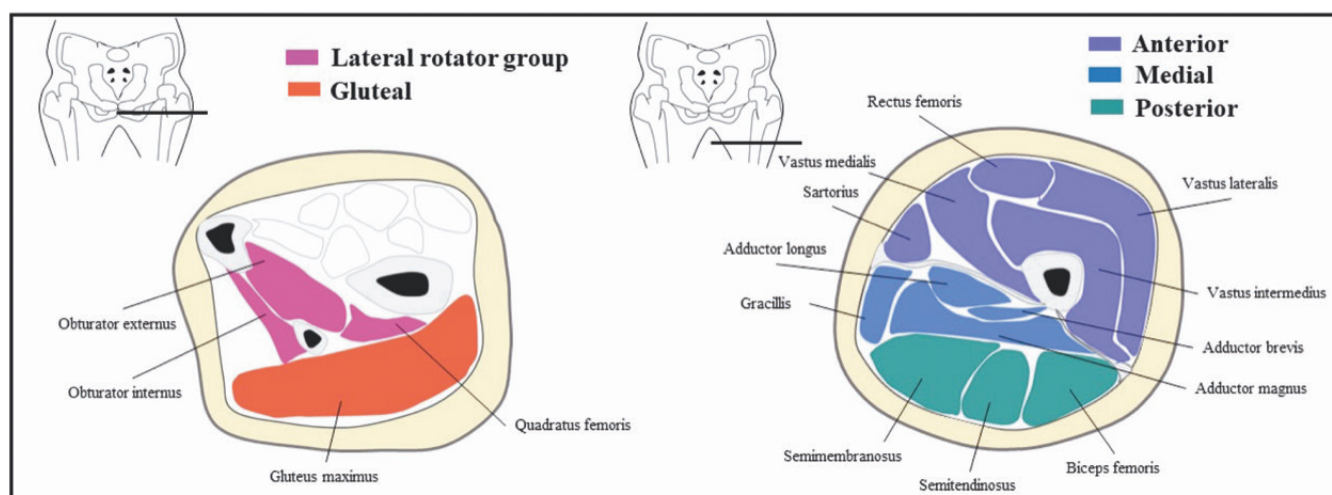


Supplementary Table S1. Muscles were grouped in each thigh compartment.

Compartments	Muscles
Lateral rotator group	Obturator internus Obturator externus Quadratus femoris
Gluteal	Gluteus maximus
Anterior	Rectus femoris Vastus medialis Vastus intermedius Vastus lateralis Sartorius
Medial	Gracillis Adductor longus Adductor brevis Adductor magnus
Posterior	Semimembranosus Semitendinosus Biceps femoris

**Supplementary Fig. S1.** Anatomy of thigh muscles.

Cross-section of the pelvis, gluteus maximus was grouped in Gluteal. Obturator internus and obturator externus and quadratus femoris were grouped in Lateral rotator group. Cross-section of the thigh, three compartments: anterior, medial, and posterior, were painted in different colours.