

Musculoskeletal ultrasound in paediatric rheumatology: the Italian perspective

Sirs,

In recent years, musculoskeletal ultrasound (MSUS) has been regarded as the most suitable imaging tool to assess children with chronic inflammatory arthritis, owing to several advantages over other imaging modalities (1, 2). However, MSUS in children requires a steep, long-lasting learning curve, due to the peculiar changes of the immature skeleton and of the sonographic findings over time. Furthermore, thorough standardisation and validation in pediatrics are still under investigation (3-5). Among several collaborative initiatives teeming with these topics, the Italian Pediatric Ultrasound in Rheumatology (I-PURE) group, born in 2014, performed a survey to investigate the current use and the relevant topics of interest of MSUS among Italian paediatric rheumatologists.

The survey questionnaire was emailed in July 2015 to the listserve of the Italian Paediatric Rheumatology Study Group, was completed by each respondent through a web-based system in approximately 10-15 minutes, and explored: 1) demographic and professional data; 2) use of MSUS in daily practice; 3) rating (0 = not important at all; 5 = extremely important) the level of importance of applications of MSUS in clinical practice, and of different joints to investigate by MSUS; 4) rating (0-5) the level of importance of conventional radiology, MSUS and MR for the diagnosis and monitoring of JIA. Responses were analysed by descriptive statistics. Respondents' data were matched with the Pediatric Rheumatology International Trial Organization (PRINTO) Italian centres, available online at <http://www.printo.it/pediatric-rheumatology/pediatricrheumatology/centri.asp?Lingua=Italy&Paese=Italy>. No ethical approval was required.

Seventeen physicians out of 174 (10%) completed the survey. Fifty-three per cent of the respondents *versus* 14% of the non-respondents were part of the PRINTO network. Sixty-five per cent spent more than 75% of the working time with children affected by rheumatic diseases and almost all (94%) have been visiting them for more than 5 years, with 24% for more than 20 years. Thirteen respondents (76%) used MSUS in daily practice: three by themselves, whereas ten referring patients to radiologists (46%), adult rheumatologists (31%), paediatric rheumatologists (23%), or orthopaedic surgeons (8%) with experience in MSUS. The majority (82%) considered the ability of MSUS to assess active synovitis and to guide intraarticular corticosteroid injections as the most important clinical applications (score 4/5), followed by the support in monitoring the disease activity and in therapeutic decision-making. Fifteen respondents (88%) indicated the wrist, the ankle and the midfoot as the most relevant joints to investigate by MSUS (Fig. 1). MSUS was regarded as the most suitable imaging modality to diagnose (88%) and to monitor disease activity (94%) in JIA, compared to MR (75% and 9%, respectively) and conventional radiology (19% and 18%, respectively).

To the best of our knowledge, this is the first attempt to assess the use and interest in MSUS in paediatric rheumatology in Italy. The respondents to our survey had considerable experience and were frequently part of PRINTO, one of the most widespread networks in paediatric rheumatology. Very few performed MSUS assessments by themselves. MSUS was considered of high relevance in assessing active synovitis and guiding intraarticular corticosteroid injections, in particular for the evaluation of the wrist, the ankle and the midfoot joints, in line with previous studies (6-10). Our response rate was low, but still higher than a similar survey recently conducted in the Italian adult Rheumatology Units

(10). The low diffusion of MSUS among Italian paediatric rheumatologists may be explained by the recent astounding interest in MSUS in children, compared to the well-established experience in adults. Furthermore, unlike adult rheumatologists' training programmes, no formal training on MSUS is usually planned during the educational course of paediatric rheumatologists. Our survey suggests that suitable training and further research on MSUS in paediatric rheumatology are priorities for successfully running the path already experienced in adults.

Acknowledgments

The authors are grateful to Prof. Giovanni Corsello, for the Italian Paediatric Society (SIP) endorsement, and to Dr Valeria Geroni, Dr Loredana Lepore and Prof. Alberto Martini for their valuable support to the I-PURE initiative.

Web-based and editorial support was provided by FULLCRO and was funded by Pfizer.

- S. LANNI¹, MD
- O. DE LUCIA², MD, PhD
- N. POSSEMATO³, MD
- C. MALATTIA¹, MD, PhD
- V. RAVAGNANI⁴, MD, PhD
- S. MAGNI-MANZONI⁵, MD

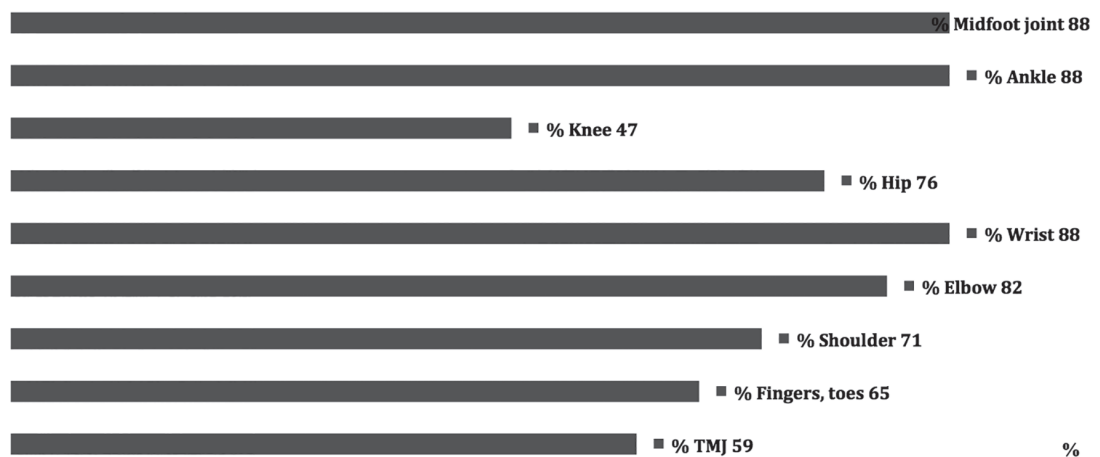
- ¹Pediatria II Reumatologia, Istituto Giannina Gaslini, Genoa, Italy;
- ²Department of Rheumatology, Gaetano Pini Institute, Milan, Italy;
- ³Department of Internal Medicine, Azienda Ospedaliera ASMN, IRCCS, Reggio Emilia, Italy;
- ⁴Internal Medicine, Carlo Poma Hospital, Mantova, Italy;
- ⁵Paediatric Rheumatology Unit, IRCCS Bambino Gesù Children's Hospital, Rome, Italy.

S. Lanni and O. De Lucia contributed equally to this study.

Please address correspondence to: Silvia Magni-Manzoni, Piazza Sant'Onofrio 4, 00165 Rome, Italy. E-mail: silvia.magnimanzoni@opbg.net

Competing interests: none declared.

Fig. 1. Frequency (%) of respondents who rated the MSUS evaluation of a specific joint as very important or extremely important.



Letters to the Editors

References

1. MAGNI-MANZONI S, MALATTIA C, LANNI S, RAVELLI A: Advances and challenges in imaging in juvenile idiopathic arthritis. *Nat Rev Rheumatol* 2012; 8: 329-36.
2. LANNI S, WOOD M, RAVELLI A, MAGNI-MANZONI S, EMERY P, WAKEFIELD RJ: Towards a role of ultrasound in children with juvenile idiopathic arthritis. *Rheumatology* (Oxford) 2013; 52: 413-20.
3. COLLADO P, JOUSSE-JOULIN S, ALCALDE M, NAREDO E, D'AGOSTINO MA: Is ultrasound a validated imaging tool for the diagnosis and management of synovitis in juvenile idiopathic arthritis? A systematic literature review. *Arthritis Care Res* (Hoboken) 2012; 64: 1011-9.
4. ROTH J, JOUSSE-JOULIN S, MAGNI-MANZONI S *et al.*: Definitions for the Sonographic Features of Joints in Healthy Children. *Arthritis Care Res* 2015; 67: 136-42.
5. COLLADO P, VOJINOVIC J, NIETO JC *et al.*: Toward standardized musculoskeletal ultrasound in pediatric rheumatology: Normal age related ultrasound findings. *Arthritis Care Res* 2015; doi: 10.1002/acr.22670.
6. MAGNI-MANZONI S, COLLADO P, JOUSSE-JOULIN S *et al.*: Current state of musculoskeletal ultrasound in paediatric rheumatology: results of an international survey. *Rheumatology* (Oxford) 2014; 53: 491-6.
7. PASCOLI L, WRIGHT S, MCALLISTER C, ROONEY M: Prospective evaluation of clinical and ultrasound findings in ankle disease in juvenile idiopathic arthritis: importance of ankle ultrasound. *J Rheumatol* 2010; 37: 2409-14.
8. LAURELL L, COURT-PAYEN M, NIELSEN S *et al.*: Ultrasonography and color Doppler in juvenile idiopathic arthritis: diagnosis and follow-up of ultrasound-guided steroid injection in the ankle region. A descriptive interventional study. *Pediatr Rheumatol Online J* 2011; 9: 4.
9. LAURELL L, COURT-PAYEN M, NIELSEN S, ZAK M, FASTH A: Ultrasonography and color Doppler in juvenile idiopathic arthritis: diagnosis and follow-up of ultrasound-guided steroid injection in the wrist region. A descriptive interventional study. *Pediatric Rheumatology* 2012; 10: 11.
10. IAGNOCCO A, CECCARELLI F, CUOMO G *et al.*: Musculoskeletal Ultrasound Study Group of the Italian Society of Rheumatology. Diffusion and applications of musculoskeletal ultrasound in Italian Rheumatology Units. *Reumatismo* 2013; 65: 46-7.