

## One year in review: ultrasound in arthritis

E. Naredo<sup>1</sup>, A. Iagnocco<sup>2</sup>

<sup>1</sup>Department of Rheumatology, Hospital General Universitario Gregorio Marañón, Faculty of Medicine, Universidad Complutense, Madrid, Spain;

<sup>2</sup>Department of Rheumatology, Sapienza Università di Roma, Rome, Italy.

Esperanza Naredo, MD, PhD  
Annamaria Iagnocco, MD

Please address correspondence to:  
Esperanza Naredo,  
Department of Rheumatology,  
Hospital General Universitario  
Gregorio Marañón,  
Doctor Esquerdo 46,  
28007 Madrid, Spain.  
E-mail: enaredo@ser.es

Received on January 10, 2016; accepted  
in revised form on January 13, 2016.

Clin Exp Rheumatol 2016; 34: 1-10.

© Copyright CLINICAL AND  
EXPERIMENTAL RHEUMATOLOGY 2016.

**Key words:** ultrasound, rheumatoid arthritis, spondyloarthritis, psoriatic arthritis, osteoarthritis, juvenile idiopathic arthritis

### ABSTRACT

*Musculoskeletal ultrasound (MSUS) has become a relevant part of rheumatology practice and research because it substantially allows us to optimise management of rheumatic and musculoskeletal diseases. This non-invasive imaging modality is a valuable point-of-care tool to accurately evaluate intra-articular and periarticular structures involved in a wide range of rheumatic diseases in adults and children. In addition, MSUS is an invaluable bedside aid for guiding accurate and safe musculoskeletal aspirations, injections and biopsies. This review provides an overview of the literature of the last year on the role of MSUS in arthritis.*

### Introduction

Over the past two decades, musculoskeletal (MS) ultrasound (US) has played an increasingly important role in optimising diagnosis, assessment, and monitoring of patients with rheumatic and musculoskeletal diseases (1). High-resolution grey-scale (GS) US and highly sensitive Doppler mode resulting from technological improvements allow an accurate and sensitive evaluation of joint inflammation and structural damage in rheumatoid arthritis (RA), spondyloarthritis (SpA), and osteoarthritis (OA). US is now also increasingly being used in the diagnosis and monitoring of microcrystalline arthropathies, connective tissue diseases, vasculitis, and paediatric musculoskeletal diseases. Furthermore, MSUS is a valuable bedside tool for guiding accurate and safe MS diagnostic fluid aspiration or biopsies and peri- or intralesional therapeutic injections (2). A great research effort, particularly by the Outcome Measures in Rheumatology (OMERACT) MSUS group, is being undertaken to validate MSUS in rheumatic diseases as well as to standardise US scanning technique and definitions

of abnormalities in order to overcome the intrinsic operator-dependent nature of this imaging modality (3). The advantages of US such as non-invasiveness, availability, relative low cost, repeatability, and high patient-acceptance facilitate its progressive implementation in rheumatologic clinics all over the world. This review provides an evidence-based update on the role of MSUS in arthritis, *i.e.* RA, SpA, OA and juvenile idiopathic arthritis (JIA). Figures 1-4 show illustrative US images of these diseases.

### Methods

We carried out a literature search in PUBMED and EMBASE databases for English language articles published from January 2015 to December 2015. We review all the published articles and selected the most relevant according to the following criteria; involving humans, focus on MSUS advancements, relevance to clinical rheumatology, journal impact factor and expert opinion of the authors. We included original articles and international consensus and recommendations. Reviews or abstracts from scientific congresses were not included.

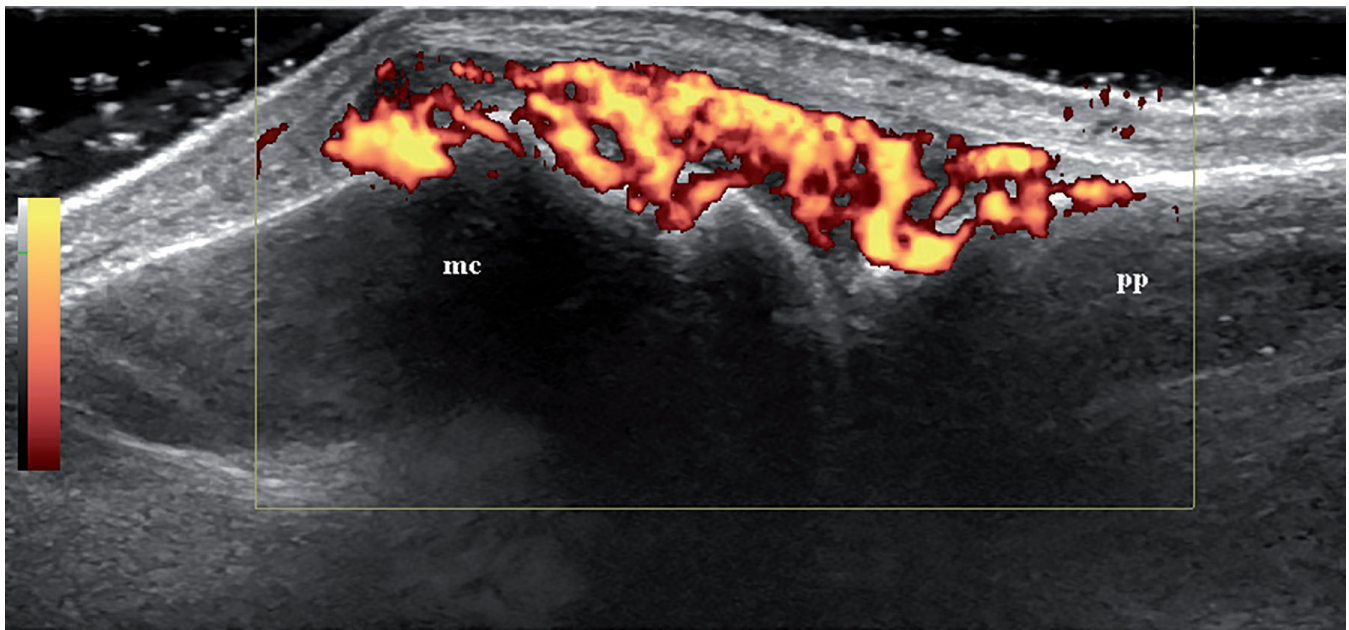
### Rheumatoid arthritis

MSUS has shown validity and added value over clinical and radiographic assessment in improving diagnosis and monitoring of RA (4, 5). GS US is more sensitive than clinical evaluation in detecting intra-articular (*i.e.* synovial hypertrophy and effusion) and periarticular inflammation (*i.e.* tenosynovitis) as well as more sensitive than conventional radiography in detecting structural damage (*i.e.* bone erosions, tendon damage). Doppler mode, either colour Doppler (CD) or power Doppler (PD), is able to detect pathological synovial and tenosynovial flow, which is a validated marker of synovial inflam-

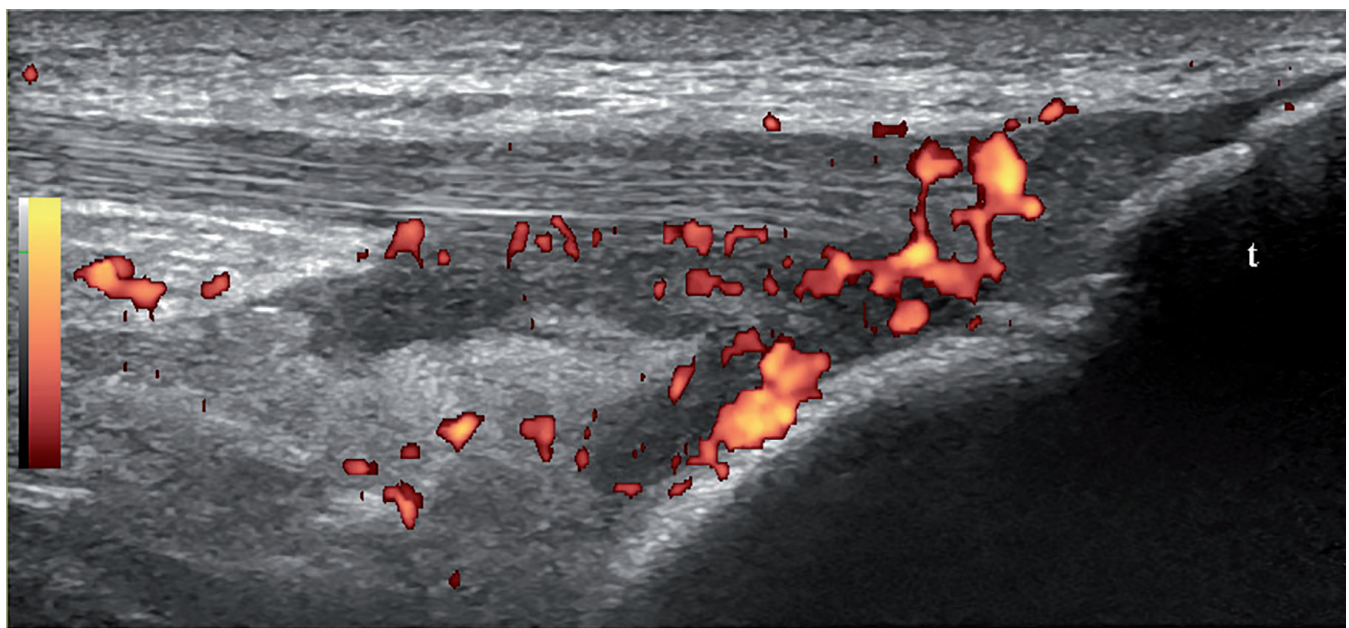
### Competing interests:

E. Naredo has received speaker fees from Abbvie, Roche Farma, Bristol-Myers Squibb, Pfizer, UCB, and Novartis.

A. Iagnocco has received speaker fees from Abbvie and Bristol-Myers Squibb.



**Fig. 1.** Longitudinal ultrasound image of the dorsal aspect of a metacarpophalangeal joint that shows grey-scale synovial hypertrophy with high power Doppler signal in a patient with rheumatoid arthritis. **mc**: metacarpal bone; **pp**: proximal phalanx.



**Fig. 2.** Longitudinal ultrasound image of the patellar tendon that shows grey-scale distal enthesopathy and deep infrapatellar bursitis with power Doppler signal in a patient with psoriatic arthritis. **t**: tibia.

matory activity (*i.e.* Doppler synovitis, Doppler tenosynovitis) that strongly predicts joint structural damage progression (4, 5).

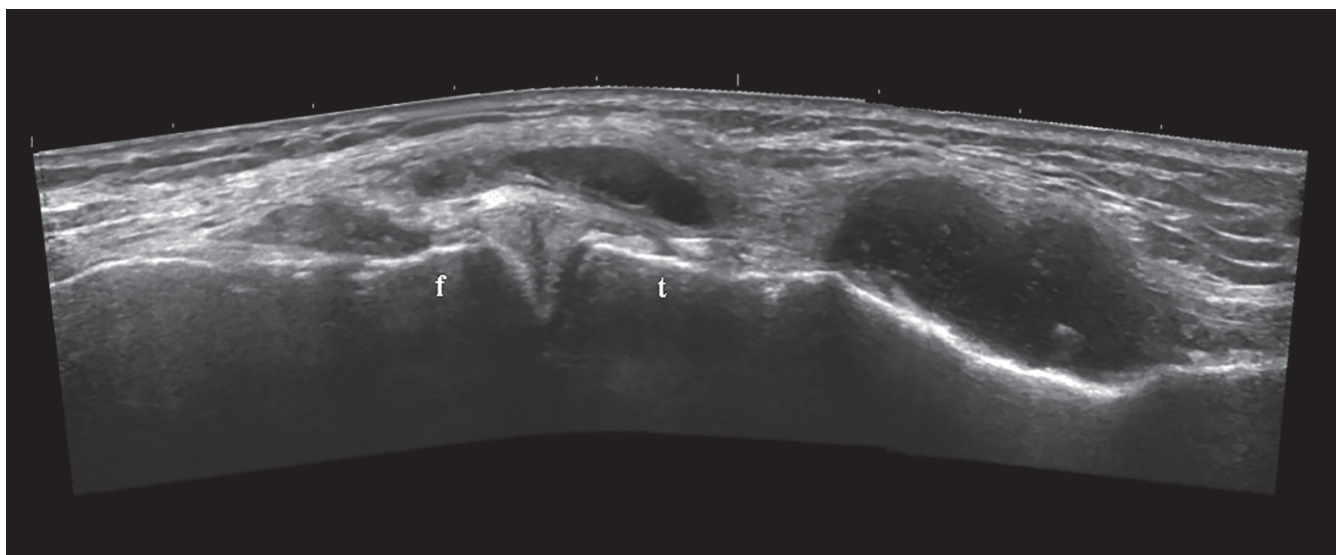
#### Validation

Kelly *et al.* (6) investigated the relationship of GS and Doppler synovitis with histological synovial vascularity, angiogenic/lymphangiogenic factors and cellular mediators of inflammation in 12

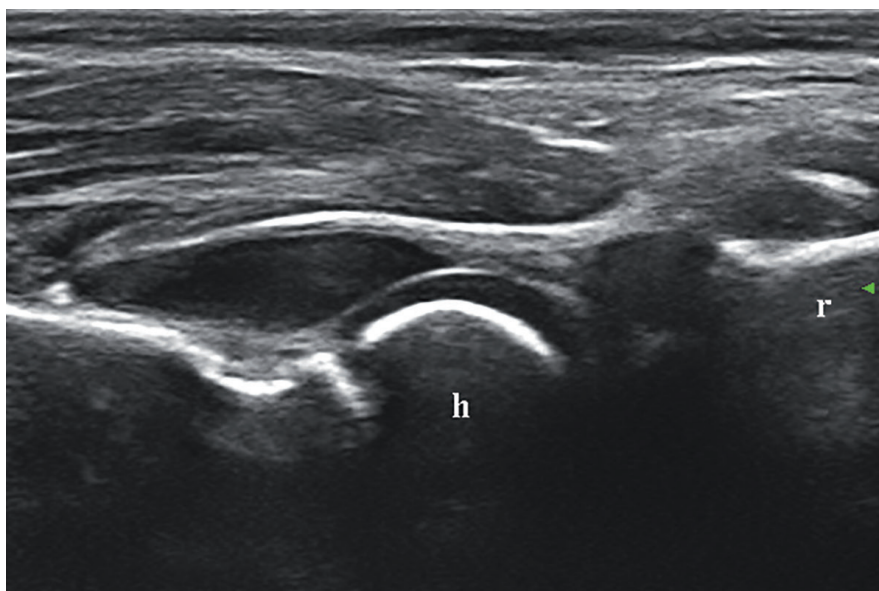
patients with treatment-naïve early RA who underwent US-guided synovial biopsy at the suprapatellar recess of the knee. GS and Doppler synovitis were measured quantitatively (*i.e.* pixel count for synovial area and synovial PD signal) and semiquantitatively (0–3 scale for GS synovial thickness and synovial PD signal). Quantitative and semiquantitative US parameters correlated with synovial vascular density and blood

vessel number density. Quantitative PD correlated well with tumour necrosis factor (TNF)- $\alpha$ , interleukin (IL)-1 $\beta$  and IL-6 gene expression (Spearman's rho 0.61, 0.69 and 0.59, respectively) and angiogenic factors such as vascular endothelial growth factor (VEGF)-A and VEGF-R3. GS synovial area correlated significantly with proinflammatory cytokine expression and angiogenic factors such as VEGF-A, Angiopoietin 2





**Fig. 3.** Longitudinal ultrasound image of the medial tibiofemoral space that shows a tear of the anterior horn of the medial meniscus with a meniscal cyst extending to the pes anserinus area in a patient with early knee osteoarthritis. f: femur; t: tibia.



**Fig. 4.** Longitudinal ultrasound image of the anterior recess of the elbow that shows synovitis in a 5-year-old patient with idiopathic juvenile arthritis. h: humerus; r: radius.

and tyrosine kinase (Tie) 2. Regarding lymphangiogenesis, a significant correlation was found between synovial area and VEGF-R3, VEGF-C, and podoplanin (Spearman's rho 0.61, 0.62 and 0.71, respectively). The authors concluded that both GS and PD synovitis reflect synovial inflammation in early RA.

Abe *et al.* (7) studied the relation between PD-scored (0-3) synovial flow and synovial histological findings in 215 joints (64 large joints and 151 small joints) from 177 RA patients who

underwent joint surgery. In both large and small joints, there was a strong correlation between the PD signal grade and Rooney total score (Spearman's rho 0.76,  $p < 0.001$ ) and between the PD signal grade and five of the individual Rooney scores; synoviocyte hyperplasia (Spearman's rho 0.55,  $p < 0.001$ ), fibrosis (Spearman's rho -0.54,  $p < 0.001$ ), perivascular infiltrates of lymphocytes (Spearman's rho 0.77,  $p < 0.001$ ), focal aggregates of lymphocytes (Spearman's rho 0.68,  $p < 0.001$ ) and diffuse infiltrates of lymphocytes

(Spearman's rho 0.77,  $p < 0.001$ ). The authors also concluded that PD-detected synovitis was a valid marker of synovial inflammation.

MSUS can be successfully used to guide synovial biopsy of large, medium size and small joints (8). Humby *et al.* (9) investigated the utility of minimally invasive, US-guided biopsies of small joints performed at baseline and after 3 or 6 months of disease modifying antirheumatic drug (DMARD) therapy in 35 RA patients from two clinical trials. GS synovial thickness and synovial PD signal were semiquantitatively scored (0-3) before biopsy. Good quality synovial tissue that accurately reflected the synovial immune phenotype of the total joint was obtained in 80% of US-guided procedures when synovial thickness was graded  $\geq 2$  before biopsy. In 100% of the procedures, sufficient RNA was extracted to permit molecular analysis. There was a significant correlation between change in sublining macrophage (CD68<sup>+</sup>) number and clinical response to treatment. Thus, the authors confirmed the validity of a technically simple procedure to obtain good quality synovial tissue from biopsies of small joints in RA.

The previous research group conducted another study (10) that aimed to assess the tolerability, safety and yield of synovial tissue in early arthritis patients using the previously tested US-guided

synovial biopsy procedure in small, medium size and large joints. They carried out 93 biopsies (baseline and 36 repeat biopsies at 6 months) of the knee, elbow, wrist, metacarpophalangeal (MCP) or proximal interphalangeal (PIP) joints from 57 patients. GS synovial thickness and synovial PD signal were semiquantitatively scored (0–3) before biopsy. No significant complications were reported after the procedure. The majority (93%) of biopsies yielding good quality tissue. RNA yield was good in all joints. Again, a prebiopsy high GS synovitis score was predictor of good quality and quantity of tissue and greater yield of RNA.

MSUS allows visualisation of a variable part of the articular cartilage. Onodera *et al.* (11) evaluated the validity of *in vivo* US scoring of metatarsal head articular cartilage as compared to *in vitro* US scoring and histologic scoring in 15 RA patients who underwent resection arthroplasty of the metatarsal heads. The articular cartilage was scored with US on a 1–6 scale of damage (1, blurred margin or partial lack of clarity, without thickness change; 6, no visualised cartilage band). The histologic scoring was performed blinded to the US findings and consisted of a 1–4 scale for the following changes; loss of matrix staining, surface fibrillation, deeper fissures or clefts, reduced thickness, and loss and erosion of cartilage. *In vivo* US scoring showed a significant correlation with both *in vitro* US scoring (Spearman's rho 0.74,  $p < 0.001$ ) and histologic scoring (Spearman's rho 0.67,  $p < 0.001$ ).

Mandl *et al.* (12) conducted a study aimed at validating US for measuring metacarpal cartilage thickness using anatomical measurement of 5 cadaver specimens as gold standard as well as assessing the relation between US-measured metacarpal cartilage thickness and radiographic joint space in 35 patients with RA. The results demonstrated a substantial agreement between US and anatomical metacarpal cartilage thickness (intraclass correlation coefficient 0.61). In addition, US metacarpal cartilage thickness of individual MCP joints showed a high correlation with individual MCP joint space width (Pearson's  $r$  0.72,  $p < 0.001$ ).

US operator-dependence is a major barrier to full implementation in clinical practice. Brulhart *et al.* (13) evaluated the reproducibility of a semiquantitative scoring system [Swiss Sonography in Arthritis and Rheumatism (SONAR) group] for synovitis and erosions in RA between 19 participants with various levels of expertise in US, using 6 US machines ranging from low to high quality. Concordance between ultrasonographers with high experience in US who used good quality machine was substantial (median kappa ( $\kappa$ ) 0.64 for GS and Doppler synovitis and 0.41 for erosions). However, agreement was worse for less experienced participants and/or low quality machines. These results highlight the importance of experience in MSUS and machine quality for appropriate use of this imaging modality in clinical practice.

#### Diagnostic performance

MSUS has been recommended to enhance the diagnostic capability of conventional clinical and laboratory approach in patients with preclinical RA or early undifferentiated arthritis (14). Rakieh *et al.* (15) prospectively assessed the predictive value of clinical, imaging, and serological features in relation to progression to inflammatory arthritis in 100 patients with non-specific MS symptoms and positive anticyclic citrullinated peptide (anti-CCP) antibodies. Fifty patients developed inflammatory arthritis after a median 7.9 months (0.1–52.4), the majority (86%) fulfilling the 2010 American College of Rheumatology/European League Against Rheumatism (EULAR) criteria for RA. Tenderness of hand or foot joints, early morning stiffness  $\geq 30$  min, high-positive autoantibodies, and positive PD synovial signal were predictors for high risk of progression to established arthritis.

#### Assessment of inflammation

MSUS has widely demonstrated greater sensitivity than clinical evaluation in detecting joint and tendon inflammation. This fact is particularly relevant in deep anatomic areas, which are difficult to assess by physical examination. Two studies (16, 17) compared MSUS and clinical assessment in the

detection of synovitis in the elbow and ankle joints. The results confirmed that MSUS was able to detect subclinical synovitis and enthesopathy in elbows (synovitis in 17.3% and enthesopathy in 14.1% of clinically normal elbows from 181 patients with inflammatory joint diseases) as well as subclinical synovitis in ankles (tibiotalar synovitis in 35% of asymptomatic ankles from 80 RA patients).

The presence of concomitant diseases such as fibromyalgia (FMG) frequently interferes with clinical assessment of RA and lead to an overestimation of the disease activity. In this scenario, MSUS can provide us with a more objective measure of inflammatory activity. Two studies (18, 19) investigated US inflammatory findings in RA patients with and without concomitant FMG. The results of both studies were consistent; while composite indexes of disease activity such as the Disease Activity Score (DAS) 28 were greater in RA patients with FMG, GS synovitis and, particularly Doppler synovitis did not differ in RA patients with and without FMG. Thus, it seems that US-assessed synovitis is not affected by FMG in RA patients.

US-detected synovitis has been associated in varying degree with other clinical and laboratory markers of inflammatory status or response to therapy in RA. In line with this, Hurnakova *et al.* (20) and Montoro *et al.* (21) evaluated the association of US-determined (*i.e.* semiquantitative scores of GS and Doppler synovitis) RA activity and serum calprotectin and native complement components, respectively. Hurnakova *et al.* (20) found a significant correlation between calprotectin levels and Doppler synovitis (Spearman's rho 0.50,  $p < 0.005$ ). Montoro *et al.* (21) reported that Doppler-determined disease inactive status but not clinically determined was associated with decrease in complement (C3) in RA patients treated with biologic therapy.

An important issue in clinical practice is whether MSUS can distinguish between joint inflammation due to RA or other diseases such as OA, which coexists with the former in many older patients. Glimm *et al.* (22) compared the amount (*i.e.* semiquantitative 0–3

score) and distribution of inflammation detected by GS and PD and fluorescence optical imaging in wrist and finger joints of 67 RA patients and 23 OA patients. GS US showed wrist and MCP joints mostly affected in RA and PIP and distal interphalangeal (DIP) joints in OA. Overall, PD synovitis was more frequent in RA patients than in OA patients except for DIP joints.

Several studies have shown the capability of US to detect relevant subclinical synovitis

in RA patients in clinical remission treated with either synthetic or biologic DMARDs, which has been related to silent structural damage progression and disease flare (23). Over the last year, a number of interesting papers on this topic have been published. Gärtner *et al.* (24), Harman *et al.* (25) and Tokai *et al.* (26) found subclinical GS and Doppler synovitis in a high percentage of RA patients in clinical remission. They also found that US-determined inactivity was related to longer duration of clinical inactivity. In addition, US inactivity was significantly associated with low radiographic structural damage (26).

Marks *et al.* (27) undertook a challenging study on tapering anti-TNF- $\alpha$  therapy, a recent strategy widely used in many countries, in 70 longstanding RA patients in sustained clinical remission with absence of PD synovitis in wrist and hand joints. Combined DAS28 and PDUS remission was maintained by 96% of patients at 3 month follow-up, 63% at 6 months, 37% at 9 months, and 34% at 18 months. The authors concluded that this combined clinical-US strategy may be useful to optimise the selection of patients for anti-TNF- $\alpha$  dose reduction.

Another relevant issue to address is the presence of US-detected synovitis in normal subjects. This is extremely important for an appropriate MSUS assessment of RA inflammatory activity. Kitchen *et al.* (28) evaluated 40 joint of 30 healthy subjects. As expected, GS synovitis was more frequent than Doppler synovitis and increased with aging. PD synovial signal was found only in the wrist (8%) and first metatarsophalangeal (MTP) joint (3%).

#### Quantification of inflammation

A great deal of interest has been focused on the feasibility of MSUS assessment of RA inflammatory activity, *i.e.* whether a reduced number of joints can replace a comprehensive assessment of global synovitis in RA patients (29). Aga *et al.* (30) conducted a study on developing and validating optimal sets of joints and tendons for a feasible US assessment of joint inflammation in 227 early RA and 212 established RA patients who started or change DMARD therapy. The authors identified 2 joint sets, *i.e.* bilateral 7 joints/2 tendons [MCP1, MCP2, PIP 3, radiocarpal, elbow, MTP1, MTP, tibialis posterior tendon, extensor carpi ulnaris tendon] and bilateral 9 joints/2 tendons [MCP5 and MTP5 added to the above set] that performed well in terms of retaining the information from a comprehensive assessment and responsiveness. However, Yoshimi *et al.* (31), obtained a 8-joint model [bilateral MCP2, MCP3, wrist, and knee joints] that represented well a comprehensive US assessment of synovitis in 234 RA patients.

Doppler synovitis is usually assessed subjectively on a semiquantitative 0-3 scale. In addition, Doppler assessment is particularly machine dependent. Two studies have addressed these relevant issues. Schmidt *et al.* (32) compared subjective scoring (0-3) with computerised quantification of synovial Doppler signal in 41 active RA patients. The distribution of the measured colour fraction by the assigned subjective scores was as follows; 0-6% for grade 1, >6-12% for grade 2 and >12% for grade 3. The authors suggested to reconsider the subjective scores for Doppler synovitis. On the other hand, Torp-Pedersen *et al.* (33) investigated the influence of PD and CD settings on different high- and intermediate-range US machines and evaluated the impact of these factors on Doppler scoring of synovitis. PD was more sensitive on half of the machines, whereas CD Doppler was more sensitive on the other half. In addition, there was an average increase in both CD and PD of 78% using modified settings instead of factory setting. The authors highlighted the great influence of the US machine and

the high impact of optimising Doppler settings on the quantification of inflammation.

#### Assessment of structural damage

MSUS is very sensitive in detecting early bone erosions in accessible joints such as those of hands and feet, which are target joints for early RA structural damage (34). However, the validity and reliability of US detection of bone erosions have not been fully addressed. Three-dimensional (3D) volumetric probes potentially reduce the operator-dependence and thus can be a useful tool in clinical practice and research. Peluso *et al.* (35) investigate the performance of 3DUS in the detection of bone erosions in hand and wrist joints of 20 early RA patients without erosions on radiography, using computed tomography (CT) as the reference method. The sensitivity, specificity, positive predictive value (PPV), and negative predictive value (NPV) of 3DUS as compared with CT were 0.9, 0.55, 0.71, and 0.83, respectively. Most 3DUS false-negatives were in the wrist joints and most 3DUS false-positives were in the PIP joints.

#### Monitoring of therapeutic response

Responsiveness of MSUS has been worthy of attention by the scientific community (36). Two recent studies provided new insights into this field (36, 37). D'Agostino *et al.* (37) undertook an international, multicentre, open-label, single-arm clinical trial to assess the responsiveness of a combined PD and GS synovitis score [Global OMERACT-EULAR Synovitis Score (GLOESS)] in patients with RA starting abatacept. Early improvement was observed in the synovitis components either in MCP joints or in 22 bilateral joints (*i.e.* PD at week 1, synovial hypertrophy at week 2, and joint effusion at week 4) with continuous improvement to week 24. DAS28 significantly decreased from weeks 1 to 24, reaching clinical meaningful improvement at week 8.

Iagnocco *et al.* (38) assessed the short-term (3 months) response to anti-TNF- $\alpha$  therapy in 68 RA patients using a 6-joint (*i.e.* bilateral wrist, MCP2, and knee joints) GS (synovial hyper-



trophy and effusion) and PD scoring (0–3) of synovitis. A significant decrease in the scores of the components of synovitis in all sites and in the global 6-joint score was shown, which moderately correlated with DAS28. These results confirmed the responsiveness of a feasible synovitis US assessment.

#### *Prognostication of outcomes*

There are previous solid results on the predictive value of US-detected synovitis, mainly Doppler synovitis, either in clinically active or inactive RA patients in relation to structural damage progression and disease flare or relapse. The results of the study by Sreerangaiah *et al.* (39) confirmed again that Doppler-detected synovial vascularity (either with 2D or 3D US) in wrist and MCP joints was highly associated with structural damage progression at 12 months in 85 RA patients with seropositive early RA. Naredo *et al.* (40) investigated the predictive value of US-detected synovitis in relation to failed tapering of biologic therapy in 77 RA patients in sustained clinical remission. At 12 months, 45.5% of patients presented BT tapering failure, 29.9% in the first 6 months. In logistic regression analysis, a baseline DAS28  $\geq 2.2$  and the presence of Doppler synovitis were identified as independent predictors of BT tapering failure at 6 and 12 months, being the presence of Doppler synovitis the strongest predictor (odds ratio (OR) at 6 months 13.91 95%CI 3.44–56.29,  $p < 0.0005$ ; OR at 12 months 29.92, 95% CI 6.81–131.40,  $p < 0.0005$ ). These results suggested that US may contribute to the selection of appropriate patients for biologic therapy tapering.

#### **Spondyloarthritis**

MSUS has been widely used to assess the peripheral joint, tendon and entheses involvement in SpA (41, 42).

#### *Validation*

Enthesitis is the hallmark of SpA. MSUS provides high-definition images of peripheral entheses. Falcao *et al.* (43) evaluated the construct validity of US-assessed Achilles enthesopathy in a 12-month longitudinal study on 146 early SpA patients. Throughout the

study, GS Achilles structure abnormalities and enthesal Doppler signal were significantly associated with clinical [*i.e.* Ankylosing Spondylitis Disease Activity Score (ASDAS)] and laboratory markers of disease activity (*i.e.* C-reactive protein (CRP) and erythrocyte sedimentation rate (ESR)).

Ventura-Ríos *et al.* (44) evaluated the inter-reader reliability between 18 ultrasonographers with different experience in 60 images of entheses from SpA patients and healthy controls. The results showed a variable agreement depending of the lesion assessed, being better between experts. Inter-reader reliability between experts was moderate for detection of structure and thickness changes, good for calcifications and bursitis, and excellent for erosions and enthesal Doppler signal. Again, the impact of experience in MSUS on a good reliability was evidenced in this study.

#### *Diagnostic performance*

Milutinovic *et al.* (45) conducted a study aimed at testing the capability of MSUS to distinguish enthesopathy from patients with and without SpA. They blindly assessed entheses thickness, echogenicity, enthesophytes, PD signal and erosions in the entheses of plantar fascia, Achilles, patellar, quadriceps and common extensor tendons in 76 patients with SpA, 26 with RA, and 25 with mechanically-related enthesopathy. Using logistic regression and receiver operating characteristic (ROC) curve analysis, they developed the Belgrade Ultrasound Enthesitis Score (BUSES), which represented a cumulative score of entheses lesions. BUSES cut-off point  $\geq 7$  achieved excellent specificity (90.2%) for identifying SpA patients.

The capability of MSUS to detect a variety of inflammatory findings in early psoriatic arthritis (PsA) was shown in the paper by Bandinelli *et al.* (46) who described wrist and hand US abnormalities in 112 cases. GS and PD synovitis, tenosynovitis, peritendinitis, and erosions were found independently of the clinical findings. In a study comparing US findings in the fingers of RA and PsA patients, Lin *et al.* (47) reported the presence of soft tissue inflamma-

tion, enthesopathy and tenosynovitis only in PsA patients.

Little attention has been paid to the US assessment of the joints of the anterior chest wall (ACW) in SpA. In a case-control study, Verhoeven *et al.* (48) described a frequent involvement of the ACW joints in SpA patients (36.5% of 131 patients), mainly US-detected bone changes in the sternoclavicular and manubriosternal joints that were associated with disease duration and radiographic sacroiliitis.

#### *Assessment of inflammation*

Acquacalda *et al.* (49) compared US-assessed enthesopathy in 10 entheses of 34 patients with psoriasis (Ps) requiring systemic treatment, 22 without MS symptoms and 12 with PsA. The authors found a high prevalence of US abnormalities in Ps patients either with or without MS symptoms. After 6 months of systemic therapy, US morphological abnormalities significantly improved in Ps patients without MS and in PsA patients.

The study by Janta *et al.* (50) dealt with US assessment of synovitis, tenosynovitis, enthesopathy, and paratenonitis in PsA patients treated with full (74 patients) and tapered (28 patients) dosage of biologic DMARDs. The authors found no significant differences between US variables, both for BM and CD between patients with full and tapered dosage and between patients with and without concomitant synthetic DMARDs.

#### *Monitoring of therapeutic response*

Two recent studies by Ruta *et al.* (51) and Wang *et al.* (52) showed responsiveness of US-detected inflammatory changes at joint, tendon, and enthesal level in active SpA patients who began an effective treatment. Particularly, Wand *et al.* (52) demonstrated responsiveness of GS and PD abnormalities in the Achilles tendon of ankylosing spondylitis patients after 3 months of anti-TNF- $\alpha$  therapy.

#### *Prognostication of outcomes*

Little research has been done on the predictive value of MSUS in PsA. El Miedany *et al.* (53) prospectively in-

vestigated the predictive value of US-detected inflammation in relation to radiographic structural damage progression in 126 early PsA patients. Baseline GS score  $\geq 2$ , PD score  $\geq 2$ , presence of B-mode and Doppler enthesopathy as well as persistent US synovitis and enthesitis at 6 months were predictors of progressive early PsA and structural damage development.

#### *International recommendations*

Recently, EULAR has produced evidence-based recommendations on the use of imaging in the clinical management of both axial and peripheral SpA (54). According to these recommendations, MSUS may be used to detect peripheral enthesitis, which may support the diagnosis of SpA or to detect peripheral synovitis, tenosynovitis and bursitis and to monitor synovitis and enthesitis in peripheral SpA.

#### **Osteoarthritis**

MSUS offers a comprehensive assessment of the OA joint (55, 56).

#### *Validation*

Again, US reliability has been noteworthy for international research groups. Bruyn *et al.* (57) on behalf of the OMERACT MSUS group assessed the intra- and interobserver reliability of MSUS for evaluating inflammatory and structural abnormalities in patients with knee OA. Eleven experienced ultrasonographers semiquantitatively scored knee synovitis, osteophytes, femoral cartilage damage and meniscal damage. Intra- and interobserver reliability were moderate to good for synovitis (mean  $\kappa$  0.67 and 0.52, respectively), and fair to good for cartilage damage, medial meniscal damage and osteophytes (mean  $\kappa$  0.55 and 0.34, 0.75 and 0.56, 0.73 and 0.60, respectively).

Koski *et al.* (58) also investigated the intra- and inter-reader reliability of MSUS and radiography for detecting and semiquantitatively scoring osteophytes in the tibiofemoral joint between 14 readers, using a novel reference atlas as support. Overall, intra- and inter-reader US and radiography agreements were substantial ( $\kappa$  0.60–0.72). US detected more osteophytes than CR at

both the medial (65% vs. 48%) and lateral (70% vs. 60%) compartments.

#### *Monitoring of therapeutic response*

There is little information of the responsiveness of MSUS findings in OA. The study by Keen *et al.* (59) aimed to test whether US was able to detect synovial response to intra-articular corticosteroid (IACS) injections in 35 patients with knee OA. GS synovial thickness and PD score decreased in 16 and 13, respectively of 19 patients who received IACS injection and both were substantively associated with reduction in pain  $\geq$  to the minimum clinically important improvement.

#### *Prognostication of outcomes*

The role that inflammation plays in the pathogenesis of OA is under investigation. Over the last year, four novel studies have dealt with this issue, two of them focused on hand OA (60, 61) and two studies on knee OA (62, 63). Kortekaas *et al.* (60) and Mancarella *et al.* (61) investigated the longitudinal association between US-detected inflammatory findings and radiographic progression in patients with hand OA (56 and 22 patients, respectively) after 2–4 years of followup. Both groups obtained comparable results; PD synovitis was associated with radiographic worsening, particularly with bone erosion development or progression. However, in the study by Kortekaas *et al.* (60) GS synovial thickening was also associated with erosive deterioration. Mathiessen *et al.* (62) assessed the predictive value of US-detected knee inflammation in relation to radiographic progression in 78 patients with knee OA. In this study, US-detected synovitis predicted OA progression according to the Kellgren-Lawrence (K-L) scale after 5 years of followup as follows; for GS synovitis grade 1, OR 2.8 (95% CI 1.8–4.2); grade 2, OR 3.6 (95% CI 2.2–5.8); and grade 3, OR 15.2 (95% CI 6.9–33.6) and for PD synovitis grade 1, OR 2.9 (95% CI 1.2–6.8); and grades 2–3, OR 12.0 (95% CI 3.5–41.0). In 125 patients with knee OA, Bevers *et al.* (63) found that the presence on US mainly of Baker's cyst but also synovial hypertrophy were associated with radiographic progres-

sion after 2 years of followup. Further studies on potential therapeutic strategies targeting inflammation in OA are warranted.

#### *Assessment of associated abnormalities*

Periarticular complaints are frequent in knee OA. Two recent studies (64, 65) evaluated the pes anserinus tendon insertion in patients with knee OA. Toktas *et al.* (64) found that the mean pes anserinus thickness was significantly greater in 157 patients with knee OA with or without clinical anserine tendinitis-bursitis syndrome than in 30 healthy controls. In addition, the mean pes anserinus thickness in OA knees K-L graded 3 and 4 was greater than in OA knees K-L graded 1 and 2, independently of the presence of anserine symptoms. Uysal *et al.* (65) found pes anserine bursitis in 20% of 85 patients with knee OA. There was a significant positive correlation between both the longest length and area of the bursitis and the OA K-L grade. Both groups concluded that MSUS may be helpful to detect pes anserinus abnormalities associated with knee OA that can benefit from specific treatment.

#### **Juvenile idiopathic arthritis**

Over the past years, MSUS has been increasingly implemented in paediatric rheumatology. The non-invasive and friendly nature of this imaging modality makes it particularly suitable for children care (66, 67).

#### *Validation*

The OMERACT MSUS group has put much effort into validating MSUS in paediatric rheumatic diseases, starting with JIA. Two novel studies (68, 69) have provided extremely useful data on the normal age-related sonoanatomy and vascularisation of joints and entheses in healthy children. In addition, the OMERACT MSUS group has produced agreed definitions for the component of the normal paediatric joints (*i.e.* articular bone, cartilage, joint capsule, epiphyseal ossification centre, and synovial membrane) whose applicability has been successfully tested in standardised US scans of representative

normal joints by an international panel (70).

Pradsgaard *et al.* (71) carried out a study aiming at comparing US with magnetic resonance imaging (MRI) measurements of distal femoral cartilage thickness in the knee joint of 23 children with oligoarticular JIA. The authors found a high level of agreement between MRI and US measurements of the cartilage thickness (Spearman's Rho 0.70–0.86).

#### Assessment of inflammation

Synovial angiogenesis is involved in the pathogenesis of JIA. Świdrowska *et al.* (72) assessed the relation between the levels of angiogenic markers and US inflammatory findings in 43 early JIA children and 23 healthy controls. PD-detected joint vascularisation correlated with serum VEGF, supporting the inflammatory nature of both biomarkers.

#### Management

Nieto *et al.* (73) evaluated the extent to which MSUS may influence the diagnosis and management decisions in daily clinical practice in paediatric rheumatology. Of 111 patients who attended a busy paediatric rheumatology unit over a 3-month period (45.9% diagnosed with JIA), 65 (58.6%) patients qualified for MSUS. Of the 65 patients undergoing MSUS, in 38 (58.5%) patients there was a change in diagnosis, therapeutic decisions or both following the MSUS information. The authors concluded that MSUS may play a relevant role in local diagnosis and therapeutic decisions and could help in the management of rheumatic diseases in children.

The utility of US as guidance for injection targeting challenging anatomic area is supported by the study by Young *et al.* (74) which described a successful and safe technique for US-guided corticosteroid injection in the subtalar joint of 122 children with JIA.

#### International recommendations

Recently, EULAR and the Paediatric Rheumatology European Society (PRES) have developed evidence-based points to consider for the use of imaging in the diagnosis and management of JIA

in clinical practice (75). This document highlights the superiority of MSUS over clinical assessment in detection of joint inflammation and thus MSUS should be considered in diagnosis JIA and assessment of extension of joint involvement. In addition, MSUS may be used to detect early joint damage and to monitor disease activity as well as US-detected inflammation may be considered a prognostic indicator. Finally, US can be used for accurate placement of intra-articular injections.

In conclusion, 2015 has provided us with novel insights into the validity and utility of MSUS in arthritis that enhance the applicability of this imaging modality in rheumatologic practice and encourage further research in this field.

#### References

1. KEEN HI, WAKEFIELD R, CONAGHAN PG: Optimising ultrasonography in rheumatology. *Clin Exp Rheumatol* 2014; 32: S-13-6.
2. KOSKI JM, HAMMER HB: Ultrasound-guided procedures: techniques and usefulness in controlling inflammation and disease progression. *Rheumatology* (Oxford) 2012; 51: vii31-vii35.
3. BRUYN GA, NAREDO E, IAGNOCCO A *et al.*: OMERACT Ultrasound Task Force. The OMERACT Ultrasound Working Group 10 Years On: Update at OMERACT 12. *J Rheumatol* 2015; 42: 2172-6.
4. OHRNDORF S, BACKHAUS M: Pro musculoskeletal ultrasonography in rheumatoid arthritis. *Clin Exp Rheumatol* 2015; 33 (Suppl. 92): S50-3.
5. MANDL P, KURUCZ R, NIEDERMAYER D, BALINT PV, SMOLEN JS: Contributions of ultrasound beyond clinical data in assessing inflammatory disease activity in rheumatoid arthritis: current insights and future prospects. *Rheumatology* (Oxford) 2014; 53: 2136-42.
6. KELLY S, BOMBARDIERI M, HUMBY F *et al.*: Angiogenic gene expression and vascular density are reflected in ultrasonographic features of synovitis in early Rheumatoid Arthritis: an observational study. *Arthritis Res Ther* 2015; 17: 58.
7. ABE A, ISHIKAWA H, NAKAZONO K, MURASAWA A, WAKAKI K: A comparison of the ultrasonography images of the joints of patients with rheumatoid arthritis and the corresponding synovial histological findings. *Mod Rheumatol* 2015 Nov 20; 1-6 [Epub ahead of print].
8. LAZAROU I, D'AGOSTINO MA, NAREDO E, HUMBY F, FILER A, KELLY SG: Ultrasound-guided synovial biopsy: a systematic review according to the OMERACT filter and recommendations for minimal reporting standards in clinical studies. *Rheumatology* (Oxford) 2015; 54: 1867-75.
9. HUMBY F, KELLY S, HANDS R *et al.*: Use of ultrasound-guided small joint biopsy to evaluate the histopathologic response to rheumatoid arthritis therapy: recommendations for application to clinical trials. *Arthritis Rheumatol* 2015; 67: 2601-10.
10. KELLY S, HUMBY F, FILER A *et al.*: Ultrasound-guided synovial biopsy: a safe, well-tolerated and reliable technique for obtaining high-quality synovial tissue from both large and small joints in early arthritis patients. *Ann Rheum Dis* 2015; 74: 611-7.
11. ONODERA T, KASAHARA Y, KASEMURA T, SUZUKI Y, KONDO E, IWASAKI N: A comparative study with *in vitro* ultrasonographic and histologic grading of metatarsal head cartilage in rheumatoid arthritis. *Foot Ankle Int* 2015; 36: 774-9.
12. MANDL P, SUPP G, BAKSA G *et al.*: Relationship between radiographic joint space narrowing, sonographic cartilage thickness and anatomy in rheumatoid arthritis and control joints. *Ann Rheum Dis* 2015; 74: 2022-7.
13. BRULHART L, ZISWILER HR, TAMBORRINI G, ZUFFEREY P; SONAR/SCQM PROGRAMMES: The importance of sonographer experience and machine quality with regards to the role of musculoskeletal ultrasound in routine care of rheumatoid arthritis patients. *Clin Exp Rheumatol* 2015; 33: 98-101.
14. COLEBATCH AN, EDWARDS CJ, ØSTERGAARD M *et al.*: EULAR recommendations for the use of imaging of the joints in the clinical management of rheumatoid arthritis. *Ann Rheum Dis* 2013; 72: 804-14.
15. RAKIEH C, NAM JL, HUNT L *et al.*: Predicting the development of clinical arthritis in anti-CCP positive individuals with non-specific musculoskeletal symptoms: a prospective observational cohort study. *Ann Rheum Dis* 2015; 74: 1659-66.
16. USON J, MIGUÉLEZ-SÁNCHEZ R, DE LOS RISCOS M *et al.*: Elbow clinical, ultrasonographic and radiographic study in patients with inflammatory joint diseases. *Rheumatol Int* 2015 Nov 23 [Epub ahead of print].
17. ALSUWAIDI M, EHRENSTEIN B, FLECK M, HARTUNG W: Asymptomatic versus symptomatic ankle joints in rheumatoid arthritis: A high resolution B-mode and power Doppler ultrasound study. *Arthritis Care Res* (Hoboken) 2015 Sep 28 [Epub ahead of print].
18. GHIB LJ, TĂMAȘ MM, DAMIAN LO *et al.*: The role of ultrasonography in assessing disease activity in patients with rheumatoid arthritis and associated fibromyalgia. *Med Ultrason* 2015; 17: 339-44.
19. DA SILVA CHAKR RM, BRENOL JC, BEHAR M *et al.*: Is ultrasound a better target than clinical disease activity scores in rheumatoid arthritis with fibromyalgia? A case-control study. *PLoS One* 2015; 10: e0118620.
20. HURNAKOVA J, ZAVADA J, HANOVA P *et al.*: Serum calprotectin (S100A8/9): an independent predictor of ultrasound synovitis in patients with rheumatoid arthritis. *Arthritis Res Ther* 2015; 17: 252.
21. MONTORO ALVAREZ M, CHONG OY, JANTA I *et al.*: Relation of Doppler ultrasound synovitis versus clinical synovitis with changes in native complement component levels in rheumatoid arthritis patients treated with biologic disease-modifying anti-rheumatic drugs. *Clin Exp Rheumatol* 2015; 33: 141-5.



22. GLIMM AM, WERNER SG, BURMEISTER GR, BACKHAUS M, OHRNDORF S: Analysis of distribution and severity of inflammation in patients with osteoarthritis compared to rheumatoid arthritis by ICG-enhanced fluorescence optical imaging and musculoskeletal ultrasound: a pilot study. *Ann Rheum Dis* 2015 Aug 26 [Epub ahead of print].
23. NGUYEN H, RUYSEN-WITRAND A, GANDBAKHCH F, CONSTANTIN A, FOLTZ V, CANTAGRELA: Prevalence of ultrasound-detected residual synovitis and risk of relapse and structural progression in rheumatoid arthritis patients in clinical remission: a systematic review and meta-analysis. *Rheumatology* (Oxford) 2014; 53: 2110-8.
24. GÄRTNER M, ALASTI F, SUPP G, MANDL P, SMOLEN JS, ALETAHA D: Persistence of subclinical sonographic joint activity in rheumatoid arthritis in sustained clinical remission. *Ann Rheum Dis* 2015; 74: 2050-3.
25. HARMAN H, TEKEOĞLU I, KABAN N, HARMAN S: Factors influencing ultrasonographic remission in patients with rheumatoid arthritis. *Rheumatol Int* 2015; 35: 485-91.
26. TOKAI N, OGASAWARA M, GORAI M *et al.*: Predictive value of bone destruction and duration of clinical remission for subclinical synovitis in rheumatoid arthritis patients. *Mod Rheumatol* 2015; 25: 540-5.
27. MARKS JL, HOLROYD CR, DIMITROV BD *et al.*: Does combined clinical and ultrasound assessment allow selection of individuals with rheumatoid arthritis for sustained reduction of anti-tumor necrosis factor therapy?. *Arthritis Care Res* (Hoboken) 2015; 67: 746-53.
28. KITCHEN J, KANE D: Greyscale and power Doppler ultrasonographic evaluation of normal synovial joints: correlation with pro- and anti-inflammatory cytokines and angiogenic factors. *Rheumatology* (Oxford) 2015; 54: 458-62.
29. MANDL P, NAREDO E, WAKEFIELD RJ *et al.*: A systematic literature review analysis of ultrasound joint count and scoring systems used to assess synovitis in rheumatoid arthritis, according to the OMERACT filter. *J Rheumatol* 2011; 38: 2055-62.
30. AGA AB, HAMMER HB, OLSEN IC *et al.*: First step in the development of an ultrasound joint inflammation score for rheumatoid arthritis using a data-driven approach. *Ann Rheum Dis* 2015 Jun 17 [Epub ahead of print].
31. YOSHIMI R, IHATA A, KUNISHITA Y *et al.*: A novel 8-joint ultrasound score is useful in daily practice for rheumatoid arthritis. *Mod Rheumatol* 2015; 25: 379-85.
32. SCHMIDT WA, SCHÖNAU V, REICHE BE, OBERDORFER PD, OHRNDORF S, BACKHAUS M: Grading of ultrasound Doppler signals in synovitis: does it need an update?. *Rheumatology* (Oxford) 2015; 54: 1897-903.
33. TORP-PEDERSEN S, CHRISTENSEN R, SZKUDLAREK M *et al.*: Power and color Doppler ultrasound settings for inflammatory flow: impact on scoring of disease activity in patients with rheumatoid arthritis. *Arthritis Rheumatol* 2015; 67: 386-95.
34. SZKUDLAREK M, TERSLEV L, WAKEFIELD RJ *et al.*: Summary findings of a systematic literature review of the ultrasound assessment of bone erosions in rheumatoid arthritis. *J Rheumatol* 2015; 43: 12-21.
35. PELUSO G, BOSELLO SL, GREMESE E *et al.*: Detection of bone erosions in early rheumatoid arthritis: 3D ultrasonography versus computed tomography. *Clin Rheumatol* 2015; 34: 1181-6.
36. IAGNOCO A, NAREDO E, WAKEFIELD R *et al.*: Responsiveness in Rheumatoid Arthritis. A report from the OMERACT 11 Ultrasound Workshop. *J Rheumatol* 2014; 41: 379-82.
37. D'AGOSTINO MA, WAKEFIELD RJ, BERNERHAMMER H *et al.*: Value of ultrasonography as a marker of early response to abatacept in patients with rheumatoid arthritis and an inadequate response to methotrexate: results from the APPRAISE study. *Ann Rheum Dis* 2015 Nov 20 [Epub ahead of print].
38. IAGNOCO A, FINUCCI A, CECCARELLI F, PERRICONE C, IORGOVEANU V, VALESINI G: Power Doppler ultrasound monitoring of response to anti-tumour necrosis factor alpha treatment in patients with rheumatoid arthritis. *Rheumatology* (Oxford) 2015; 54: 1890-6.
39. SREERANGAIAH D, GRAYER M, FISHER BA, HO M, ABRAHAM S, TAYLOR PC: Quantitative power Doppler ultrasound measures of peripheral joint synovitis in poor prognosis early rheumatoid arthritis predict radiographic progression. *Rheumatology* (Oxford) 2016; 55: 89-93.
40. NAREDO E, VALOR L, DE LA TORRE I *et al.*: Predictive value of Doppler ultrasound-detected synovitis in relation to failed tapering of biologic therapy in patients with rheumatoid arthritis. *Rheumatology* (Oxford) 2015; 54: 1408-14.
41. BALINT PV, D'AGOSTINO MA: Spondyloarthritis: a journey within and around the joint. *Rheumatology* (Oxford) 2012; 51: vii13-vii17.
42. DELLE SEDIE A, RIENTE L: Psoriatic arthritis: what ultrasound can provide us. *Clin Exp Rheumatol* 2015; 33: S60-5.
43. FALCAO S, CASTILLO-GALLEGO C, PEITEADO D, BRANCO J, MARTÍN MOLA E, DE MIGUEL E: Can we use entheses ultrasound as an outcome measure of disease activity in spondyloarthritis? A study at the Achilles level. *Rheumatology* (Oxford) 2015; 54: 1557-62.
44. VENTURA-RÍOS L, NAVARRO-COMPAN V, ALISTE M *et al.*: Is entheses ultrasound reliable? A reading Latin American exercise. *Clin Rheumatol* 2015 Jul 22 [Epub ahead of print].
45. MILUTINOVIC S, RADUNOVIC G, VELJKOVIC K *et al.*: Development of ultrasound enthesitis score to identify patients with enthesitis having spondyloarthritis: prospective, double-blinded, controlled study. *Clin Exp Rheumatol* 2015; 33: 812-7.
46. BANDINELLI F, DENARO V, PRIGNANO F, COLLAKU L, CIANCIO G, MATUCCI-CERINIC M: Ultrasonographic wrist and hand abnormalities in early psoriatic arthritis patients: correlation with clinical, dermatological, serological and genetic indices. *Clin Exp Rheumatol* 2015; 33: 330-5.
47. LIN Z, WANG Y, MEI Y, ZHAO Y, ZHANG Z: High-frequency ultrasound in the evaluation of psoriatic arthritis: a clinical study. *Am J Med Sci* 2015; 350: 42-6.
48. VERHOEVEN F, GUILLOT X, GODFRIN-VALNET M, PRATI C, WENDLING D: Ultrasonographic evaluation of the anterior chest wall in spondyloarthritis: a prospective and controlled study. *J Rheumatol* 2015; 42: 87-92.
49. ACQUACALDA E, ALBERT C, MONTAUDIE H *et al.*: Ultrasound study of entheses in psoriasis patients with or without musculoskeletal symptoms: A prospective study. *Joint Bone Spine* 2015; 82: 267-71.
50. JANTA I, MARTÍNEZ-ESTUPIÑÁN L, VALOR L *et al.*: Comparison between full and tapered dosages of biologic therapies in psoriatic arthritis patients: clinical and ultrasound assessment. *Clin Rheumatol* 2015; 34: 935-42.
51. RUTA S, ACOSTA FELQUER ML, ROSA J, NAVARTA DA, GARCÍA MONACO R, SORIANO ER: Responsiveness to therapy change of a global ultrasound assessment in spondyloarthritis patients. *Clin Rheumatol* 2015; 34: 125-32.
52. WANG CH, FENG Y, REN Z *et al.*: Performance of ultrasound to monitor Achilles enthesitis in patients with ankylosing spondylitis during TNF- $\alpha$  antagonist therapy. *Clin Rheumatol* 2015; 34: 1073-8.
53. EL MIEDANY Y, EL GAFFARY M, YOUSSEF S, AHMED I, NASR A: Tailored approach to early psoriatic arthritis patients: clinical and ultrasonographic predictors for structural joint damage. *Clin Rheumatol* 2015; 34: 307-13.
54. MANDL P, NAVARRO-COMPÁN V, TERSLEV L *et al.*: European League Against Rheumatism (EULAR). EULAR recommendations for the use of imaging in the diagnosis and management of spondyloarthritis in clinical practice. *Ann Rheum Dis* 2015; 74: 1327-39.
55. MEENAGH G, FILIPPUCCI E, IAGNOCO A *et al.*: Ultrasound imaging for the rheumatologist VIII. Ultrasound imaging in osteoarthritis. *Clin Exp Rheumatol* 2007; 25: 172-5.
56. IAGNOCO A, NAREDO E: Osteoarthritis: research update and clinical applications. *Rheumatology* (Oxford) 2012; 51: vii2-vii5.
57. BRUYN GA, NAREDO E, DAMJANOV N *et al.*: An OMERACT reliability exercise of inflammatory and structural abnormalities in patients with knee osteoarthritis using ultrasound assessment. *Ann Rheum Dis* 2015 Apr 22 [Epub ahead of print].
58. KOSKI JM, KAMEL A, WARIS P *et al.*: Atlas-based knee osteophyte assessment with ultrasonography and radiography: relationship to arthroscopic degeneration of articular cartilage. *Scand J Rheumatol* 2015 Sep 1: 1-7 [Epub ahead of print].
59. KEEN HI, HENSOR EM, WAKEFIELD RJ, MEASE PJ, BINGHAM CO 3RD, CONAGHAN PG: Ultrasound assessment of response to intra-articular therapy in osteoarthritis of the knee. *Rheumatology* (Oxford) 2015; 54: 1385-91.
60. KORTEKAAS MC, KWOK WY, REIJNERS M, STIJNEN T, KLOPPENBURG M: Inflammation is associated with erosive development in patients with hand osteoarthritis: A prospective ultrasonography study. *Arthritis Rheumatol* 2016; 68: 392-7.
61. MANCARELLA L, ADDIMANDA O, PELOTTI P, PIGNOTTI E, PULSATELLI L, MELICONI R: Ultrasound detected inflammation is associated with the development of new bone erosions in hand osteoarthritis: a longitudinal

- study over 3.9 years. *Osteoarthritis Cartilage* 2015; 23: 1925-32.
62. MATHIESSEN A, SLATKOWSKY-CHRISTENSEN B, KVIEN TK, HAMMER HB, HAUGEN IK: Ultrasound-detected inflammation predicts radiographic progression in hand osteoarthritis after 5 years. *Ann Rheum Dis* 2015 Apr 1 [Epub ahead of print].
  63. BEVERS K, VRIEZKOLK JE, BIJLSMA JW, VAN DEN ENDE CH, DEN BROEDER AA: Ultrasonographic predictors for clinical and radiological progression in knee osteoarthritis after 2 years of follow-up. *Rheumatology (Oxford)* 2015; 54: 2000-3.
  64. TOKTAS H, DUNDAR U, ADAR S, SOLAK O, ULASLI AM: Ultrasonographic assessment of pes anserinus tendon and pes anserinus tendinitis bursitis syndrome in patients with knee osteoarthritis. *Mod Rheumatol* 2015; 25: 128-33.
  65. UYSAL F, AKBAL A, GÖKMEN F, ADAM G, REŞORLU M: Prevalence of pes anserine bursitis in symptomatic osteoarthritis patients: an ultrasonographic prospective study. *Clin Rheumatol* 2015; 34: 529-33.
  66. COLLADO RAMOS P: Ultrasound imaging in juvenile idiopathic arthritis for the rheumatologist. *Clin Exp Rheumatol* 2014; 32 (Suppl. 80): S34-41.
  67. RAMOS PC, CECCARELLI F, JOUSSE-JOULIN S: Role of ultrasound in the assessment of juvenile idiopathic arthritis. *Rheumatology (Oxford)* 2012; 51: vii10-2.
  68. COLLADO P, VOJINOVIC J, NIETO JC *et al.*: Omeract Ultrasound Pediatric Group. Toward standardized musculoskeletal ultrasound in pediatric rheumatology: Normal age related ultrasound findings. *Arthritis Care Res (Hoboken)* 2015 Jul 20 [Epub ahead of print].
  69. JOUSSE-JOULIN S, CANGEMI C, GERARD S *et al.*: Normal sonoanatomy of the paediatric entheses including echostructure and vascularisation changes during growth. *Eur Radiol* 2015; 25: 2143-52.
  70. ROTH J, JOUSSE-JOULIN S, MAGNI-MANZONI S *et al.*: Definitions for the sonographic features of joints in healthy children. *Arthritis Care Res (Hoboken)* 2015; 67: 136-42.
  71. PRADSGAARD DØ, FIIRGAARD B, SPANNOV AH, HEUCK C, HERLIN T: Cartilage thickness of the knee joint in juvenile idiopathic arthritis: comparative assessment by ultrasonography and magnetic resonance imaging. *J Rheumatol* 2015; 42: 534-40.
  72. ŚWIDROWSKA J, SMOLEWSKI P, STAŃCZYK J, SMOLEWSKA E: Serum angiogenesis markers and their correlation with ultrasound-detected synovitis in juvenile idiopathic arthritis. *J Immunol Res* 2015; 2015: 741457.
  73. NIETO-GONZÁLEZ JC, MONTEAGUDO I, VARGAS-HENNY L *et al.*: Impact of musculoskeletal ultrasound on clinical practice in paediatric rheumatology. *Clin Exp Rheumatol* 2015; 33: 583-7.
  74. YOUNG CM, HORST DM, MURAKAMI JW, SHIELS WE 2<sup>ND</sup>: Ultrasound-guided corticosteroid injection of the subtalar joint for treatment of juvenile idiopathic arthritis. *Pediatr Radiol* 2015; 45: 1212-7.
  75. COLEBATCH-BOURN AN, EDWARDS CJ, COLLADO P *et al.*: EULAR-PreS points to consider for the use of imaging in the diagnosis and management of juvenile idiopathic arthritis in clinical practice. *Ann Rheum Dis* 2015; 74: 1946-57.