

Widespread nocardiosis in two patients with Behçet's disease

C. Korkmaz¹, A. Aydinli²,
N. Erol³, N. Yildirim³,
Y. Akgün², R. Inci⁴,
P. Boiron⁵

¹Department of Internal Medicine, Division of Rheumatology, ²Department of Microbiology, ³Department of Ophthalmology, Faculty of Medicine, Osmangazi University, Eskişehir, Turkey; ⁴Faculty of Medicine, Department of Microbiology, Ege University, İzmir, Turkey; ⁵University of Claude Bernard, Faculty of Pharmacology, Lyon, France.

Cengiz Korkmaz, MD, Assistant professor; Aydin Aydinli, MD, Assistant professor; Nazmiye Erol, MD; Nilgün Yildirim, MD, Professor of Ophthalmology; Yurdanur Akgün, MD, Professor of Microbiology, Department of Microbiology; Ramazan Inci, Professor of Microbiology; Patrick Boiron, Professor of Microbiology.

Please address correspondence to: Cengiz Korkmaz, Visnelik Mah, Ali Fuat Güven Cad. Akasya Sok. 11/11, 26020 Eskişehir, Turkey.

E-mail: ckorkmaz@ogu.edu.tr

Received on July 26, 2000; accepted in revised form on December 6, 2001.

© Copyright CLINICAL AND EXPERIMENTAL RHEUMATOLOGY 2001.

Key words: Behçet's disease, opportunistic infections, nocardiosis.

ABSTRACT

Nocardia spp., a group of gram-positive variably acid-fast aerobic bacteria, are opportunistic pathogens in immunocompromised hosts. We here within describe 2 cases of widespread nocardiosis in patients with Behçet's disease. In addition to endogenous endophthalmitis in case 1, both cases developed lung, brain and skin involvement. Despite brain involvement, the prognosis was good, although vision was completely lost in case 1, which was directly attributable to a delay in both diagnosis and treatment.

Introduction

Behçet's disease is characterized by recurrent oral aphthae, genital ulcers and uveitis with retinal vasculitis. Severe organ involvement such as eye, brain and lung vessels are effectively treated by glucocorticoids and cytotoxic drugs (1,2). However, these drugs may lead to opportunistic infections. No cases of nocardiosis have been reported in Behçet's disease (BD) yet. We describe a widespread nocardiosis in two patients with BD and discuss some of the similar clinical findings in these two diseases.

Case 1

A 29 year-old man was referred to our hospital on 5 May 1998 due to continuous fever, cough, pleuritic chest pain, and a decrease in visual acuity in the right eye. He had a history of BD based on the clinical features of recurrent oral and genital aphthous ulcerations, papulopustular skin lesions and a positive pathergy test for 8 years. He had been taking fluocortolone 10 mg/day and azathioprine 150 mg/day for the preceding 3 years for the management of flares of posterior uveitis.

Upon admission, he had dyspnoea and high fever (39.8°C). He also had Cushingoid. His ophthalmological examination disclosed cells and flare in the anterior chamber. There was hypopyon and fibrin deposition in the posterior chamber and on the intraocular lens. The visual acuity was of light perception. Crackles were audible over both lungs. Laboratory findings were as follows: hemoglobin 12 gr/dl, white blood

cells (WBC) 21,400 mm³, erythrocyte sedimentation rate (ESR) 105 mm/h, C-reactive protein (CRP) 55 mg/dl, serum glucose level 98 mg/dl. PPD was negative. His chest roentgenogram revealed pneumonic infiltrations with cavitations in the upper and middle zones of the right lung. The cultures of blood, sputum and bronchoalveolar lavage (BAL) were negative. These findings were considered to be an exacerbation of Behçet's uveitis and non-specific lung infection. Azathioprine and fluocortolone were halted. Intravenous ceftazidime and oral claritromycin, along with topical steroid drops and mydriatic, were given. Fifteen days later his fever had dissipated with clearing of the lungs on chest roentgenogram while his right eye findings did not improve. The patient was discharged with oral claritromycin and topical eye drops.

On 28 May 1998 the patient was readmitted to our hospital due to tender, mild fluctuant nodular lesions spreading over the dorsal, abdominal and perianal regions and severe orbital pain in the right eye. An ophthalmological examination revealed severe eyelid oedema, conjunctival injection and hypopyon in the anterior chamber. He had fever of 39.5°C. This status was considered to be endogenous endophthalmitis and parenteral ceftriaxone and ciprofloxacin were concurrently started with topical antibiotics. An orbital computed tomography revealed increased heterogeneous density in the vitreous of the right eye (Fig. 1a). On 6 June 1998 his sclera perforated and pus leaked. Gram positive filamentous organisms were found in the specimens obtained from the right eye and skin abscesses. This bacteria was identified as *Nocardia asteroides* after microbiological tests. Immediately after the diagnosis of nocardiosis, the treatment was changed to intramuscular trimethoprim (6400 mg) and sulfamethoxazole (1280 mg) (TMP-SMX) per day. A part of the abscess specimen culture was sent to Claude Bernard University (Lyon, France) and Ege University, Faculty of Medicine (İzmir, Turkey), where *N. asteroides* was confirmed several months later. This bacteria was moderately sen-

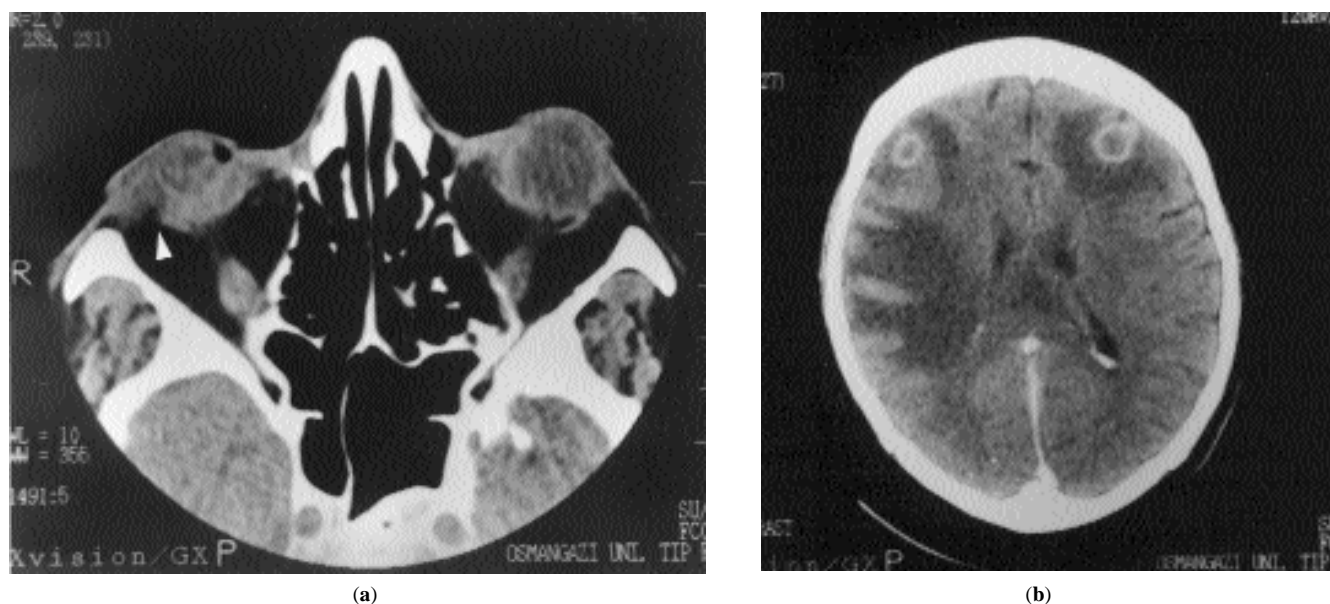


Fig. 1. (a) An orbital computed axial tomography showing increased heterogeneous density in the vitreous of the right eye and soft tissue intensity occupying the area between the zygomatic bone and bulbous oculi (arrow). (b) A cranial computed tomography showing brain abscesses in case 1.

sitive to TMP-SMX.

During therapy, a cranial computed tomography for resistant nausea revealed brain abscesses in the fronto-temporal regions (Fig. 1b). Forty days later the drug dose was tapered to 1600/320 mg per day and replaced with an oral schedule. However, vision in the patient's right eye was completely lost. Six months later, his cranial MRI was normal, and his ESR was 15 mm/h. TMP-SMX was maintained for a total of 8 months without the recurrence of symptoms.

Case 2

A 24 year-old man was admitted to our hospital on 1 January 1999 due to fever peaking at 40°C, cough, and hemoptysis. He had a history of BD, initially diagnosed in 1997 based on the clinical features of recurrent oral and genital aphthous ulcerations, pustular skin lesions and posterior uveitis. He had been taking methylprednisolone (4-64 mg/day), azathioprine (150 mg/day) and cyclosporine A (200 mg/day) for the management of flares of posterior uveitis for 2 years.

Upon examination, the patient's fever was 39.5°C. He also had Cushingoid. There were many suppurative nodules on various parts of his body. Crackles were audible over the lower half of the left lung. Laboratory findings were as follows: hemoglobin 10 gr/dl, WBC 7100 mm³, ESR 120 mm/h, CRP 21.4 mg/dl, and serum glucose level 106 mg/dl. His chest roentgenogram revealed diffuse non-homogenous opacity in the right parahilar area and a consolidation in the middle zone of the left lung (Fig. 2a). Gram positive filamentous organ-

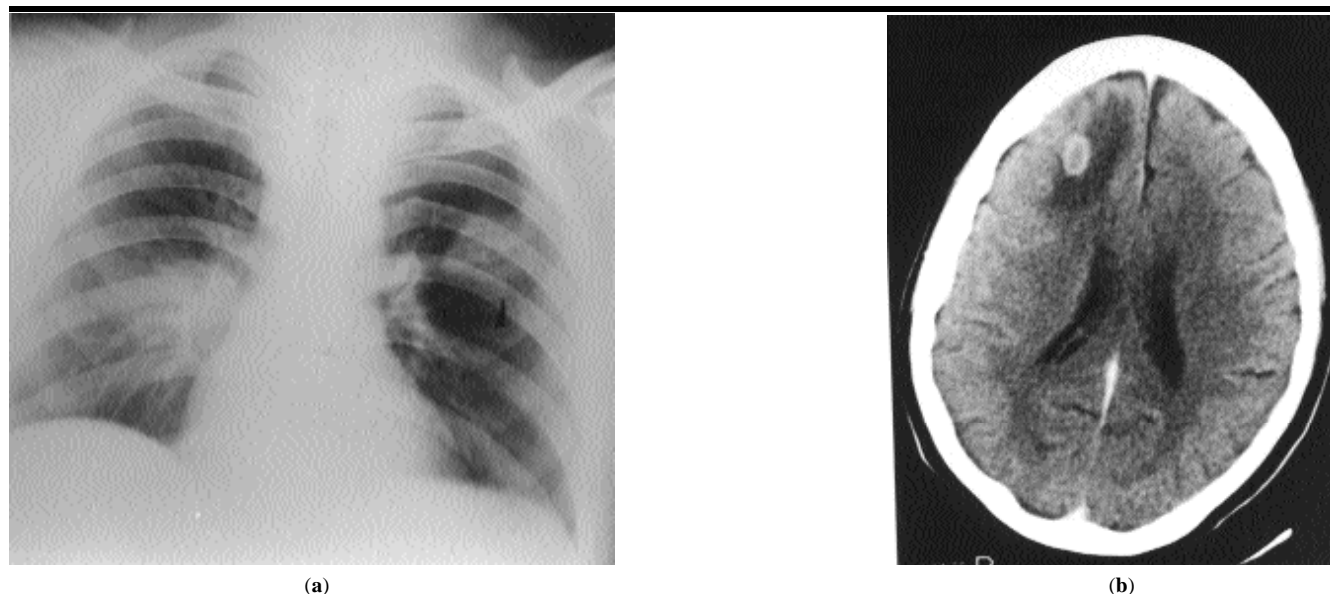


Fig. 2. (a) A chest roentgenogram showing non-homogenous opacity in the right parahilar area and a consolidation in the middle zone of the left lung in case 2. (b) A cranial computed tomography showing brain abscesses in case 2.

isms were found in the specimens obtained from skin abscesses and sputum. The abscess specimen culture was identified as *N. asteroides*, and he was started on intramuscular trimethoprim (6400 mg) and sulfamethoxazole (1280 mg) per day. A cranial computed tomography was performed for resistant nausea which revealed brain abscesses in the fronto-temporal regions (Fig. 2b). The lung and subcutaneous lesions regressed within one month. Two months later, the drug dose was tapered to 1600/320 mg per day and replaced with an oral schedule. Ten months later, the drug was discontinued. At that point, his cranial MRI was normal and his ESR was 20 mm/h. Cultures had been sent to the aforementioned centres, where *N. farcinica* was identified several months later, which was resistant to TMP-SMX. The patient has been symptom-free over the 18 months of the follow-up period, except for two uveitis attacks occurring after he was discharged.

Discussion

Nocardia spp. are comprised of a group of gram-positive, aerobic, and weakly acid-fast bacteria that form into branching filaments likely to fragment into rods or coccoid elements. *Nocardia spp.* organisms can enter the body either by inhalation or by a direct inoculation of the skin after trauma. The host's defense against nocardial infection depends on the integrity of neutrophil, monocyte, and lymphocyte functions (3,4). Impaired cell-mediated immunity caused by steroid and immunosuppressive therapy or acquired immunodeficiency syndrome (AIDS) is an important risk factor for nocardiosis. Other patients at risk of developing nocardiosis include those with lymphoreticular malignancies, dysgammaglobulinemia, chronic pulmonary disorders, and alcoholism (5,6). Although a reversed ratio of CD4+ to CD8+ T lymphocytes is not uncommon in BD (7), no data exists that opportunistic infections increase in patients with BD who have not ever been on an immunosuppressive therapy. The functions of the monocyte and polymorphonuclear leucocytes have been found to

be increased in BD (8,9). Therefore, there were no risk factors apart from immunosuppressive therapy to account for the opportunistic infections in our BD patients.

The diagnosis of nocardiosis can be difficult for several reasons. Firstly, there are no pathognomonic clinical and radiological features of nocardiosis. Secondly, *Nocardia spp.* are only infrequently cultured from the blood (10). Thirdly, the *in vitro* growth of *Nocardia spp.* is slow, usually taking almost a month (11). Finally, routine Gram smear may miss the organism, and samples may be prematurely discarded if the laboratory is not alerted. These problems often lead to a delayed diagnosis and may contribute to increased mortality and morbidity. All four of these possible reasons for delayed diagnosis and treatment may have contributed to the outcome in case 1. Moreover, the manifestations of nocardiosis may resemble those of BD, as in our patients. For instance, it is likely for *Nocardia spp.* to involve eye structures and to manifest as uveitis (12) or endophthalmitis (13). These similarities may lead to misinterpretations, as occurred in case 1. Such misinterpretations may be due partly to the preconception that every inflammatory eye event in BD is due to BD. There was a noticeable delay in the treatment of case 1, as the microbiologist in charge was not notified of *Nocardia spp.* and samples were discharged prematurely. Most probably due to this delay, this patient lost the vision in his right eye completely.

The lung is the most common site of nocardial involvement and accounts for 60-80% of cases (14). Nocardiosis then disseminates to the brain, soft tissues or other sites (15). Many authors emphasise that there are no pathognomonic radiologic features for pulmonary nocardiosis (16). Presentations include pulmonary nodules, abscesses or cavitations, consolidations, and empyema. Pulmonary artery aneurysm is a frequent diagnosis in BD with fever and hemoptysis along with parahilar opacities on chest roentgenogram (17). The risk of such a critical misinterpretation was present in case 2, who presented

with fever, hemoptysis and a parahilar opacity. In this particular case, maintaining the intense immunosuppressive therapy might have led to a fatal result. However, due to our awareness of this problem, gained from the previous case, the microbiologist was immediately notified of the possibility of nocardiosis. Accordingly, nocardiosis was diagnosed easily and its treatment was started without delay.

Cerebral involvement worsens the prognosis of nocardiosis. The overall fatality rate of nocardiosis is 70% in the case of brain abscess (18). We found brain abscesses in both the frontal and temporal regions of the brain. In addition to agitation in case 1, the common symptom of cerebral involvement in both cases was nausea. Fortunately, our patients responded quite well to TMP-SMX, despite the fact that *N. farcinica* was resistant to TMP-SMX in case 2.

In conclusion, in the case of a BD patient presenting with hemoptysis, fever and parahilar opacities or an inflammatory eye event while still under immunosuppressive therapy, we recommend that such opportunistic infections as nocardiosis be considered and an aggressive diagnostic approach be started.

References

1. YAZICI H, PAZARLI H, BARNES CG, *et al.*: A controlled trial of azathioprine in Behçet's syndrome. *N Engl J Med* 1990; 332: 281-5.
2. OZYAZGAN Y, YURDAKUL S, YAZICI H, *et al.*: Low dose cyclosporine A versus pulsed cyclophosphamide in Behçet's syndrome: A single masked trial. *Br J Ophthalmol* 1992; 76: 241-3.
3. BEAMAN BL, BEAMAN L: *Nocardia* species: Host-parasite relationships. *Clin Microbiol Rev* 1994; 7: 213-64.
4. FILICE DA, NIEWOEHNER DE: Contribution of neutrophils and cell-mediated immunity to control of *Nocardia asteroides* in murine lungs. *J Infect Dis* 1987; 156: 113-21.
5. KIM J, MINAMOTO GY, GRIECO MH: Nocardial infection as a complication of AIDS: Report of six cases and review. *Rev Infect Dis* 1991; 13: 624-629.
6. PEABODY JW, SEABURY JH: Actinomycosis and nocardiosis. *Am J Med* 1960; 28:99-115.
7. LEHNER T: Recent advances in cellular and humoral immunity in Behçet's syndrome. In INABA G (Ed.): *Behçet's Disease*, University of Tokyo Press, 1982; 357-68.
8. SAHIN S, LAWRENCE R, DİRESKENELİ H, HAMURYUDAN V, YAZICI H, AKOĞLU T: Monocyte activity in Behçet's disease. *Br J Rheumatol* 1996; 35: 424-9

9. MIZUSHIMA Y: Chemotaxis and phagocytosis of leukocytes in Behçet's disease. An overview. In LEHNER T and BARNES CG (Eds.): *Recent Advances in Behcet's Disease*. Royal Society of Medicine Services, London, 1986; 85-7.
10. KONTOTYANNIS DP, RUOFF K, HOOPER DE: Nocardia bacteremia. Report of 4 cases and review of the literature. *Medicine (Baltimore)* 1998; 77: 255-67.
11. GOODMAN JS, KOENIG MG: Nocardia infections in a general hospital. *Ann NY Acad Sci* 1970; 552-67.
12. LEELARASMEE A, VANICHAKARN S, ASWAPKEE P, NILVARANGKUR S, JAROONVESMA N: Disseminated nocardiosis after pulmonary collapse. *SE Asian JTrop Med Public Health* 1977; 8: 558-62.
13. KNOUSE MC, LORBER B: Early diagnosis of *Nocardia asteroides* endophthalmitis by retinal biopsy: Case report and review. *Rev Infect Dis* 1990; 12: 393-8.
14. FILICE GA: Nocardiosis. In SAROSI GA and DAVIES SF (Eds.): *Fungal Disease of the Lung*, 2nd ed. Raven Press 1993; 191-204.
15. WILSON JP, TURNER HR, KIRCHNER KA, CHAPMAN SW: Nocardial infections in renal transplant recipients. *Medicine* 1989; 65: 55-9.
16. FEIGIN DS: Nocardiosis of the lung: Chest radiographic findings in 21 cases. *Radiology* 1986; 159: 9-14.
17. HAMURYUDAN V, YURDAKUL S, MORAL F, et al.: Pulmonary arterial aneurysms in Behçet's syndrome: A report of 24 cases. *Br J Rheumatol* 1994; 33: 48-51.
18. HOEPRICH PD: Nocardiosis. In HOEPRICH PD, JORDAN MC, RONALD AR (Eds.): *Infectious Disease*. 5th ed. New York, J.B. Lippincott 1994; 485-93.