Severe CNS manifestations as the clinical hallmark in generalized Wegener's granulomatosis consistently negative for antineutrophil cytoplasmic antibodies (ANCA). A report of 3 cases and a review of the literature

E. Reinhold-Keller[1], K. de Groot[1], K. Holl-Ulrich[2], A.C. Arlt[3], M. Heller[4], A.C. Feller[2], W.L. Gross[1]

[1]Department of Rheumatology of the Medical University of Lübeck and Rheumaklinik Bad Bramstedt GmbH; [2]Department of Pathology, Medical University of Lübeck; [3]Department of Neurology, Rheumaklinik Bad Bramstedt GmbH; [4]Clinic for Radiology; University of Kiel, Germany.

Abstract

Objective

Antineutrophil cytoplasmic antibodies (ANCA) directed against proteinase 3 are highly specific for Wegener's granulomatosis (WG); their sensitivity for active generalized WG is nearly 100%. There are patients, however, who fulfill both the ACR 1990 criteria and the CHC 1992 definition for WG but who remain ANCA negative. The authors report 3 young patients with biopsy-proven active generalized WG who were consistently negative for ANCA over observation times ranging from 58 to 114 months.

Methods

ANCA titers were determined serially every 3 months. ANCA-negativity was defined by the absence of any fluorescence pattern on IFT plus the absence of any specific ELISA reactions. This included negative results for the antibody classes IgG, IgM and IgA. The sera of all patients were also tested in a capture PR3-ANCA ELISA. At 1- to 6-month intervals each patient underwent a standardized set of interdisciplinary examinations.

Results

Although CNS involvement in large WG cohorts is about 10%, severe CNS manifestations were the clinical hallmark in all 3 patients. One patient suffered from both intraspinal and intracerebral disease with fatal outcome; the other 2 had meningeal manifestations that responded favorably to immunosuppressive therapy.

Conclusion

Severe CNS manifestations could represent a clinical hallmark of patients with generalized Wegener's granulomatosis who are consistently negative for antineutrophil cytoplasmic antibodies (ANCA).

Key words

Wegener's granulomatosis, CNS manifestation, meningitis, antineutrophil cytoplasmic antibodies (ANCA).

Eva Reinhold-Keller, MD; Kirsten de Groot, MD; Wolfgang L. Gross, MD; Konstanze Holl-Ulrich, MD; Alfred C. Feller, MD; Andreas C. Arlt, MD; Martin Heller, MD.

Please address correspondence and reprint requests to: Eva Reinhold-Keller, MD, Poliklinik für Rheumatologie der Universität zu Lübeck, Rheumaklinik Bad Bramstedt GmbH, Oskar-Alexander-Straße 26, D-24576 Bad Bramstedt, Germany.
E-mail: RKeller@rheuma-zentrum.de

Received on January 8, 2001; accepted in revised form on April 11, 2001.

© Copyright CLINICAL AND EXPERIMENTAL RHEUMATOLOGY 2001.

Introduction

Antineutrophil cytoplasmic antibodies (ANCA) with a cytoplasmic fluorescence pattern in indirect immunofluorescence (IFT) directed against proteinase 3 (cANCA/PR3-ANCA) as proven by standardized enzyme-linked immunosorbant assays (ELISA) are highly specific (up to 90%) for Wegener's granulomatosis (WG). The sensitivity of cANCA for generalized active WG approaches 100% (1, 2). The strong association of WG with ANCA has led to its designation as "ANCA-associated vasculitis" (3). However, there are patients without ANCA whose clinical and pathological features meet both the 1992 Chapel Hill Consensus Conference (CHC) on the Nomenclature of Systemic Vasculitis (3) definition of WG and the American College of Rheumatology (ACR) 1990 classification criteria (4) for WG. We recently described a syndrome resembling WG with low surface expression of HLA class I molecules and fulfilling the ACR criteria and CHC definition for WG (5). Since the discovery of ANCA in the mid-1980s, 12 cases of active generalized WG without ANCA have been described in the English language literature (Table I). It is remarkable that 10 of these patients – 83% - had cerebral and/or meningeal involvement, whereas in larger WG cohorts CNS manifestations affect only about 10% of patients (15,16).

We report 3 young patients with biopsy-proven active generalized WG fulfilling the CHC definition and ACR criteria for WG who were consistently ANCA-negative over their whole course ranging from 4 to more than 8 years. All 3 patients had severe CNS involvement, with a fatal outcome in one.

Methods

ANCA testing

ANCA titers were determined serially every 3 months as described previously and in accordance with a standardized protocol of the European Community (1, 2). Over the whole observation period ranging from 48 to 102 months, 9 to 25 sera were tested from each of the 3 patients. "ANCA-negativity" was characterized by the absence of any fluorescence pattern (cytoplasmic, perinuclear, or any atypical pattern) on ethanol and formaldehyde-fixed granulocytes in IFT *plus* the absence of any specific ELISA reaction to the following granulocytic antigens: proteinase 3 (PR3), myeloperoxidase (MPO), bacterial permeability increasing protein (BPI), lactoferrin, cathepsin G, lysozyme, human leukocyte elastase (1,2, 17,18). This included negative results for the antibody classes IgG, IgM, and IgA. In addition, we also tested sera of all patients in a capture PR3-ANCA ELISA, a highly sensitive assay (19, 20).

Assessment of disease activity and extent

At 1- to 6-month intervals (depending on disease activity and severity), each patient underwent a standardized set of interdisciplinary clinical, serological, and immunological examinations, including an extended imaging procedure with magnet resonance imaging (MRI) scan of the head and high-resolution computerized tomography scan of the chest, for the presence of active disease by the same team of clinicians (internist, neurologist, ear, nose, and throat specialist, ophthalmologist, etc.), as described elsewhere (16). In addition, an extended procedure was performed to exclude other granulomatous diseases, infections (especially hepatitis B and C infections), HIV, immunodeficiency disorders and malignant diseases, as described elsewhere (21).

Histological examination

Biopsies were taken from the nasal or paranasal mucosa in all patients, from the skin in one patient, and from the leptomeningeal tissue in another patient (Table II). Histological findings in all biopsies were analyzed for the classic changes of WG: vasculitis (including granulomatous vasculitis), extravascular granulomas (including well-defined granuloma), microgranuloma (<1 mm diameter), and diffuse granulomatous inflammation with multinucleated giant cells (of the Langhans' type), and geographic necrosis (22). Hematoxylin-eosin (HE)-stained serial sections from each specimen were examined. All specimens were also stud-

Table I. Twelve cases of ANCA-negative generalized Wegener's granulomatosis reported in the literature.

Author, publication year	Gender/Age (yrs.)	Disease extent*	CNS manifestations (abnormal results)**	CNS diagnostic procedures
Weinberger *et al*., 1993 (6)	male / 62	EY; **CNS**; L; S; B	Seizures, left hemiparesis	EEG, Cranial CT, MRI Biopsies of dura, arachnoid, and cortex
Newman *et al*., 1995 (7)	male / 73	**CNS**	Headaches, cranial neuropathy	MRI, CSF, meningeal biopsy
Newman *et al*., 1995 (7)	female / 60	L; E; A; S; **CNS**; B	Headaches, cranial neuropathy	Cranial CT, MRI, biopsy of dura
Newman *et al*., 1995 (7)	male / 71	E; **CNS**	Seizures, confusion, weakness of left hand/leg	MRI, EEG, meningeal biopsy
Lima *et al*., 1995 (8)	female / 29	E; A; S; B;	None	
Provenzale *et al*., 1996 (9)	female / 43	E (subgl. stenosis); S; **CNS**	Headache, TIA	MRI
Provenzale *et al*., 1996 (9)	male / 35	E; L; **CNS**	Headache, cranial neuropathy	MRI
Mukae *et al*., 1996 (10)	male / 62	L; E; S; B	None	
Nordmark *et al*., 1997 (11)	female / 74	E; **CNS**; B	Vertigo, confusion, seizures	Cranial CT, autopsy
Tojo *et al*., 1998 (12)	female / 61	E; B; **CNS**; K; L	Headache, diplopia cranial neuropathy, convulsions	MRI, CSF, autopsy
Hermann *et al*., 1999 (13)	male / 45	E; **CNS**	Headache, cranial neuropathy partial loss of visus	MRI
Nusbaum *et al*., 1999 (14)	female / 42	E; L; **CNS**; B;	Headache, nausea, vomiting	MRI, CFS, leptomeningeal and dural biopsy

*E: upper respiratory tract, L: lung, EY: inflammatory eye involvement, A: rheumatic complaints, S: skin, **CNS**: central nervous system, B: constitutional symptoms.
**EEG: electroencephalogram. CT: computed tomography. MRI: magnet resonance imaging. CSF: cerebrospinal fluid.

ied using additional histochemical stains, including elastic tissue stains. Mycobacterial or fungal infections were excluded in all biopsies by Ziehl-Neelsen and periodic acid-Schiff staining. All biopsies were assessed independently by 2 pathologists experienced in vasculitides (KH-U; ACF).

Case reports *(for details see Table II)*

No. 1 (D.S., female)

At the age of 8 years the patient experienced her first occurrence of fever, polyarthritis, myalgia, nodular skin changes with an increase in acute phase parameters. These symptoms spontaneously regressed after 3 months, but were followed by chronic crusty-bloody rhinitis. In 1992 at the age of 16 years she had clinical fever > 39°, arthralgia, myalgia, cough, episcleritis, bloody rhinitis, weight loss, night sweats, nodular skin changes on both forearms and upper limbs. A skin-muscle biopsy of the right upper limb

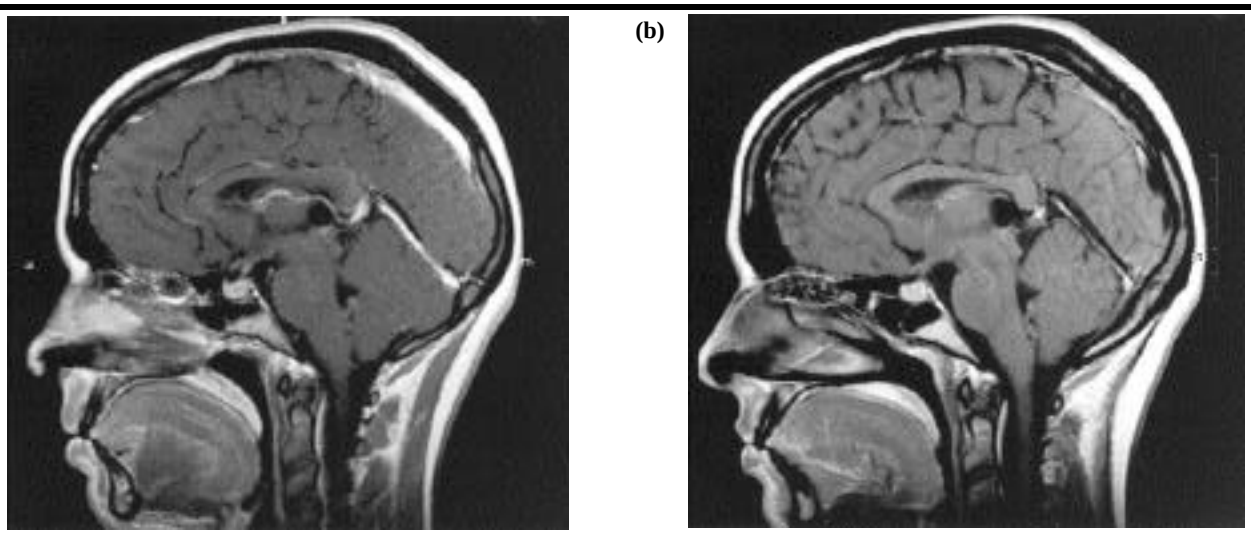

Fig. 1 (a) Mid-sagittal T1-weighted, contrast-enhanced MRI scan of the head in case no. 1 (10/1994). Marked contrast enhancement and pronounced meningeal thickening indicate inflammatory meningitis. **(b)** Follow-up examination 5 months later (3/1995) after treatment with cyclophosphamide and prednisone. A marked decrease in contrast enhancement and meningeal thickening can be seen.

Table II. Three patients with active generalized Wegener's granulomatosis without ANCA but with severe CNS manifestations.

	Case no. 1 (female)	Case no. 2 (female)	Case no. 3 (male)
Age at first symptoms attributable to WG	8 yrs.	29 yrs.	22 yrs.
Age at diagnosis (year of diagnosis)	16 (1992)	30 (1996)	25 (1992)
First symptoms attributable to WG*	A, S, B	E	E, EY, C, B
Organ involvement:			
at diagnosis	E, EY,A, S, B	E	E, EY, C, B
over the whole course*	E, EY, A, S, C,B	E, C, B	E, EY, C, B
Time between WG diagnosis and first CNS symptoms (months)	28	24	0
Clinical CNS manifestations	Headache	Headache, paraspastic progressive psycho-syndrome, hydrocephalus internus	Headache, visual acuity both eyes, tetraspasm, loss of bladder/sphincter control, transient ischemic attack (right-side central facial paresis, paresis of the right arm)
CNS diagnostic procedures/results			
MRI of the head	**1992**: mucosal thickening of all paranasal sinuses, CNS normal **8/93:** normal **10/94:** extensive enhancement of choroid plexus, ependyma in both ventricles, diffuse meningeal thickening (Fig. 1a) **6/95:** marked improvement (Fig. 1b)	**9/96:** mucosal thickening of all parasinus/nasal cavities, CNS normal **11/96:** unchanged, CNS normal **7/98:** extensive leptomeningeal nodular thickening basal cerebrum **12/98:** improved leptomeningeal infiltrates, but hydrocephalus internus **2/00:** further regress of leptomeningeal inflammation	**8/92:** disseminated perivascular white matter lesions; bilateral frontal, parietal, occipital opaque maxillary sinuses **11/92:** same as 8/92 **2/94:** increase in perivascular white matter lesions, enhancement tentorium **5/95:** same as 2/94 **11/95:** new pontine lesions **6/96:** idem **1/97:** multiple periventricular lesions, but not increased.
MRI of the spinal cord	not done	**12/96:** normal **1/99:** normal	**11/95:** inflammatory lesions gadolinium enhancement TH5/6 and TH9/10 (figure 3) **2/96:** decreased edema lesions idem, but without gadolinium enhancement
VEP	**10/94:** severe conduction slowing in optical pathway **3/95:** normal		**8/92:** no response potentials
EEG	**10/94:** normal	**11/96:** bi-frontotemporal focal disturbance	
Lumbar puncture	**4/93:** normal **10/94:** normal cells, proteins: 1.374 mg/l, albumin: 639 mg/l IgG: 314.4 mg/l, no oligoclonal bands **3/95:** normal **6/95:** normal **10/95:** normal	**2/97:** 7/3 cells; proteins: 223 mg/dl; IgG: 42.5mg/dl **8/98:** 240/3 cells proteins: 577 mg/dl, IgG: 315 mg/dl oligoclonal IgG bands + (serum -) **12/98:** proteins 2.6 g/l	**8/92:** 49/3 cells; proteins: 828mg/dl **8/92:** 280/3 cells; proteins: 930mg/dl; oligoclonal IgG bands + **6/93:** 35/3 cells; proteins: 332mg/dl. **2/94:** 29/3 cells; proteins: 260mg/dl **5/95:** 164/3 cells; proteins: 370mg/dl **6/96:** 44/3 cells; proteins: 340mg/dl. **1/97:** 43/3 cells; proteins: 247mg/dl
Leptomeningeal biopsy	**10/94:** see Fig. 2 a-b	not done	not done
Four vessel cerebral angiogram	not done	not done	**8/92:** normal
Extra/intracranial vascular US	not done	**11/96:** normal; 8/98: normal	**6/96:** normal

Biopsies and results*			
E	Unspecific eosinophilic rhinitis	Necrotizing granulomatous vasculitis, fibrinoid necrosis	Necrotizing ulceration, granulomatous vasculitis, non-caseating granuloma
S	Vasculitis, fibrinoid necrosis, non-caseating epithelioid formations, poorly defined granuloma		
C	(see Fig. 2)		
Observation period (months)**	114	54	58
Number of ANCA tests	25	9	18
Outcome	complete remission	partial remission	Death

*E: upper respiratory tract; EY: inflammatory eye involvement; A: rheumatic complaints; S: skin; C: central nervous system; B: constitutional symptoms. **From diagnosis until the end of follow-up (death or June 30th, 2000).

Fig. 2 (A) Temporoparietal meningeal biopsy in case no. 1. Low-power view showing several small vessels with dense perivascular infiltrates in the center, ill-defined inflammatory infiltrates with numerous foam cells on the left, and an area of fibrosis on the right (HE stain, x 40). **(B)** High-power view of same location as in (a) (case no. 1). In the center, an arteriole with inflammatory infiltration of the vessel wall can be seen. In addition to neutrophils and lymphocytes, some histiocytic cells and epithelioid cells are visible. The surrounding tissue shows dense inflammatory infiltrates consisting predominantly of foam cells with some epithelioid cells and plasma cells (HE stain, x 630).

revealed a leukocytoclastic vasculitis of the small arteries with focal fibrinoid vessel wall necrosis, infiltrates of lymphocytes, neutrophils, eosinophils and monocytes with partial epithelioid cell transformation and sparse poorly-defined granulomas. Serological findings: ESR 71 mm/1st hr, C-reactive protein 5.8 mg/dl; Immunological findings: negative readings for ANCA, ANA, anti-dsDNA, anticardiolipin antibody.

A diagnosis of WG was made based on the ACR criteria for WG and confirmed by the histology. Treatment with prednisone (Prd) and methotrexate (MTX) 15 mg/week intravenously led to only transient recovery. Despite an increase in the MTX dose, relapse with skin vasculitis, episcleritis and rheumatic complaints occurred in 10/94 together with the first onset of headache. A cranial MRI scan after administration of gadolinium revealed extensive enhancement of the choroid plexus, ependyma in both ventricles, and meningeal thickening temporoparietally on the right and temporobasally on the left (Fig. 1a) Two MRIs of the head one and three years earlier, by contrast, had revealed normal findings for the cerebrum. Leptomeningeal biopsy (right temporoparietal) showed an extensive area of well-defined inflammatory infiltrates with numerous foam cells in addition to lymphocytes, plasma cells, and some neutrophils (Fig. 2a, b). Several arterioles were visible within the dense inflammatory infiltrates, with vasculitic vessel wall infiltrations consisting of neutrophils and lymphocytes as well as histiocytic cells, some transformed to epithelioid cells. On the periphery of the inflammatory changes there was an area of dense fibrosis. Under medication with daily cyclophosphamide (CYC) combined with Prd, a cranial MRI scan in 6/95 revealed a marked improvement (Fig. 1b) and normalisation of the cerebrospinal fluid (CSF). Since 10/95 the patient has been in complete remission without any medication.

No. 2 (K.B., female)

Beginning at age 29, clinically the young woman suffered from crusty, bloody rhinitis, and a blocked nose. One year later, in 1996, nasal biopsy revealed necrotizing granulomatous

vasculitis with giant cells of the Langhans' type. Some small arteries and venules were infiltrated by neutrophils with fibrinoid necrosis. Serologically the acute phase parameters were elevated, but ANCA was negative. MRIs of the head in 9/96 and 11/96 revealed mucosal thickening in all the parasinus and nasal cavities, but no abnormalities in the cerebrum. The neurological examination was normal, EEG, however, showed a focal disturbance bi-frontotemporal.

The diagnosis of WG was based on the ACR criteria and CHC definition with exclusive involvement of the ENT tract as proved by a nasal biopsy. In another hospital, therapy with Prd was started with temporary success. In 7/98 B-symptoms occurred combined with increased acute phase reactants. In addition, the patient exhibited progressive psychosyndrome (personality changes, impaired memory, psychomotor superactivity, perseveration, acoustic and optical hallucinations), a paraspastic gait, and bulbar dysarthria. Renewed MRI (Table II) in 7/98 revealed an extensive leptomeningeal nodular thickening in the basal cerebrum, but no inflammatory signs in the sinus. The CSF analysis showed an increase in cells and proteins (Table II). Therapy with high doses of Prd (250 mg/d) plus azathioprine (2.5 mg/kg/d) led to amelioration of the neurological symptoms. In 12/98 signs of increased intracranial pressure (emesis) were observed, with progressive gait ataxia. MRI now disclosed signs of hydrocephalus internus whereas the extensive enhancement of the leptomeningeal infiltrations decreased. Despite intensive immunosuppression with Prd plus CYC 2 mg/kg/d the hydrocephalus increased. A dual-switch valve was implanted in 2/99. During a further course with continuation of CYC plus Prd all neurological signs improved. The CYC was discontinued and treatment switched to low-dose MTX in 3/00; the Prd dosage of 5 mg/d was tapered.

No. 3 (N.S., male)

In 1989, at age 22, the patient first experienced crusty, bloody rhinitis and a blocked nose. Beginning in 1992 he suffered from increasing fatigue and night sweats. In 8/92 his visual acuity deteriorated within a couple of days in the right eye, some days later also in the left eye, combined with severe frontal headaches. Lumbar puncture showed inflammatory signs; visual evoked potentials (VEP) elicited no response potentials; and a cranial MRI scan disclosed disseminated perivascular white matter lesions and bilateral opaque maxillary sinuses. Amaurosis of the right eye, visual acuity of 0.1 for the left. No congestion of the optic pit on either side. Ear, nose, throat examination: extensive crusts in both nasal cavities, histological examination of the biopsy revealed necrotizing ulceration, granulomatous vasculitis and non-caseating granuloma. Apart from an ESR of 29 mm/h, repeated tests found no serological or immunological abnormalities, including no ANCA. The diagnosis of WG with CNS and ENT involvement as proved histologically was made in 10/92. Under medication with daily CYC and Prd until 2/94 visual acuity improved to 0.3 in the left eye, the right eye remained amaurotic. Between 9/94 and 11/95 the patient refused any medication.

Beginning in 5/95 increasing vertigo and progressive tetraspasm, 11/95 loss of bladder and bowel sphincter control. At this time MRI scan revealed spinal lesions, affecting TH5/6 and TH9/10 (Fig. 3). No abnormalities were detected in any other organ systems. Resumption of CYC plus Prd and additional irradiation of the thoracic myelon with 40 Gy did not result in significant improvement. In 6/96 the patient suffered a transitory ischemic attack with right-side central facial paresis and paresis of the right arm. Under continuation of CYC plus Prd development of extended decubital ulcers. The patient died in 5/97 due to septicemia.



Fig. 3. MRI of the spinal cord in case no. 3 (11/95). Abnormal hyperintense signals of the spinal cord in the middle of the thoracic cord (T 5/6) after administration of gadolinium in the T1-weighted scan are consistent with extensive inflammatory myelitis.

Discussion

We report 3 young patients (mean age at diagnosis WG < 30 years) with biopsy-proven active generalized WG who were consistently negative for ANCA over observation periods of at least 5 years, in one patient exceeding 9 years. The clinical hallmark in these patients was severe CNS involvement, with a lethal outcome in one patient. Although the sensitivity for cANCA/PR3-ANCA approaches 100% in acute generalized stage WG, the English language literature published since the mid-1980s describes 12 patients with generalized ANCA negative WG (6-14) (Table I). It is remarkable that 10 of these patients

Table III. Cases of Wegener's granulomatosis with meningeal involvement reported in the literature (n = 32).

Author; yr. published (ref.)	Gender/age (yrs.)	ANCA findings*	CNS manifestations	CNS diagnostic procedures (abnormal results)**
Scully *et al.*; 1988 (24)	male / 72	not done	Loss of hearing, vertigo, headache, cranial neuropathy	MRI, CSF, auditory evoked potentials both ears, meningeal biopsy
Weinberger *et al.*; 1993 (6)	male / 62	negative	Seizures, left hemiparesis	EEG, cranial CT, MRI, biopsies of dura, arachnoid, and cortex
Tishler *et al.*; 1993 (25)	male / 41	cANCA 1:80 PR3 n.i.	Headaches, blurry vision left, infero-nasal field cut left, Generalized tonic-clonic seizures	CT, MRI, fundoscopia, biopsy (dura)
Nishino *et al.*; 1993 (26)	male / 40	positive Type and PR3 unknown	Cranial neuropathy, headache	MRI, meningeal biopsy
Newman *et al.*; 1995 (7)	male / 73	negative	Headaches, cranial neuropathy	MRI, CSF, meningeal biopsy
Newman *et al.*; 1995 (7)	female / 60	negative	Cranial neuropathy, headaches	Cranial CT, MRI, biopsy of dura
Newman *et al.*; 1995 (7)	male / 71	negative	Seizures, confusion, weakness of left hand/leg	MRI, EEG, meningeal biopsy
Newman *et al.*; 1995 (7)	male / 40	cANCA+	Diplopia, multiple cranial neuropathy	MRI, biopsy of dura
Provenzale *et al.*; 1996 (9)	male / 41	cANCA 1:160, PR3 unknown	Headache, diplopia, optic neuritis	MRI
Provenzale *et al.*; 1996 (9)	female / 43	negative	Headache, TIA	MRI
Provenzale *et al.*; 1996 (9)	male / 35	negative	Headache, cranial neuropathy	MRI
Jinnah *et al.*; 1997 (27)	male / 41	cANCA 1:1,280 PR3 n.i.	Horizontal diplopia, papilledema, headache, nausea, vomiting, cranial neuropathy VI,VII	MRI, CFS, biopsy (leptomeningeal)
Tojo *et al.*; 1998 (12)	female / 61	negative	Headache, diplopia, cranial neuropathy, convulsions	MRI, CSF, autopsy
Katrib *et al.*; 1998 (28)	male / 57	cANCA 1: 640 PR3 +	Headache, mild hyperreflexia right	MRI, biopsies of dura and arachnoid
Scarrow *et al*; 1998 (29)	male / 53	cANCA + PR3 unknown	Cranial neuropathy, headache	MRI, meningeal biopsy, CFS
Garcia-A. *et al.*; 1998 (30)	male / 32	cANCA + PR3 +	Headache, double vision, amaurosis left, multiple cranial neuropathy	Cranial CT, MRI, visual evoked potentials
Burrell *et al.*; 1998 (31)	female / 37	weakly positive (type unknown)	Headache, double vision, vomiting, cranial neuropathy	MRI
Kelly *et al.*; 1998 (32)	female / 58	pANCA, MPO +	Spastic paraparesis	Thoracic MRI, biopsy (thoracic dura and cord)
Nusbaum *et al.*; 1999 (14)	female / 42	negative	Headache, nausea, vomiting	MRI, CFS, leptomeningeal and dural biopsy
Murphy *et al.*; 1999 (33)	11 patients	n.i.	Headache	MRI in all pts., in 6 pts unrelated, and in 5 pts. adjacent to sinus or orbit, meningeal biopsies in 4 pts.
Scully *et al.* ; 1999 (34)	female / 75	pANCA MPO +	Headache, dizziness, tendency to fall, desorientation	MRI, meningeal biopsy
Hermann *et al.*; 1999 (13)	male / 45	negative	Headache, cranial neuropathy, partial loss of visus	MRI

*ANCA: antineutrophil cytoplasmic antibodies; cANCA: cytoplasmic fluorescence pattern; pANCA: perinuclear fluorescence pattern; PR3: proteinase 3; MPO: myeloperoxidase.
**EEG: electroencephalogram; CT: computed tomography; MRI: magnet resonance imaging; CSF: cerebrospinal fluid.

(83%) had cerebral and/or meningeal involvement, whereas studies of large WG cohorts have reported only 10% of patients with CNS involvement (15, 16). In our own cohort 13 of 425 WG patients had active generalized WG that was consistently ANCA negative. Seven of these 13 patients (including the 3 patients described here) had CNS involvement (54%). Furthermore, the median age of our 13 patients with generalized WG without ANCA was 35 years at diagnosis compared to the mid-forties or older in patients with "classical" generalized WG.

All 3 patients fulfilled the 1990 ACR criteria and the 1992 CHC definition for WG supported by histological findings. Granulomatous vasculitis or extravascular granuloma were seen in all 3 patients together with the complete pathological triad of WG with geographic necrosis, vasculitis, and granuloma in repeated biopsies. Other granulomatous diseases, infections, malignant diseases or immunodeficiency disorders, including defects in the expression of MHC I, were excluded (5, 21). We have seen patients with a WG-like syndrome involving a defect in the expression of MHC I accompanying the clinical and histological picture of WG. They also had CNS involvement and were negative for ANCA. However, unlike cases of "classic" WG, immunosuppressive therapy failed in these cases (5).

Two of our 3 patients had extensive meningeal involvement. In case no. 1 extensive meningeal involvement was noted 2 years after the diagnosis of WG. At that time, the young woman only complained of headache and a clinical neurological examination was inconspicuous, but VEP testing revealed severe conduction slowing of the optical pathway. MRI of the head disclosed extensive meningeal involvement (Fig. 1 a, b) and no inflammation in the sinus (23), whereas MRI scans one and two years earlier had shown no CNS changes. A leptomeningeal biopsy excluded other causes (Fig. 2). The patient responded well to daily CYC combined with Prd (Fig. 1a, b). The other young woman with meningeal involvement (case no. 2) experienced serious neurological and psychiatric symptoms with progressive signs of hydrocephalus internus requiring surgery.

Meningeal involvement is uncommon in WG; we could find only 32 such cases in the literature (Table III) (6, 7, 9, 13, 24-34). It is remarkable that 9 out of the 20 patients (45%) with meningeal involvement and known ANCA results were ANCA negative. It is surprising that 10 of the reported 12 patients (83%) with generalized, invariably ANCA-negative WG had cerebral and/or meningeal involvement (Table I). Our cohort of more than 400 patients with generalized WG included no patients with meningeal involvement other than the 2 ANCA-negative patients described here. In the majority of cases with meningeal involvement, headache was the main clinical sign. CSF findings were inconsistent (Table III). Both of our cases had elevated protein levels, but case no. 1 had a normal cell count whereas case no. 2 exhibited a lymphocytic pleocytosis.

Neuroimaging procedures, especially MRI with gadolinium, appear to be the most sensitive, but not highly specific, methods for detecting meningeal involvement, e.g. thickening and enhancement of gadolinium (33). Other possible causes of these findings (e.g. neurosarcoidosis, infections, hypertrophic pachymeningitis, malignancies) should be excluded.

In our case no. 3 multifocal neurologic abnormalities were the first signs of WG, with development of a tetraparesis caused by inflammation of the thoracic cord during further course leading to a fatal outcome despite treatment with daily CYC plus Prd combined with irradiation of the spinal cord. Spinal cord involvement in WG is rare. Nishino *et al*. (35) described one case with symptoms of obstruction of the thoracic cord caused by biopsy-proven vasculitic inflammation of the dural tissue. Kelly *et al*. (32) reported a WG patient with MPO-ANCA with gradually progressive spastic paraparesis secondary to biopsy-proven thoracic cord compression caused by dural granuloma from TH2 to TH8.

Since the mid-1980s, examination by a neurologist combined with an MRI scan of the head have been part of our regular interdisciplinary assessment of disease extent and activity in WG patients (16, 36). The clinical signs of CNS involvement can arise at any time during the course of WG; as a first clinical sign (case no. 3), or later in course as in cases no. 1 and 2. The clinical signs of CNS involvement can be mild (case no. 1). In our patients, CNS involvement was confirmed (after exclusion of other causes) based on the clinical picture, extensive neurological examination, including CSF and MRI of the head and/or spinal cord, and by leptomeningeal biopsy in one patient (case no. 1).

In summary, despite the high sensitivity of PR3-ANCA/cANCA in active generalized WG (nearly 100%), some patients with active generalized WG fulfilling the ACR criteria and CHC definition for WG remain consistently ANCA negative and have serious CNS involvement as the clinical hallmark. This observation accords with the literature showing an 83% rate of CNS involvement in WG patients who are consistently ANCA-negative versus only 10% in large cohorts with "classic" WG. Conversely, WG patients with meningeal involvement have a high rate of ANCA negativity (45%). Further studies, including extensive immunological investigations beyond ANCA testing, are needed to distinguish this "seronegative WG" subset with predominant CNS involvement from "classic" PR3-ANCA-positive WG.

References

1. NÖLLE B, SPECKS U, LÜDEMANN J, ROHRBACH MS, DEREMEE RA, GROSS WL: Anticytoplasmic autoantibodies: Their immunodiagnostic value in Wegener's granulomatosis. *Ann Intern Med* 1989; 111: 28-40.
2. HAGEN EC,ANDRASSY K, BAJEMA I, *et al*.: The diagnostic value of standardized assays for antineutrophil cytoplasmic antibodies (ANCA) in systemic vasculitis. Results of an international collaborative study. *Kidney Int* 1998; 53: 743-53.
3. JENNETTE JC, FALK RJ, ANDRASSY K, *et al.*: Nomenclature of systemic vasculitides: proposal of an International Consensus Conference. *Arthritis Rheum* 1994; 37: 187-92.
4. LEAVITT RY, FAUCI AS, BLOCH DA, *et al*.: The American College of Rheumatology 1990 criteria for the classification of Wegen-

er's granulomatosis. *Arthritis Rheum* 1990; 33: 1101-7.
5. MOINS-TEISSERENC HT, GADOLA SD, CELLA M, *et al*.: Association of a syndrome resembling Wegener's granulomatosis with low surface expression of HLA class-I molecules. *The Lancet* 1999; 354; 1598-603.
6. WEINBERGER LM, COHEN ML, REMLER BF, NAHEEDY MH, LEIGH RJ: Intracranial Wegener's granulomatosis. *Neurology* 1993; 43: 1831-4.
7. NEWMAN NJ, SLAMOVITS TL,FRIEDLAND S, WILSON WB: Neuro-ophthalmic manifestations of meningocerebral inflammation from the limited form of Wegener's granulomatosis. *Am J Ophthalmology* 1995; 120: 613-21.
8. LIMA F, BUCHANAN N, FROES L,KERSLAKE S, KHAMASHTA MA,HUGHES GRV: Pregnancy in granulomatosis vasculitis. *Ann Rheum Dis* 1995; 54: 604-6.
9. PROVENZALE JM, ALLEN NB: Wegener granulomatosis: CT and MR findings. *Am J Neuroradiol* 1996; 17: 785-92.
10. MUKAE H, MATSUMOTO N, ASHITANI J, *et al*.: Neutrophil-related cytokines and neutrophil products in bronchoalveolar lavage fluid of a patient with ANCA negative Wegener's granulomatosis. *Eur Respir J* 1996;9:1950-4.
11. NORDMARK, BOQUIST L, RÖNNBLOM L: Limited Wegener's granulomatosis with central nervous system involvement and fatal outcome. *J Intern Med* 1997; 242: 433-6.
12. TOJO J, NISHIMAKAI T, OHYANAGI H, *et al*.: An autopsy case of Wegener's granulomatosis with Pachymeningitis. *Internal Medicine* 1998; 37: 711-5.
13. HERMANN M,BOBEK-BILLEWICZ B, BULLO B, HERMANN A, RUTKOWSKI B: Wegener's granulomatosis with unusual cavernous sinus and sella turciva extension. *European Radiology* 1999; 9: 1859-61.
14. NUSBAUM AO, MORGELLO S, ATLAS SW: Pial involvement in Wegener's granulomatosis shown on MRI. *Neuroradiology* 1999; 41: 847-9.
15. HOFFMAN GS, KERR GS, LEAVITT RY, FAUCI AS: Wegener granulomatosis: An analysis of 158 patients. *Ann Intern Med* 1992; 116:488-98.
16. REINHOLD-KELLER E, BEUGE N, LATZA U, *et al*.: Interdisciplinary approach to the care of patients with Wegener's granulomatosis. *Arthritis Rheum* 2000; 43: 1021-32.
17. HAUSCHILD S, SCHMITT WH, CSERNOK, E, FLESCH BK, RAUTMANN A, GROSS WL: ANCA in systemic vasculitides, collagen vascular diseases, rheumatic disorders and inflammatory bowel diseases. ANCA associated vasculitides. *In* GROSS WL (Ed.): *Advances in Experimental Medicine and Biology*, 1993; 336: 245-51.
18. SCHULZ H, CSERNOK E, JOHNSTON TW, LOCKWOOD CM, GROSS WL: Use of native and recombinant bactericidal/permeability-increasing protein (BPI) as antigens for detection of BPI-ANCA. *J Immunol Methods* 1997; 205: 127-33.
19. BASLUND B, SEGELMARK M,WIIK A,SZPIRT W, PETERSEN J, WIESLANGER J: Screening for ANCA: is indirect immunofluorescence the method of choice? *Clin Exp Imm* 1995; 99: 486-92.
20. SELGA D, SEGELMARK M, WESTMAN K, *et al*.: Clinical evaluation of a capture ELISA for PR3-ANCA. *Sarcoidosis* 1996; 13: 276.
21. GROSS WL, SCHNABEL A, TRABANDT A: New perspectives in pulmonary angiitis. From pulmonary angiitis and granulomatosis to ANCA associated vasculitis. *Sarcoidosis* 2000; 17: 33-52.
22. DEVANEY KO, TRAVIS WD, HOFFMAN G, LEAVITT R,LEVOVICS R, FAUCI AS: Interpretation of head and neck biopsies in Wegener's granulomatosis. A pathologic study of 126 biopsies in 70 patients. *Am J Surg Pathol* 1990; 14: 555-64.
23. DRACHMANDD: Neurological complications of Wegener's granulomatosis. *Arch Neurol* 1963; 8: 145-155.
24. SCULLY RE, MARK EJ, MCNEELY WF, MCNEELY BU: Case records of the Massachusetts general hospital. Weekly clinicopathological exercises. *N Engl J Med* 1988; 318: 760-8.
25. TISHLER S, WILLIAMSON T, MIRRA SS, LICHTMAN JB, GISMONDI P, KIBBLE MB: Wegener granulomatosis with meningeal involvement. *AJNR* 1993; 14: 1248-52.
26. NISHINO H, RUBINO FA, PARISI E: The spectrum of neurologic involvement in Wegener's granulomatosis. *Neurology* 1993; 43:1334-7.
27. JINNAH HA, DIXON A, BRAT DJ, HELLMANN DB: Chronic meningitis with cranial neuropathies in Wegener's granulomatosis. *Arthritis Rheum* 1997; 40: 573-7.
28. KATRIB A, PORTEK I, CORBETT AJ, HERSCH MI, ZAGAMI AS: Meningeal involvement in Wegener's granulomatosis. *J Rheumatol* 1998; 25: 1009-11.
29. SCARROW AM, SEGAL R, MEDSGER TA JR, WASKO MC: Communicating hydrocephalus secondary to diffuse meningeal spread of Wegener's granulomatosis: Case report and literature review. *Neurosurgery* 1998; 6: 1470-3.
30. GARCIA-ASENSIO S, BARRENA R, GUELBUENZU S, VELILLA J, MARTINEZ R: Granulomatosis de Wegener con afectatcion meningea: Correlacion clinicorradiologica. *Rev Neurol* 1998; 27: 833-6.
31. BURRELL HC, MCCONACHIE NS: Pachymeningitis in Wegener's granulomatosis. *Australasian Radiology* 1998; 42: 364-6.
32. KELLY PJ, TOKER DE,BOYER P, MCDONALD CT, NILES J: Granulomatous compressive thoracic myelopathy as the initial manifestation of Wegener's granulomatosis. *Neurology* 1998; 51: 1769-70.
33. MURPHY JM, GOMEZ-ANSON B, GILLAR JH, *et al*.: Wegener granulomatosis:MR imaging findings in brain and meninges. Radiology 1999; 213: 794-9.
34. SCULLY RE, MARK EJ, MCNEELY WF, EBELING SH: Case records of the Massachusetts General Hospital. Case 9-99. *N Engl J Med* 1999; 340: 945-53.
35. NISHINO H, RUBINO FA, DEREMEE RA, SWANSON JW, PARISI JE: Neurological involvement in Wegener's granulomatosis: an analysis of 324 consecutive patients at the Mayo Clinic. *Ann Neurol* 1993; 33: 4-9.
36. DE GROOT K,SCHMIDT DK,ARLT AC,GROSS WL, REINHOLD-KELLER E: Standardized neurological follow-up as part of the interdisciplinary approach to the care of 128 patients with Wegener's granulomatosis. *Arch Neurol* 2001; 58: 1215-21.