Clinical vignette

Subcutaneous calcification on the nose in a patient with scleroderma

A 62-year-old woman with long-standing limited scleroderma presented to the outpatient rheumatology clinic because of pain and discomfort of the nose. On physical examination a firm subcutaneous nodule was observed over the ridge of the nose **(A)**. No other such nodule-like lesions were observed. The nature of this nodule was disclosed by plain radiographs, which clearly demonstrated a subcutaneous calcification **(B)**. Subcutaneous calcifications occur in about 40% of patients with limited scleroderma. The most characteristic locations include the fingers of the hands, the pre-olecranon and olecranon areas, the prepatellar bursae and the anterior compartment of the lower extremities.

Our patient has not developed similar calcifications in other areas, which are frequently affected in scleroderma patients. Thus the present location, as a first manifestation on the ridge of the nose, is extremely unusual.

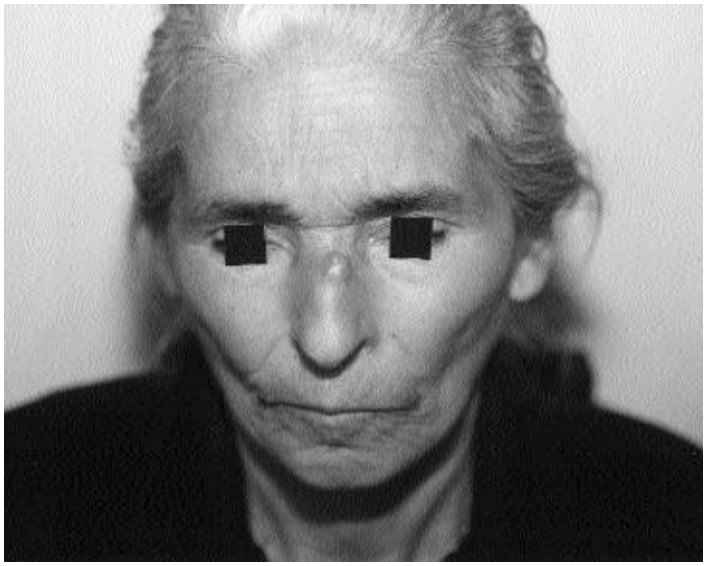

(A)

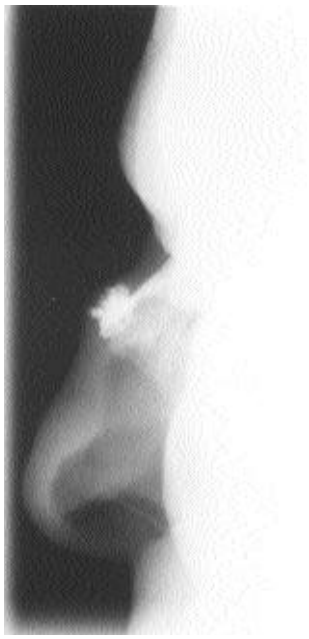

(B)

T.I. TEMEKONIDIS, *MD, Fellow in Rheumatology*
A.A. DROSOS, *MD, FACR, Professor of Medicine/ Rheumatology*

Department of Internal Medicine, Medical School, University of Ioannina, Ioannina, Greece

Please address correspondence and reprint requests to: Alexandros A. Drosos, MD, FACR, Professor of Medicine/Rheumatology, Department of Internal Medicine, Medical School, University of Ioannina, 45110, Ioannina, Greece. E-mail: adrosos@cc.uoi.gr