Clinical and Experimental Rheumatology 2001; 19: 565-568.

Calcification of the internal elastic membrane in temporal arteries: Its relation to age and gender

C. Nordborg[1], E. Nordborg[2], V. Petursdottir[3], I.-M. Fyhr[1]

[1]Department of Pathology and [2]Department of Rheumatology, Sahlgrenska University Hospital, Göteborg, Sweden; [3]Department of Pathology, University of Iceland, Reykjavik, Iceland

Claes Nordborg, MD, PhD; Elisabeth Nordborg, MD, PhD; Vigdis Petursdottir, MD, PhD; Ing-Marie Fyhr, MD, PhD.

This study was supported by grants from the Göteborg Medical Society, the Swedish Heart-Lung Foundation, the Swedish Rheumatism Association, Rune och Ulla Amlöfs Stiftelse and Syskonen Holmströms Donationsfond.

Please address correspondence and reprint requests to: Claes Nordborg, Department of Pathology, Sahlgrenska University Hospital, SE-413 45 Göteborg, Sweden. E-mail: claes.nordborg@path.gu.se

Received on October 13, 2000; accepted in revised form on February 28, 2001.

© Copyright CLINICAL AND EXPERIMENTAL RHEUMATOLOGY 2001.

Key words: Giant cell arteritis, temporal artery, calcification, elastin.

ABSTRACT

Objective

To investigate the age and sex distribution of calcifications of the internal elastic membrane (IEM) in temporal arteries.

Methods

Calcifications of the IEM were assessed light-microscopically in temporal arteries from 40 women and 21 men, aged 51 or more, who were known not to have giant cell arteritis (GCA). Their relation to age and the difference between women and men were tested statistically.

Results

The IEM calcifications differed morphologically from the calcifications in Mönckeberg's mediosclerosis and atherosclerosis. They increased significantly with age and were 2.62 times more common in women than men.

Conclusion

Previous morphological studies indicate that the inflammatory process in GCA is initiated by a foreign-body, giant-cell attack on calcifications of the IEM. The present study showed that IEM calcifications in non-GCA controls show an age and sex distribution similar to that of GCA morbidity. The results may indicate that the presence of IEM calcifications in the general population influences the age and sex distribution of GCA. Furthermore, the findings support the hypothesis that the calcifications, although not disease specific, may play a pathogenetic role in the latter.

Introduction

Giant cell arteritis (GCA) is a chronic inflammatory disorder of the medium-sized and large arteries (1, 2). Morphological studies indicate that the inflammatory process is initiated by a foreign-body, giant-cell reaction directed at calcified parts of the arterial internal elastic membrane (IEM) (3, 4). Although larger in the inflamed arteries, IEM calcifications are also found in non-GCA controls (3,5). Focal calcification of the IEM could therefore not be the only inducing factor but should instead be regarded as one of several pathogenetic factors and a prerequisite for the development of GCA.

GCA is a disease of elderly people and there is a clear predominance among women (for references, see 6). The reason for its occurrence with regard to age and gender remains to be clarified. The object of the present study was to investigate whether, in the general population, focal calcification of the IEM in temporal arteries relates to sex and age in a similar way.

Material and methods

Temporal artery specimens were collected during autopsy from 34 cases known not to have GCA, whereas the other specimens derived from 27 cases which, after temporal artery biopsy, proved not to have GCA. Specimens were thus collected from 61 patients (40 women; 21 men). The age of the women was 72.65 ± 9.56 years (range: 51-93) and that of the men was 72.91 ± 8.84 (range: 54-90) (± SD). Four of the patients were known to have diabetes mellitus, eight patients had arterial hypertension and one further patient had both disorders (Table I).

In 36 of the cases, part of the temporal artery tissue was fixed in formaldehyde and embedded in paraffin wax, whereas part of it was fixed in 4% glutaraldehyde in Millonig's buffer and embedded in Epon 812. In 19 other cases, the entire specimen was embedded in paraffin wax and in 6 cases the entire material was embedded in Epon 812. One m thick plastic sections were stained according to Richardson and 5 m thick paraffin sections were stained with eosin and haematoxylin or according to van Gieson. The calcifications in paraffin sections were confirmed with the van Kossa staining.

Arterial cross-sections were screened in a light microscope for IEM calcifications. Specimens from biopsies and autopsies were included in the same study as postmortem changes do not influence the detection of calcifications. Likewise, both plastic and paraffin sections were included in the study; the screening for calcification is not influenced by the embedding or staining procedures.

The number of temporal artery cross-sections per case depended on the length of the specimen. The average

Table I. Patient data. Number of calcified arteries in patients with diabetes mellitus and/or hypertension within brackets. (± SD).

	Age	Age of calcified		Age of non-calcified	Percent calcified	Diabetes mellitus	Hyper-tension
Women (n = 40)	72.65 ± 9.56	77.10 ± 8.15	(p = 0.0056)	68.20 ± 8.92	50 (p = 0.0187)	3 (1)	7 (2)
Men (n = 21)	72.91 ± 8.84	78.80 ± 9.20	(p = 0.0199)	71.28 ± 8.15	19	2 (0)	2 (0)
Total (n = 61)	72.74 ± 9.25	77.96 ± 7.94	(p = 0.0006)	69.24 ± 8.41	39	5	9

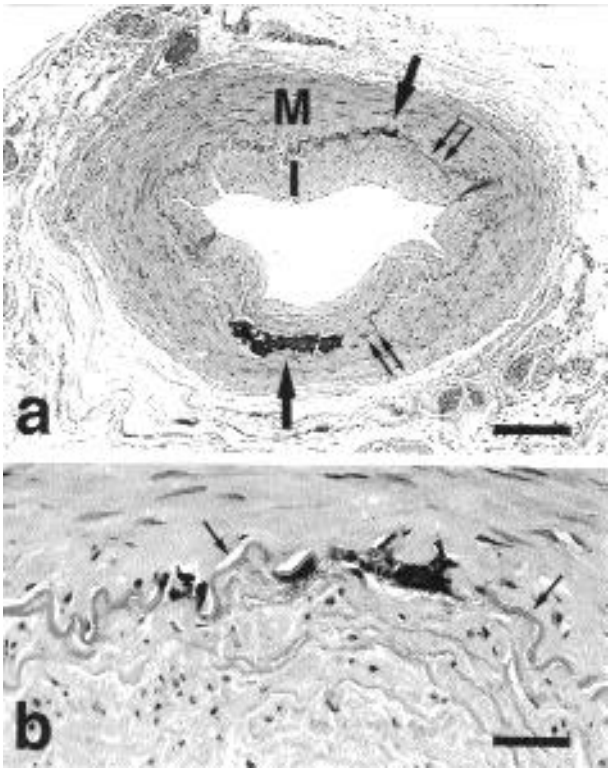

Fig. 1. (**a**) Cross-section of a temporal artery from a 90-year-old woman. **M**: media. **I**: intima. Large arrows: calcifications. **Small arrows**: internal elastic membrane. Haematoxylin and eosin. Bar: 200 m. (**b**) Detail of (a) showing small, dark, granular calcifications. Small arrows:internal elastic membrane. Haematoxylin and eosin. Bar: 50 m.

number of investigated segments per arterial biopsy did not differ between women and men (4.23 ± 1.59 v. 4.19 ± 1.63; ±SD). The average number of investigated segments did not differ significantly between calcified and non-calcified arteries for men or women.

The chi-square test was used to analyse the differences in the occurrence of calcified arteries between women and men. The Mann-Whitney rank sum test was used to evaluate differences in age between patients with and without arterial calcification.

For each autopsy case scores were calculated, based on the reported degree of atherosclerosis in the aorta,coronary arteries and basal cerebral arteries respectively (0 = no atherosclerosis; 1 = mild; 2 = moderate; 3 = severe). The aortic, coronary and cerebral atherosclerosis scores in patients with and without temporal artery calcification were then compared, using Mann-Whitney rank sum test.

Results

Thirty-nine per cent of the temporal arteries displayed focal calcifications of varying size and shape which covered the outer and/or inner surfaces of the IEM (Fig. 1). The latter was sometimes partly concealed by calcified masses. The periphery of the calcifications had a granular appearance, whereas their more compact centres were often fragmented due to the sectioning. They stained dark violet with haematoxylin-eosin, greyish brown or greyish yellow with the van Gieson method and were light blue to dark blue in the plastic sections stained according to Richardson. The calcifications in paraffin sections stained black with the van Kossa method. Large calcifications encroached on the media, but they were all connected with the IEM. Calcifications of the Mönckeberg type, located entirely within the media, were not found in any of the cases.

Patients with IEM calcifications proved to be older than those without calcifications when the complete material was analysed (p = 0.0006) and also when women and men were analysed separately (p = 0.0056, p = 0.0199). IEM calcifications were more common in women than in men (p = 0.0187) (Figs. 2 and 3). Among the women, the number of segments which displayed calcification in each case increased with age (p = 0.0416). The latter could not be analysed in the men due to the low number of calcified arteries.

IEM calcifications were found in 2 of 9 patients with arterial hypertension and in 1 of 5 patients with diabetes mellitus. The patient with both disorders did not display calcification.

Patients with IEM calcification in their temporal artery displayed slightly higher atherosclerosis scores in the aorta, coronary arteries and basal cerebral arteries (Table II). However, these differences were not statistically significant.

Discussion

Previous morphological studies indicate that the first phase of the inflammatory process in GCA is a foreign-body, giant-cell attack on IEM calcifications (3,4). It could be argued that calcified and atrophic lesions in temporal artery biopsies are sequelae after previous arteritis. However, the lesions are free from fibroblastic and microvascular proliferation, which contradicts post-inflammatory scarring (3,4). Moreover, the circumference of the non-inflamed calcified arterial seg-

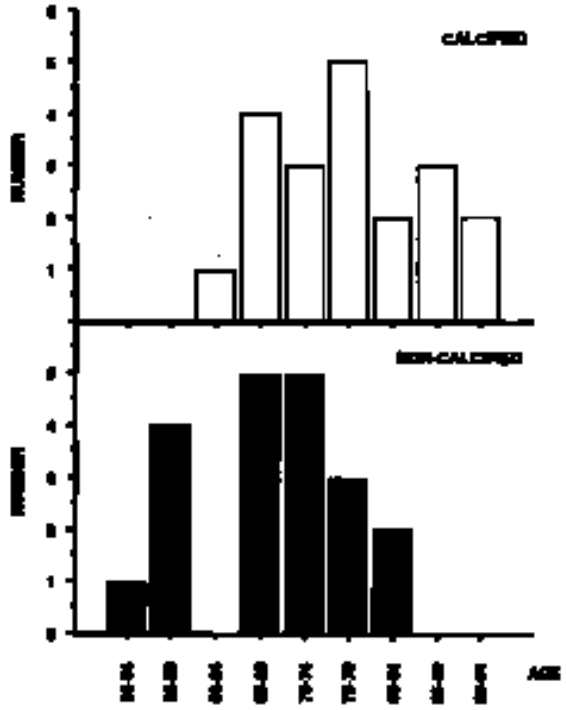

Fig. 2. Number of calcified and non-calcified temporal arteries in 40 women, divided into nine age classes.

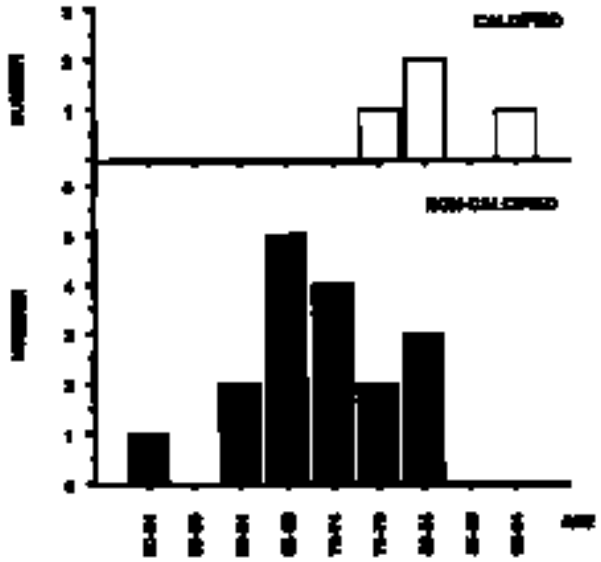

Fig. 3. Number of calcified and non-calcified temporal arteries in 21 men, divided into nine age classes.

Table II. Atherosclerosis scores in patients with and without temporal artery IEM calcification (0:none, 1:mild, 2:moderate, 3:severe) (±SD). Number of cases within brackets.

	Aorta	Coronary	Cerebral
IEM calcification in temporal artery	2.7 ± 0.7 (16)	2.7 ± 0.7 (16)	2.1 ± 0.8 (16)
No IEM calcification in temporal artery	2.6 ± 0.6 (17)	2.1 ± 0.9 (18)	1.6 ± 0.9 (17)

ments is smaller than that of inflamed arteries, which makes it unlikely that the calcified atrophic lesions are post-inflammatory; arteries which are dilated due to wall damage do not decrease their circumference with time (3, 4). Finally, the present study, as well as earlier reports, shows that IEM calcifications may be found in elderly patients known not to have arteritis, which lends further support to the hypothesis that the calcified lesions are primarily atrophic and not post-inflammatory (3, 5).

The IEM calcifications should not be confused with Mönckeberg's mediosclerosis, a segmental form of arterial calcification which is confined to the media and does not involve the intimal layer (7-9). The latter is observed most frequently in muscular arteries of the extremities, but it may involve visceral arteries and has even been found in the temporal artery (10). Mönckeberg's mediosclerosis is more frequent in diabetes mellitus (7, 9). The present observations did not suggest a pathogenetic relationship between IEM calcifications and diabetes mellitus or arterial hypertension. Nor did these calcifications bear any resemblance to the type of dystrophic calcification which may be seen in atherosclerotic intimal plaques (11). Atherosclerotic lesions were not seen in the temporal arteries. Moreover, the aortic, coronary or cerebral atherosclerosis was not more pronounced in patients with IEM calcifications.

The present results show that, in the general population, IEM calcifications increase with advancing age. Moreover, they proved to be 2.62 times more common among women than men, aged 50 or more. GCA is rarely seen before 50 years of age, its incidence increases with age and it is reported to be more common in women (for references, see 6). A recent investigation in Göteborg revealed a 2.38 times higher incidence of biopsy-proven GCA in women than in men, aged 50 or more (6). Similarities between the patients with GCA and individuals with IEM calcifications in terms of age and sex distribution lend support to our hypothesis that the latter play a role in the pathogenesis of GCA. According to previous morphological observations, the inflammatory reaction is initiated by a foreign-body, giant-cell attack on IEM calcifications (3, 4). However, it remains to be explained why the latter only cause the foreign-body reaction in some individuals. Regarding additional factors contributing to the initiation of this inflammatory process, GCA has previously been associated with various infections (for references, see 12).

Theoretically, infection might directly induce the formation of foreign-body giant cells or act as a trigger by activating the immune system.

Our observations may suggest that the presence of IEM calcifications in the general population influences the age and sex distribution of GCA. Further studies are needed to elucidate whether differences in GCA incidence between different communities and ethnic groups are related to differences in terms of IEM calcification.

Acknowledgements

The skilled technical assistance of Margareta Persson is gratefully acknowledged.

References

1. LIE JT: Occidental (temporal) and oriental (Takayasu) giant cell arteritis. *Cardiovasc Pathol* 1994; 3: 227-40.
2. LIEJT: When is arteritis of the temporal arteries not temporal arteritis ? *J Rheumatol* 1994; 21: 186-9.
3. NORDBORG E, BENGTSSON B-Å, NORDBORG C: Temporal artery morphology and morphometry in giant cell arteritis. *APMIS* 1991; 99: 1013-23.
4. NORDBORG C, NORDBORG E, PETURSDOTTIR V: The pathogenesis of giant cell arteritis; Morphological aspects. *Clin Exp Rheumatol* 2000; 18 (Suppl. 20): S18-S21.
5. LIE JT, BROWN AL, CARTER ET: Spectrum of aging changes in temporal arteries. *Arch Path* 1970; 90: 278-85.
6. PETURSDOTTIR V, JOHANSSON H, NORDBORG E,NORDBORG C: The epidemiology of biopsy-positive giant cell arteritis:special reference to cyclic fluctuations. *Rheumatology* 1999; 38: 1208-12.
7. LACHMAN AS, SPRAY TL, KERWIN DM, SHUGOLL GI, ROBERTS WC: Medial calcinosis of Mönckeberg. A review of the problem and a description of a patient with involvement of peripheral, visceral and coronary arteries. *Am J Med* 1977; 63: 615-22.
8. MÖNCKEBERG JG: Über die reine Mediaverkalkung der Extremitätenarterien und ihr Verhalten zur Arteriosklerose. V*irchows Arch Pathol Anat* 1902; 171: 141-67.
9. MOSKOWITZ M, VERANI M: Monckeberg's arteriosclerosis revisited: Or silver vessels among the old. *J Can Assoc Radiol* 1976; 27: 200-3.
10. CASTILLO BV, TORCZYNSKI E, EDWARD DP: Monckeberg's sclerosis in temporal artery specimens. *Br J Ophthalmol* 1999; 83: 1091-2.
11. GOTLIEB AI, HAVENITH MG: Atherosclerosis: lesions and pathogenesis. *In* SILVER MD (Ed.): *Cardiovascular Pathology*. 2nd ed. Churchill Livingstone Inc. 1991; Volume 1: 225-65.
12. NORDBORG C, NORDBORG E, PETURSDOTTIR V: Giant cell arteritis. Epidemiology, etiology and pathogenesis. *APMIS* 2000; 108: 713-24.