# Clinico-pathological conference

*edited by H.M. Moutsopoulos*

# Midfacial swelling and oro-nasal involvement in a 53-year-old patient with bilateral pulmonary infiltrations

C.P. Mavragani[1], S. Paikos[2], I. Doussis-Anagnostopoulou[3], M. Voulgarelis[1]

[1]*Department of Pathophysiology, Medical School, National University of Athens;*
[2]*Dental Clinic, "Laiko" General Hospital;*
[3]*Department of Histopathology and Embryology, Medical School, National University of Athens, Greece.*

*Clio P. Mavragani, MD, Fellow in Rheumatology; Spiros Paikos, DDS; Ipatia Doussis-Anagnostopoulou, MD, PhD, Lecturer; Michalis Voulgarelis, MD, Hematologist, Lecturer.*

*Please address correspondence to: Michalis Voulgarelis, MD, 75 M. Asias, 115 27 Athens, Greece.*

*Received on April 11, 2001; accepted on June 21, 2001.*

*Clin Exp Rheumatol 2001; 19: 577-581.*

© *Copyright CLINICAL AND EXPERIMENTAL RHEUMATOLOGY 2001.*

**Key words:** Wegener's granulomatosis, lymphomatoid granulomatosis, angiocentric immunoproliferative lesions, polymorphic reticulosis, nasal NK/T lymphoma.

**Case report**

*(Dr C. Mavragani)*

A 53-year old high school teacher was admitted to our hospital because of progressive swelling of the left maxillary area of his face over the last week.

The patient, with a history of heterozygous -thalassemia, had been completely well until four months previously, when he first presented to his general practitioner with swelling and a painful sensation in his left cheek which did not improve despite treatment with various antibiotics. Two months later he complained of recurrent episodes of chills and high fever. At that time he was referred to an ENT (ear-nose-throat) specialist, who performed the surgical excision of a nasal polyp. The complaints did not abate. Chest X-ray films revealed bilateral pulmonary infiltrates and on the full blood count leukopenia was evident. The patient was referred to another hospital for further evaluation.

After five weeks of hospitalization the diagnosis of microscopic polyangiitis was made on the basis of lung and nasal mucosa biopsies, which were reported to reveal necrotic vasculitic lesions of the medium and small-sized vessels (lymphocytic inflammatory infiltrate of the vessel wall). The patient was discharged on methylprednisolone tablets 48 mg qd and cyclophosphamide tablets 50 mg bid with improvement of clinical and radiological features. Some weeks later he was readmitted because of post-operative infection at the site of the lung biopsy, for which he received antibiotic therapy. Three weeks later the patient was admitted to our outpatient rheumatology clinic for a thorough evaluation because of increasing swelling of the left maxillary area.

On admission the physical examination was significant for swelling and induration of the left facial maxillary area with periorbital swelling and closure of the left eye, as well as necrotic ulcers of the hard palate (Fig. 1 a, b). A pus-producing sinus was found in the left posterior thoracic wall. A diastolic murmur 1/6 was heard in the aortic area. Mild hepatosplenomegaly but no peripheral lympadenopathy was detected. The rest of the examination was unremarkable.

The laboratory results on admission were the following: hematocrit 37.3%, hemoglobin level 12.3 g/l, and white cell count 7,100/mm$^3$ with neutrophils 76%, lymphocytes 17%, monocytes 7% and eosinophils 1%. The platelet count was 151,000/mm$^3$ and the ESR 20 mm/hr. C-reactive protein was 20.60 mg/dl and the urinalysis was normal. The clotting and biochemical profile were also normal. The virological and immunological results (including antinuclear antibodies, perinuclear and cytoplasmic ANCA) were negative.

An electrocardiogram revealed sinus tachycardia. An x-ray film of the chest revealed bilateral pulmonary infiltrates. A tuberculin test was negative. Bone marrow and cerebrospinal fluid (CSF) examination were normal. A computed thoracic (CT) scan of the thorax confirmed the presence of bilateral infiltrates with areas of central necrosis, revealing also medium-sized paratracheal lymph nodes. A magnetic resonance imaging study (MRI) of the facial cranium revealed subcutaneous edema in the left maxillary area with bony invasion at the level of the left lateral segment of the maxillary bone.

Cultures obtained from the mouth ulcers revealed the presence of *Staphylococcus aureus*, *Aspergillus niger*, and *Candida* species. With the strong suspicion of infection, cyclophosphamide was stopped and intense antibiotic



**(a)** **(b)**

**Fig. 1. (a)** Marked edema of the left maxillary area of the face with periorbital swelling; **(b)** necrotic ulcers of the hard palate (Dr S.Paikos).

treatment covering Gram (+), Gram (-), and anaerobic bacteria as well as fungi was administered without improvement of his clinical picture. Furthermore, episodes of high fever were reported without any evident site of infection. A diagnostic biopsy was performed.

**Differential diagnosis**

*(Dr M. Voulgarelis)*

In summary this 53-year-old patient had a 4-month febrile illness that was initially confined to the nasal cavity but subsequently involved the oral cavity, lung, skin and subcutaneous tissues. The differential diagnosis in this case included granulomatous or infectious diseases, angiocentric immunoproliferative lesions, and lymphomas.

Several features of this case raised the possibility of Wegener's granulomatosis (WG). The disease is characterized by necrotizing vasculitis with granulomas of the upper and lower respiratory tract associated with focal glomerulonephritis. In the limited form of the disease, there is no evidence of glomerulonephritis or upper respiratory tract involvement. Although typical WG is more common in men than in women, the limited form is more common in women (1, 2). The clinical presentation varies, but 90% of patients present with symptoms in the upper or lower airways. Although nasal and sinus involvement form part of the characteristic triad, palatal ulceration is rare. On the other hand, nasal obstruction and crusting with an appearance similar to that of atrophic rhinitis are the most common presenting symptoms. The oral lesions are also ulcerative and midfacial pain is frequent, whereas perforation of the cartilaginous septum is rare. Secondary bacterial infection with *Staphylococcus aureus* is common (1-3). The chest radiograph is abnormal at presentation in 75% of the cases. Single or multiple nodules, infiltrative lesions, air bronchograms, cavitation and low-density necrosis on CT scanning have been reported (4,5). Fever is the initial manifestation in 23% of the patients. Among the abnormal laboratory findings, leukocytosis rather than leukopenia is typical for this disease. The test for antineutrophil cytoplasmic antibodies has a sensitivity of 90% for active WG, but in the limited form of the disease the test is positive in 60 - 70% of cases (1,6). Of critical importance in the diagnosis are the histopathological findings. The hallmark of WG is a granulomatous vasculitis. Although intense inflammation and necrosis in some biopsy specimens from the nose and sinuses may obscure this finding, multiple biopsies will ultimately reveal vasculitis with plentiful giant cells (3).

In our patient, the presence of multiple pulmonary infiltrations and the oronasal cavity involvement without laboratory evidence of kidney involvement could suggest the limited form of WG, despite the negative test for antineutrophil cytoplasmic antibodies. On the other hand the palatal ulceration, leukopenia, lack of granuloma formation in multiple biopsies and the presence of lymphoid cells rather than neutrophils infiltrating the vessel wall could shed doubt on the diagnosis of WG.

Sarcoidosis can involve the structures of the nasopharynx, particularly the salivary glands, nose, larynx and tonsil, in association with active intrathoracic or cutaneous disease. Involvement of the nose by sarcoidosis is rare. The nasal findings include crusting and nodules on the inferior turbinate or cartilaginous septum. These lesions are the result of submucosal non-caseating granulomas. The clinical manifestations are nasal obstruction, epistaxis and nasal discharge (7). However, the absence of giant cells or granulomas in the biopsy specimens, as well as the destructive clinical picture seen in this case, make this diagnosis unlikely.

Fungal infections are an important consideration in an immunosuppressed patient who presents with lung involvement, periorbital swelling, increasing pain and induration of the left maxillary area of the face. Mucormycosis is most commonly recognized in its rhinocerebral form. It generally occurs in the clinical setting of diabetic ketoacidosis or a hematological malignancy. It usually starts in the nose and paranasal sinuses and spreads rapidly to the orbit and intracranially (8). The phycomycetes have a characteristic tendency to invade the blood vessels and produce vascular thrombosis, infarction, hemorrhage, and ischemic

necrosis. The clinical features include nasal crusting and discharge, facial pain and swelling. When the crusts are removed, black gangrenous nasal mucose is revealed. Ischemic necrosis may also involve the facial skin and soft tissues. The orbital involvement most often includes proptosis, edema, and chemosis of the eyelids. In addition, the pupil becomes fixed with deterioration in the vision. Finally seizures, signs of cerebrovascular accident, and coma develop (8). The diagnosis is based on the demonstration of fungi on tissue biopsy.

*Aspergillus* and *Candida* characteristically cause multiple pulmonary infiltrates, as observed in this case. However, invasive infections by these opportunistic organisms are most frequently associated with prolonged periods of severe neutropenia in a setting of admission to a hospital and the use of broad-spectrum antibiotics. Furthermore, fungi should have been evident histologically. Thus, the positive cultures for *Candida* and *Aspergillus niger* in this case reflect most probably colonization rather than invasion.

The term "angiocentric immunoproliferative lesions" (AIL) was introduced in order to include a spectrum of disorders ranging from lymphomatoid granulomatosis (LG) and polymorphic reticulosis (PR) to angiocentric lymphoma. The term is desirable because it conveys both the proliferative character of the lesions, as well as its cytologic composition and the angiocentricity of the process. A lesion may be considered as angiocentric when there is a preferential concentration of cells around and within the blood vessels with infiltration and destruction of the blood vessel wall. Many investigators consider that LG and PR represent the same process, the latter affecting primarily the upper airways (9). Recent studies however suggest that the pulmonary and midfacial lesions may be distinct disorders (10). Progression to lymphoma exhibiting a similar angiocentric and angiodestructive character is observed in both LG and PR, and it is hypothesized that these lymphomas represent the end point in the morphologic spectrum of AIL and represent parts of a single clinicopathologic entity (9). Although many cases of AIL meet the clinical and histological criteria for lymphoma, it remains uncertain whether are all malignant. Angiocentric lymphoma, wherever it occurs, has distinctive anatomical and cytologic features, as well as a different natural history from that of the usual non-Hodgkin lymphomas. The lesion tends to occur in extra-nodal sites such as the lung (LG), nose and paranasal sinuses (PR), and even when the process is generalized, it may spare the lymph nodes (9).

Lymphomatoid granulomatosis (LG) is an angiocentric and angiodestructive lesion with a polymorphic mononuclear cellular infiltrate consisting of small lymphocytes, plasma cells and variable numbers of large immunoblasts. Both the small arteries and veins are involved and the necrosis usually shows a vascular distribution. The disease presents in middle age, and men are affected more often than women. Many organs can be involved, including the lungs, skin, liver, kidneys and central and peripheral nervous system (11, 12). The high frequency of skin lesions, the central nervous system involvement, and the absence of glomerulonephritis distinguish this disorder from WG (12) Although grossly the pulmonary lesions of LG may resemble WG, the histological distinction is usually straightforward. Multi-nucleated giant cell or true granulomas are not a feature of LG and lymphoid cells are relative sparse in WG. Furthermore the necrosis of LG is usually coagulative in character, whereas in WG abundant cellular and nuclear debris is present, secondary to the prominent neutrophilic infiltrate (9)

The primary presenting symptoms in patients with LG include fever, cough, pleuritic chest pain, weight loss, malaise, dyspnea, and neurological disturbances. The most common radiographic abnormality is the presence of bilateral pulmonary nodules with a lower lobe predominance and a tendency towards a peripheral location. Cavitation is observed in 30% of cases. Air bronchograms can be seen within the nodules, which may become confluent, with an infiltrative character (11). Patients with LG may have a decreased hematocrit, whereas leukopenia and lymphopenia is observed in 20% and 33% respectively. An association with erythrophagocytosis has been reported in some of the cases (11). The skin is involved in 40-45% of patients and may be the presenting manifestation of the disease. Erythematous macules, papules, and plaques may be seen over the gluteal areas and legs. Nodules, which can occasionally ulcerate, may resemble erythema nodosum, but are found more commonly over the trunk than over the arms and legs (13).

The disease has been reported to progress to angiocentric lymphoma in 13-45% of cases. It is unclear whether the disease is a neoplastic process at onset or whether it evolves into lymphoma from a chronic and aberrant immunologic response (9,12). Although most cases with histologic features of LG appear to be Epstein-Barr virus (EBV)-related B-cell lymphomas, a minority appear to be T-cell lymphomas (10). In our patient the presence of constitutional symptoms, multiple pulmonary infiltrates, the lymphoid infiltration around and within blood vessels associated with necrosis, and the absence of giant cells or granuloma in biopsy specimens of the lung are suggestive of LG. On the other hand, the presence of palatal ulcer, facial pain, and swelling in the left half of the face and orbit are not consistent with the diagnosis of LG.

Polymorphic reticulosis (PR) is a term used to describe aggressive lymphoreticular lesions involving the upper aerodigestive tract or midline facial structures. The clinical features of PR form part of the spectrum of lethal midline granuloma, a term which describes the clinical appearance of destructive midfacial lesions (14) The histological features of PR are identical to those of sinonasal AIL, and are characterized by angiocentic and angioinvasive lymphoid infiltrates with a wide range of cytologic atypia. The atypical lymphoid infiltrate often invades the cartilage and bone and is commonly associated with extensive necrosis and mucosal ulceration. These morphologic features

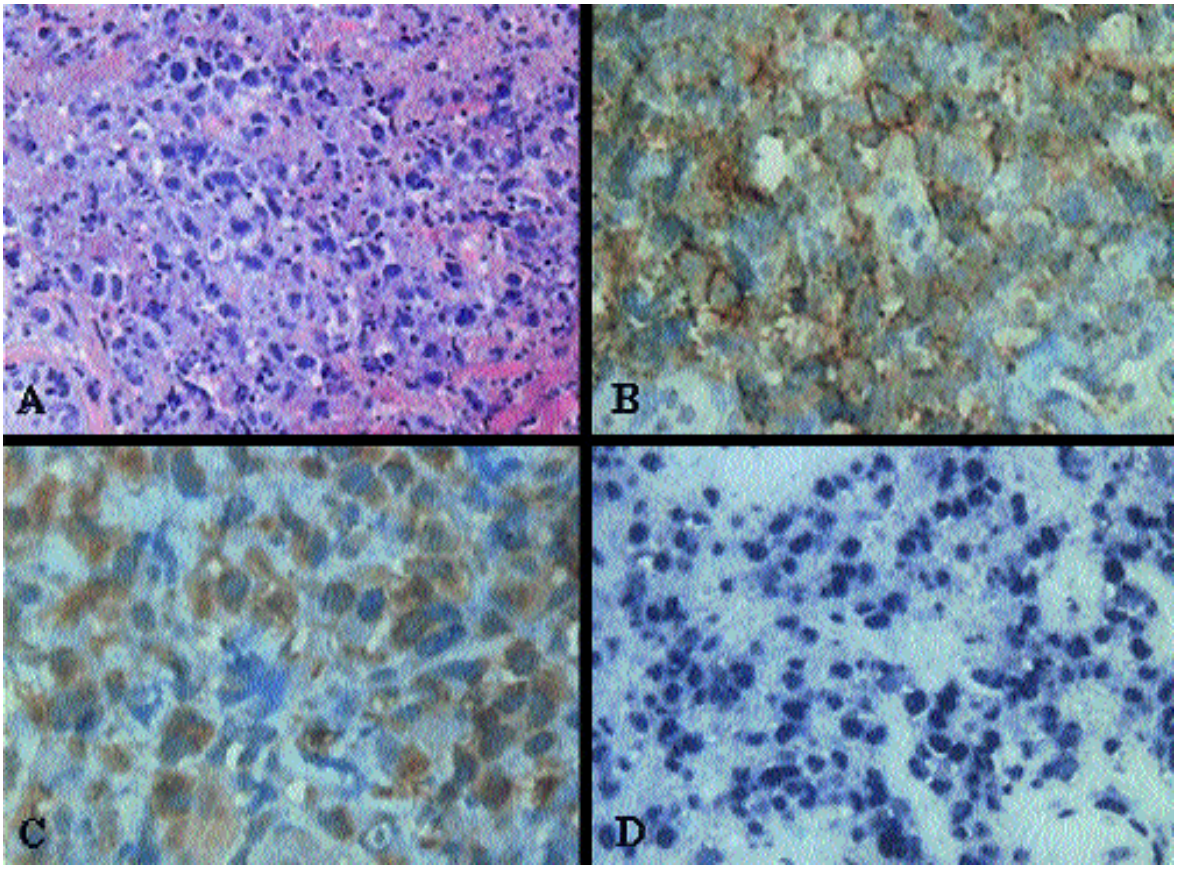


**Fig. 2. (A)** The polymorphic neoplastic population was characterized by irregular, mediun sized lymphoid cells associated with areas of necrosis (H-E,x20). **(B)** The neoplastic cells were positive for the NK-cell marker CD56 (x40) and **(C)** showed cytoplasmic positivity for CD3 (x40). **(D)** EBER1 was demonstrated by *in situ* hybridazation (x40).

closely resemble the histologic features of angiocentic T-cell lymphomas in other locations. The immunophenotypic profile of lymphoid infiltrate is highly characteristic: CD2 positive, surface CD3 negative, cytoplasmic CD3 positive, CD56 positive and frequently negative for other T-lineage markers (14, 15). Most studies have failed to show rearrangements of the T-cell receptor genes; thus it is suggested that PR is an angiocentric nasal NK/T-cell lymphoma more common among Orientals and Mexicans than in Western populations. Epstein-Barr virus can be demonstrated in almost all cases (14, 15).

Patients with nasal NK/T lymphomas (PR) are most often men who present with nasal obstructive symptoms or upper respiratory tract ulceration, sometimes superimposed on longstanding rhinitis or sinusitis. In other cases it presents with a mass effect (nasal mass or obstruction). Constitutional symptoms are often prominent out of all proportion to the upper airway disease. The upper respiratory tract lesions are progressive but may wax and wane. Once oral ulceration occurs there is usually a relentless progression with destruction of midfacial tissues, including the palate, nose and paranasal sinuses and ultimately erosion of blood vessels, the meninges, and face (14). The extensive tissue necrosis is often associated with conspicuous clinical symptoms such as erythema and swelling. Nasal NK/T lymphomas may remain localized to the upper respiratory tract or disseminate to involve other sites such as the skin, lungs, gastrointestinal tract, testis, and kidneys (16). The skin and subcutaneous tissues are the predominant sites of secondary spread. Interestingly, rare cases may present in the skin or soft tissue and relapse in the nose. The skin disease mainly appears as lobular panniculitis. It could be speculated that differences in the degree of angiodestruction and panniculitis with necrosis depend on the amount of secretion of perforin and the activation of the infiltrating atypical NK cells (17). However, lung involvement is rare (16). This finding emphasizes the distinction from pulmonary LG, which resemble nasal NK/T lymphomas histologically.

In summary the clinical picture of our patient with pulmonary infiltrations, palatal ulceration, nasal mass, and swelling in the left half of the face and orbit is consistent with lymphomatous angiocentric processes such as nasal NK/T angiocentric lymphoma (polymorphic reticulosis), lymphomatoid granulomatosis and finally T-peripheral lymphoma.

**Pathological discussion**

*(Dr I. Doussis-Anagnostopoulou)*

Two small skin biopsy specimens were received, measuring 3 and 2.4 cm in diameter. In the larger one, the dermis was diffusely infiltrated by a polymorphic neoplastic population of medium-sized lymphoid cells with atypical, irregular, hyperchromatic nuclei, in-

conspicuous nucleoli and scanty cytoplasm. Multiple mitotic figures were present. Foci of necrosis were seen. The neoplastic cells focally invaded the vessel walls, as well as the basal layer of the epidermis and of the epidermal adnexae. The smaller specimen was totally necrotic.

Immunohistochemically, the neoplastic cells were positive for the common leucocyte antigen (LCA, DAKO clone 2B11 + PD7/26), the natural killer (NK) cell molecule CD56 (Novocastra, clone CD56 1B6), and CD45RO (UCHL 1, DAKO clone UCH4), and presented cytoplasmic CD3 positivity (DAKO, CD3 polyclonal) which is also an NK cell feature, and a weak reaction with the activation marker CD30 (DAKO, clone BerH2) and EMA (DAKO, clone E29). They were negative for CD8 (DAKO, clone S8/114B), CD5 (DAKO, clone CD5/54/F6), and the B cell markers CD20 (DAKO, clone L26) and CD79a (ICRF Immunodiagnostics Lab, Oxford). The proliferation marker Ki67 (Novocastra, clone MM1) was positive in approximately 80% of the tumour cells. Using polymerase chain reaction (PCR) no T cell receptor rearrangement was found. An *in situ* hybridization study for EBV using the EBER1 probe (DAKO) demonstrated the presence of EBV in the neoplastic cells.

Review of slides of the previous lung biopsies revealed extensive areas of necrosis and focal invasion of medium-sized vessel walls by a population of mature lymphocytes consistent with vasculitis.

**Anatomical diagnosis**

Extra-nodal NK/T-cell lymphoma, nasal type.

**Follow-up**

*(Dr C. Mavragani)*

Treatment with intravenous CHOP (Cyclophosphamide-Doxorubicin-Vincristine-Prednisolone) was started and the patient was discharged. Ten days after the administration of the chemotherapeutic regimen the patient was readmitted because of fever, hypotension and profound leukopenia. The facial swelling was markedly reduced. After the administration of intravenous fluids, a combination of wide spectrum antibiotics, and Granulocyte-Colony-Stimulating Factor (G-CSF), the patient recovered. At present he is well with decreased facial swelling.

**References**


1. HOFFMAN GS, KERR GS, LEAVITT RY *et al*.: Wegener's granulomatosis: An analysis of 158 patients. *Ann Intern Med* 1992; 116:488-98.
2. FAUCI AS, HAYNES BF, KATZ P, WOLFF SM: Wegener's granulomatosis:Prospective clinical and therapeutic experience with 85 patients for 21 years. *Ann Intern Med* 1983; 98: 76-85.
3. BOKI KA, DAFNI U, KARPOUZAS GA, PAPASTERIADES C, DROSOS AA, MOUTSOPOULOS HM: Necrotizing vasculitis in Greece:Clinical,immunological and immunogenetic aspects. A study of 66 patients. *Br J Rheumatol* 1997; 36: 1059-66.
4. FARRELLY CA: Wegener's granulomatosis: A radiological review of the pulmonary manifestations at initial presentation and during relapse. *Clin Radiol* 1982; 33: 545-51.
5. PAPIRIS SA, MANOUSSAKIS MN, DROSOS AA, KONTOGIANNIS D, CONSTANTOPOULOS SH, MOUTSOPOULOS HM: Imaging of thoracic Wegener's granulomatosis: The computed tomographic appearance. *Am J Med* 1992; 93: 529-36.
6. NOLLE B, SPECKS U, LUDEMANN J, ROHRBACH MS, DE REMEE RA, GROSS WL: Anticytoplasmic autoantibodies: their immunodiagnostic value in Wegener granulomatosis. *Ann Intern Med* 1989; 111: 28-40.
7. MIGLETS AW, VIALL JH, KATARIA YP: Sarcoidosis of the head and neck. *Laryngoscope* 1977; 87: 2038-48.
8. BLITZER A, LAWSON W, MEYERS BR, BILLER HF: Patient survival factors in paranasal sinus mucormycosis. *Laryngoscope* 1980; 90: 635-48.
9. LIPFORD EH, MARGOLICH JB, LONGO DL, FAUCI AS, JAFFE ES: Angiocentric immunoproliferative lesion: A clinicopathological spectrum of post-thymic T cell proliferations. *Blood* 1988; 72: 1674-81.
10. NICHOLSON AG, WOTHERSPOON AC, DISS TC *et al.*: Lymphomatoid granulomatosis: evidence that some cases represent Epstein-Barr virus associated B-call lymphoma. *His - topathology* 1996: 29: 317-24.
11. Lymphomatoid granulomatosis: A clinicopathological study of 152 cases. *Cancer* 1979; 43: 360-73.
12. FAUCI AS, HAYNES BF, COSTA J, KATZ P, WOLFF SM: Lymphomatoid granulomatosis: prospeotive clinical and therapeutic experience over 10 years. *N Engl J Med* 1982; 306: 68-74.
13. MINARS N, KAY S, ESCOBAR MR: Lymphomatoid granulomatosis of the skin: A new clinicopathological entity. *Arch Dermatol* 1975; 111: 493-6.
14. STRICKLER JG, MENESES MF, MABERMANNTM *et al.*: Polymorphic reticulosis. A reappraisal. *Hum Pathol* 1994; 25: 659-65.
15. PETRELLA T, PELFAN-LARUE MH, CAILLOT D *et al.*: Nasopharyngeal lymphomas. Further evidence of a natural killer cell origin. *Hum Pathol* 1996; 27: 827-33.
16. JAFFE ES, CHAN JKC, SU IJ *et al.*: Report of the workshop of nasal and related extranodal angiocentric T/NK cell lymphoma. *Am J Surg Pathol* 1996; 20: 103-11.
17. TAKESHITA M, AKAMATSU M, OHSHIMA K *et al.*: Angiocentric immunoproliferative lesions of the skin show lobular panniculitis and are mainly disorders of large granular lymphocytes. *Hum Pathol* 1995; 26: 1321-1328.