

Recurrent pleural effusion is an important diagnostic clue to distinguish familial Mediterranean fever from Behçet's disease

Sirs,

In April 2012, a 39-year-old Japanese male presented with a three-day long history of fever and right-sided chest pain. During the previous four years he had recurring episodes of uveitis and epididymitis. Chest x-ray demonstrated right pleural effusion, which was exudative. An oral antibiotic was initiated based on the suggestion of acute bronchial and pleural infection. However, within a few days of the first visit, his fever reoccurred and he also had a pain in the scrotum. He was diagnosed with epididymitis. For the next four months he did not experience fever or epididymal pain; however, he developed failing vision during this period and was diagnosed with recurrence of uveitis. Another fever attack occurred one month later, this time with left side chest pain and pleural effusion. He was followed closely without any therapy, and his symptoms spontaneously improved. He had no family history of periodic fevers or consanguineous marriage. However, the symptomatic occurrence of periodic fevers with spontaneous improvement suggested auto-inflammatory disorders including familial Mediterranean fever (FMF). His blood lymphocytes harboured the E148Q heterozygote in *MEFV* (Fig. 1), and colchicine was started. His fever attack, chest pain, pleural effusion, uveitis, and epididymitis promptly subsided. His response to adequate colchicine therapy confirmed FMF.

In January 2016, he presented with arthralgia in addition to periodic pain with eruptions in both ankles, consistent with erythema nodosum. Additionally, uveitis recurred although there was no recurrence of any other symptoms on colchicine treatment. Oral corticosteroid therapy was started with colchicine and the symptoms gradually disappeared. He had no episode of oral or genital ulceration but met the standard criteria proposed by the Japan Behçet's Disease Research Committee. Blood lymphocyte analysis showed the presence of human leukocyte antigen (HLA)-B51 and -A26. Eventually he was diagnosed with an incomplete form of Behçet's disease (BD) in combination with FMF. At the last follow up in July 2017, he was symptom free. This is the first report of two independent HLA alleles associated with BD in an FMF patient.

FMF, a hereditary auto-inflammatory disease characterised by recurrent attacks of fever and serositis, is caused by mutations in *MEFV* on chromosome 16, which encodes pyrin, a protein associated with inflammas-

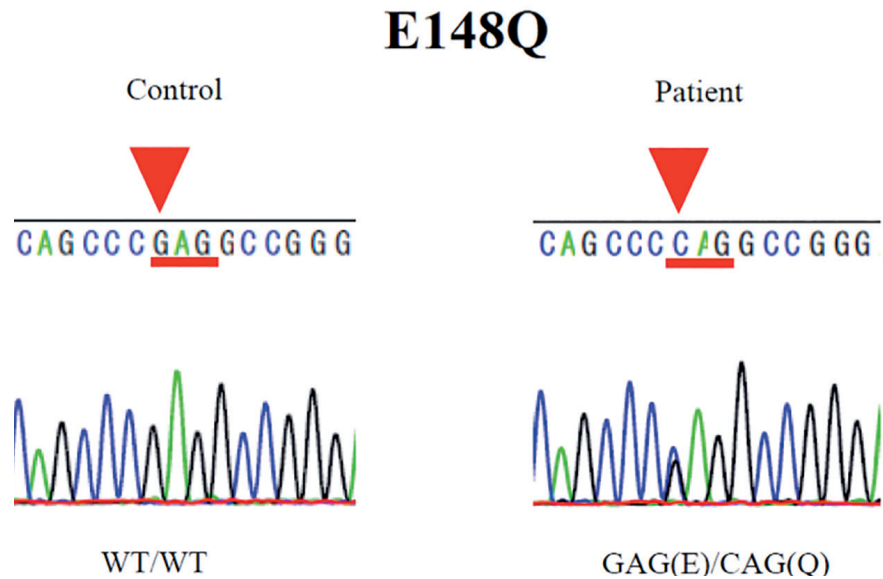


Fig. 1. Sequencing of *MEFV* exon 2 demonstrates a G to S base-pair change (arrows) at amino acid 148.

omes (1). Recent study suggests that pyrin itself is a specific pattern recognition receptor (2). In contrast, the aetiology of BD, a multisystem disorder characterised by recurrent oral and genital ulcerations, cutaneous inflammation, and uveitis, remains unclear. Although FMF and BD share a common regional, treatment, and clinical findings, there are also different symptoms in each disorder. In the current case, a male was diagnosed with FMF by the recurring episodes of fever attack, epididymitis, and chest pain resulting from pleuritis. BD diagnosis was initially eliminated by the absence of mucosal lesions, which are the most common manifestation (3). However, a diagnosis of BD in addition to FMF was determined by the recurrence of uveitis, onset of arthritis, and erythema nodosum. Relapsing uveitis is a major criterion of BD, whereas ophthalmological manifestations of FMF are rare. Pleural effusion is an uncommon manifestation of BD and it usually occurs secondary to pulmonary infarction, vasculitis, or an infectious condition (4). In contrast, FMF is characterised by a shorter duration of febrile attack accompanied by sterile peritonitis and pleuritis. Therefore, recurrent pleural effusion can be present in FMF but not in BD patients. The findings of the current study paradoxically suggest that FMF and BD can be distinguished from each other by the presence of different symptoms. Of note, self-limited pleuritis should be an important diagnostic factor for FMF.

Ethics committee approval

Official approval for gene analysis was obtained in advance from the Ethics Committee for Genomic Research at Shinshu University. The patient provided written informed consent.

Acknowledgements

We would like to thank Kunihiro Fukuchi and Hitoshi Ando for advice about gene analysis, and NAI, Inc. (<http://www.nai.co.jp/>) for proofreading this manuscript.

F. YAMAGUCHI¹, MD
M. TAJIKA¹, MD
D. INOUE¹, MD
Y. SHIKAMA¹, MD
D. KISHIDA², MD
A. NAKAMURA², MD

¹Department of Respiratory Medicine, Showa University Fujigaoka Hospital, Yokohama, Japan;

²Department of Medicine (Neurology and Rheumatology), Shinshu University School of Medicine, Matsumoto, Japan.

Please address correspondence to:

Dr Fumihiko Yamaguchi,
Department of Respiratory Medicine,
Showa University Fujigaoka Hospital,
1-30, Fujigaoka, Aoba-ku,
Yokohama 227-8501, Japan.

E-mail: f_y@med.showa-u.ac.jp

© Copyright CLINICAL AND EXPERIMENTAL RHEUMATOLOGY 2017.

Competing interests: none declared.

References

- MASTERS SL, SIMON A, AKSENTIJEVICH I, KASTNER DL: Horror autoinflammaticus: the molecular pathophysiology of autoinflammatory disease (*). *Annu Rev Immunol* 2009; 27: 621-68.
- XU H, YANG J, GAO W *et al.*: Innate immune sensing of bacterial modifications of Rho GTPases by the Pyrin inflammasome. *Nature* 2014; 513: 237-41.
- IDEGUCHI H, SUDA A, TAKENO M, UEDA A, OHNO S, ISHIGATSUBO Y: Behçet Disease. *Medicine* (Baltimore) 2011; 90: 125-32.
- TUNACI A, BERKMAN YM, GÖKMEEN E: Thoracic involvement in Behçet's disease: pathologic, clinical, and imaging features. *AJR Am J Roentgenol* 1995; 164: 51-6.