

A misleading case of deficiency of adenosine deaminase 2 (DADA2): the magnifying glass of the scientific knowledge drives the tailored medicine in real life

Sirs,

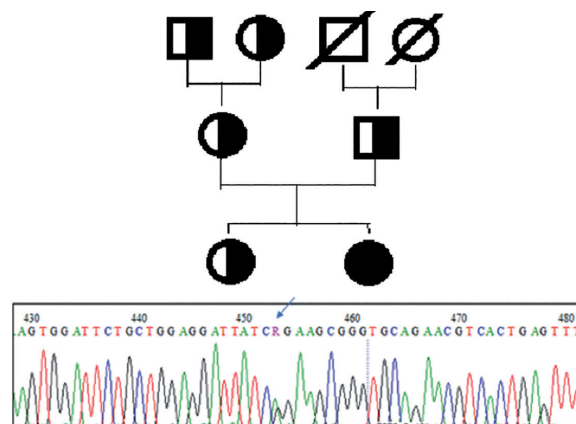
A few years ago, we described the unusual association of cutaneous polyarteritis nodosa (c-PAN) and Common Variable Immunodeficiency (CVID) in a child (1). Recently, her diagnosis has been reviewed considering a new autoinflammatory disease: the deficiency of adenosine deaminase 2 (DADA2), an enzyme mainly expressed by myeloid lineage and endothelium.

Firstly described in two different concurrent studies in 2014 (2, 3), DADA2, due to the *CECR1* gene mutation, is characterised by an anti-inflammatory macrophage reduction, an up-regulation of neutrophil expressed genes, an increased secretion of pro-inflammatory cytokines, an increased B cell mortality and endothelium damage (4). Systemic inflammation, mild immune deficiency, and vasculopathy manifested as livedoid rash, recurrent stroke or polyarteritis nodosa depict the 125 cases currently reported (5, 6). Disease onset is widely different, ranging from early infancy to late adulthood, with a spectrum of clinical features broadly variable.

In 2012 we described a Caucasian female followed at our Unit since she was 2 years old (1). Briefly, fever, rash, painful nodular lesions on feet, ankles and pretibial regions, and necrotising non-granulomatous vasculitis findings at skin biopsy were consistent with c-PAN diagnosis. She achieved disease remission on azathioprine (AZA, 3 mg/kg/day), but, after 8 months, hypogammaglobulinaemia (IgA 29.4 mg/dl, normal values for age \pm SD 93 ± 27 mg/dl; IgM 28 mg/dl, normal values 56 ± 18 mg/dl; IgG 571 mg/dl, normal values 929 ± 228 mg/dl), with a poor humoral response to vaccines, appeared. To differentiate the side effects of immunosuppression from CVID onset, AZA was progressively stopped. Since hypogammaglobulinaemia persisted over months, CVID was diagnosed and intravenous immunoglobulins (400 mg/kg, monthly) introduced. Unfortunately, 6 months later, because livedo reticularis, vasculitic lesions on feet, arthralgia, myalgia and nodular lesions flared again, AZA was restarted, and remission subsequently obtained. In addition to the previous report, every attempt to AZA withdrawal resulted in a prompt relapse and due to the appearance of mild leukopenia and thrombocytopenia (3.480 cell/mm^3 and $135.000/\text{mm}^3$) hydroxychloroquine was added (200 mg/daily). Taking into account c-PAN features, hypogammaglobulinaemia, leukopenia and thrombocytopenia, DADA2 was then considered. ADA2 metabolites were measured in blood and urine with tandem mass result-

Fig. 1. Genealogical tree of the index case.

Electropherogram representing the variant c.506G>A; p.R169Q present in heterozygosis at exon 3 of the *CECR1* gene in the parents and sister of the affected patient.



ing in the normal range (plasmatic adenosin 0.57 micromol/l, plasmatic 2-deossiadensin 0 micromol/l, urinary 2-deossiadensin 0.03 mmol/mol, urinary adenosin 0.44 mmol/mol), whilst homozygous *CECR1* mutation Arg169Gln (c.506G→A; chromosome 22:17,687,997C→T) was detected. Parents were heterozygous for mutation, as well as the unaffected sister and the maternal grandmother (Fig. 1). The diagnosis of DADA2 was confirmed, Etanercept was started (50 mg/weekly) and AZA progressively tapered. At 5 months from starting anti-TNF α , she is in good clinical condition with no vasculitic sign. IgG and IgA are currently 1150 and 77 mg/dl, respectively; IgM value improved to 43 mg/dl as well as leucocyte (3920 cell/mm^3) and platelet count ($120.000/\text{mm}^3$).

DADA2 is a clinically and genetically heterogeneous disease and the clinical presentation and course of the reported case is consistent with recent literature. (5). The identified mutation in our patient has been previously described in a cohort who presented phenotypic variability despite the same genetic mutation (7). In particular, immunological abnormalities, although not always present, are quite variable between patients, sometimes may represent the only expression of this disease, mainly affecting B-cells as in our patient (5, 8).

Actually, a current differential approach facing hypogammaglobulinaemia, leukopenia and thrombocytopenia along with cutaneous involvement and systemic inflammation should also include DADA2. In our case, the right diagnostic classification, aiming to potentially prevent a stroke in a child, prompted us to switch to the current recommended treatment, despite the good disease control on AZA. The rapid progress of knowledge prones physicians to keep up to date to better understand the different disease spectrum and achieve the most appropriate care.

I. MACCORA¹, MD
I. FRONGIA¹, MD
C. AZZARI¹, MD, Prof.
S. RICCI¹, MD
R. CIMA¹, MD, Assoc. Prof.
G. SIMONINI¹, MD, Assoc. Prof.

¹Rheumatology Unit, NEUROFARBA Department, Immunology Unit, Department of Health Sciences, AOU A. Meyer Children's Hospital, Florence, Italy.

Please address correspondence to:
Dr Ilaria Maccora,
Rheumatology Unit,
AOU A. Meyer Children's Hospital,
NEUROFARBA Department,
Viale Pieraccini 24,
50139 Firenze, Italy.
E-mail: ilamaccora@gmail.com

Competing interests: none declared.

© Copyright CLINICAL AND EXPERIMENTAL RHEUMATOLOGY 2018.

References

- PAGNINI I, SIMONINI G, LIPPI F, AZZARI C, CIMA R: Cutaneous polyarteritis nodosa and common variable immunodeficiency: a previously unreported association. *Clin Exp Rheumatol* 2012; 30 (Suppl. 70): S169.
- ZHOU Q, YANG D, OMBRELLO AK *et al.*: Early-onset stroke and vasculopathy associated with mutations in ADA2. *N Engl J Med* 2014; 370: 911-20.
- NAVON ELKAN P, PIERCE SB, SEGEL R *et al.*: Mutant adenosine deaminase 2 in a polyarteritis nodosa vasculopathy. *N Engl J Med* 2014; 370: 921-31.
- CAORSI R, PENCO F, SCHENA F, GATTORNO M: Monogenic polyarteritis: the lesson of ADA2 deficiency. *Pediatr Rheumatol Online J* 2016; 14: 51.
- HASHEM H, KELLY SJ, GANSON NJ, HERSHFIELD MS: Deficiency of adenosine deaminase 2 (DADA2), an inherited cause of polyarteritis nodosa and a mimic of other systemic rheumatologic disorders. *Curr Rheumatol Rep* 2017; 19: 70.
- CAORSI R, PENCO F, GROSSI A *et al.*: ADA2 deficiency (DADA2) as an unrecognized cause of early onset polyarteritis nodosa and stroke: a multicentre national study. *Ann Rheum Dis* 2017; 76: 1648-56.
- VAN MONTFRANS JM, HARTMAN EA, BRAUN KP *et al.*: Phenotypic variability in patients with ADA2 deficiency due to identical homozygous R169Q mutations. *Rheumatology (Oxford)* 2016; 55: 902-10.
- SCHIEPP J, PROIETTI M, FREDE N *et al.*: Screening of 181 patients with antibody deficiency for deficiency of adenosine deaminase 2 sheds new light on the disease in adulthood. *Arthritis Rheumatol* 2017; 69: 1689-700.
- SCHIEPP J, BULASHEVSKA A, MANNHARDT-LAAKMANN W *et al.*: Deficiency of adenosine deaminase 2 causes antibody deficiency. *J Clin Immunol* 2016; 36: 179-86.