

Severe cutaneous hand infection: *Mycobacterium marinum* in an immunosuppressed patient

Sirs,

A 48-year-old male professional underwater diver, with a history of ankylosing spondylitis treated with infliximab for eight years and thereafter with adalimumab for the last three years, developed, five months before consulting us, a progressively worsening swelling of his left hand, causing pain and restriction of hand joint movements. He consulted different physicians without proper diagnosis or appropriate therapeutic intervention. Oral corticosteroids were prescribed for presumable "arthritis", which caused increasingly worsening of his hand pain and swelling. At presentation to our outpatient clinic, the patient was afebrile and in intense distress due to pain. A diffuse dorsal and palmar swelling of his left hand along with large erythematous plaques and nodules over all hand joints was evident (Fig. 1A, arrows). After taking a careful and detailed history, we noted that several days before onset of symptoms, while working on an underwater ship repair, he accidentally punctured his left index finger over the dorsal proximal interphalangeal area. Shortly thereafter, painful swelling and erythema developed over the injured area. Upon presentation, laboratory testing was unremarkable, except marginally elevated C-reactive protein. Left hand magnetic resonance imaging (MRI) showed extensive soft tissue swelling, not affecting adjacent bones or joints, and multiple subcutaneous nodules following the lymphatic path in a sporotrichotic distribution along the dorsal and palmar areas of all fingers, on T2-weighted images (Fig. 1B, arrows). Given the patient's history of a recent underwater injury and immunosuppression, the possibility of an atypical mycobacterial infection was raised (1). Adalimumab was discontinued and surgical debridement was performed. Histology of the tissue biopsy showed epidermal hyperkeratosis with non-specific inflammation in the dermis and epidermis, without granulomas, caseation or acid-fast bacilli (2), whereas Gram staining was negative. While awaiting confirmatory diagnostic results and with the working hypothesis of an atypical mycobacterial infection, the patient was placed on clarithromycin (1gr/day), ethambutol (1500 mg/day) and rifampicin (1200 mg/day) (1, 2). Two weeks later, culture of the excised tissues in Löwenstein-Jensen medium at 30°C revealed *Mycobacterium mari-*

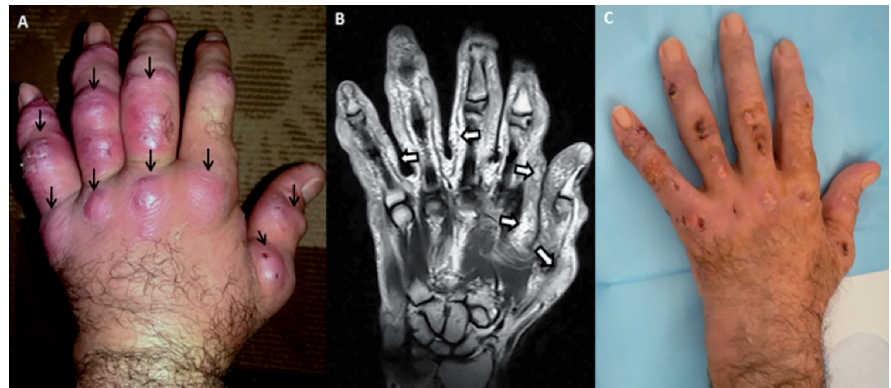


Fig. 1. (A) At presentation a diffuse, painful and restrictive swelling of the dorsal and palmar aspects of the left hand was evident, while erythematous nodules (arrows) were noted over all hand joints (B) left hand MRI revealed extensive soft tissue swelling, without bone erosive lesions, and multiple subcutaneous nodules in a sporotrichotic distribution (arrows), (C) marked improvement was achieved after treatment with combination of antibiotic drugs and a short course of oral methylprednisolone.

num growth and PCR-restriction enzyme analysis of hsp65 confirmed the diagnosis. Despite initial improvement with antibiotic treatment, fourteen days later, an exacerbation and further spreading of the infection to the forearm occurred. This deterioration of the inflammatory process was attributed to immune reconstitution inflammatory syndrome (IRIS). This syndrome can occur in previously immunosuppressed individuals with an acquired opportunistic infection following withdrawal of anti-TNF therapy. When the immune system begins to recover, it responds overwhelmingly to the infection causing a paradoxical worsening of infection symptoms (3). In line with this assumption, oral methylprednisolone (16mg/day) was added to the patient's therapeutic regimen, resulting five days later in marked clinical improvement (Fig. 1C). Human *Mycobacterium marinum* infection, also called aquarium granuloma, swimming pool granuloma or fish tank granuloma is an uncommon disease that mainly affects the cutaneous tissues, primarily in an acral distribution. Although *Mycobacterium marinum* infection affects individuals regardless of their immune status, the histopathological findings, the clinical outcome and the response to treatment may differ between immunocompetent and immunocompromised patients. We present this case to emphasise that a) in order to avoid significant delay in diagnosis of human *Mycobacterium marinum* infection, a high index of suspicion is required, especially if the individual has been traumatised while working in fresh or salty water or while holding fishes b) the suspicion should further be increased if the individual is intensively immunosuppressed and c) in mycobacterial infections affecting

immunosuppressed patients under anti-TNF treatment, halting of the therapeutic intervention and subsequent rapid restoration of TNF signalling may result in a transient paradoxical exacerbation of the inflammatory process (3).

O.D. ARGYROPOULOU¹ MD
E. ZAMPELI² MD, PhD
N.V. SIPSAS¹ MD
A.G. TZIOUFAS¹ MD
H.M. MOUTSOPOULOS^{1,2,3} MD, FACP,
FRCP, MACR

¹Department of Pathophysiology,
School of Medicine, National and
Kapodistrian University of Athens;
²Institute for Autoimmune Systemic
and Neurological Diseases, Athens;
³Academy of Athens, Athens, Greece.

Please address correspondence to:
Dr Evangelia Zampeli,
Institute for Autoimmune Systemic
and Neurological Diseases,
M. Asias 75, 11527, Athens, Greece,
E-mail: zampelieva@gmail.com

Competing interests: none declared.

© Copyright CLINICAL AND
EXPERIMENTAL RHEUMATOLOGY 2018.

References

- JOHNSON MG, STOUT JE: Twenty-eight cases of *Mycobacterium marinum* infection: retrospective case series and literature review. *Infection* 2015; 43: 655-62
- CARON J, MICHOT C, FABRE S, GODREUIL S, GUILLOT B, DEREURE O: Aggressive cutaneous infection with *Mycobacterium marinum* in two patients receiving anti-tumor necrosis factor- α agents. *J Am Acad Dermatol* 2011; 65: 1060-2.
- BARBER DL, ANDRADE BB, SERETI I, SHER A: Immune reconstitution inflammatory syndrome: the trouble with immunity when you had none. *Nat Rev Microbiol* 2012; 10: 150-6.