

Severe cutaneous vasculitis following intravenous infusion of gammaglobulin in a patient with type II mixed cryoglobulinemia

M. Yebra¹, Y. Barrios²,
J. Rincón¹, I. Sanjuan³,
F. Díaz-Espada²

Departments of Internal Medicine¹, Immunology², and Haematology³, Hospital Clínica Puerta de Hierro, Madrid, Spain. Miguel Yebra, MD; Yvelise Barrios, MD, PhD; José Rincón, M.D; Isabel Sanjuan, MD; and Fernando Díaz-Espada, PhD.

Please address correspondence and reprint requests to: Dr. Fernando Díaz-Espada, Department of Immunology, Hospital Clínica Puerta de Hierro, San Martín de Porres 4, 28035 Madrid, Spain. E-mail: fdiaz@hpth.insalud.es

Received on April 6, 2001; accepted in revised form on September 19, 2001.

© Copyright CLINICAL AND EXPERIMENTAL RHEUMATOLOGY 2002.

Key words: Intravenous immunoglobulins, cryoglobulins.

ABSTRACT

Intravenous infusion of gammaglobulins (IVIG) is one of the treatments of choice in patients with type II mixed cryoglobulinemia (MC). We describe the case of a patient with MC who suffered an adverse generalised reaction with severe cutaneous vasculitis accompanied by a sudden increase in cryocrit levels shortly after being treated with IVIG. When the same gammaglobulin preparation was added in vitro to a sample of the patient's serum, a strong increment in cryoglobulin precipitation and depletion of the monoclonal IgM peak resulted. We suggest that this simple method of studying the displacement of the precipitation reaction could help to predict the outcome of treatment and must be performed before starting IVIG in patients with MC.

Introduction

No single treatment has been shown to be the most effective for patients with mixed cryoglobulinemia. Besides general recommendations aimed at providing symptomatic relief, other treatments such as plasmapheresis and corticosteroid, cytostatic or, more recently, interferon administration are not consistently effective or without secondary effects (1, 2). Contrasting outcomes have been described after the intravenous infusion of gammaglobulins (IVIG), an alternative therapeutic approach applied in a small number of cases (3-6). This article describes the case of a patient with type II mixed cryoglobulinemia and bone-marrow B-cell lymphoma who showed serious side effects shortly after being treated with IVIG. In an attempt to find an explanation for this response, we added graded amounts of gammaglobulin to the patient's serum, observing a strong increment in cryoglobulin deposition, a fact that could be related to the clinical deterioration.

Case presentation

A 28-year-old woman was admitted to the hospital in November 1992 with a two-year history of polyarthralgias, arthritis, Raynaud's phenomenon and pethequial cutaneous lesions preferentially localised on the legs. On admis-

sion, her physical examination was normal except for purpuric lesions on the lower extremities. Histopathologic examination revealed the presence of leukocytoclastic angitis. No abnormalities were found in the haematological, hepatic or renal parameters. Type II mixed cryoglobulin containing a monoclonal IgM, kappa and polyclonal IgG was identified. The cryocrit was 6%. Concentrations of immunoglobulins in cryoglobulin-free serum were IgG: 1,030 mg/dL, IgM: 106 mg/dL and IgA: 98 mg/dL. The serum C3 concentration was 62 mg/dL and C4 was < 8 mg/dL. The rheumatoid factor was positive at 1/1280. The serum contained anti-VHC antibodies, but no anti-HIV antibodies or serological HVB markers were found. PCR analysis disclosed the presence of the VHC 1b genotype. Bone marrow aspirates showed no signs of malignancy. Chest roentgenogram and computed tomographic scan were both normal. A falling concentration of IgG and a concomitant increase in IgM marked the course of the disease. Cryocrit levels varied from 4% to 10% and the monoclonal IgM protein was detected sporadically in supernatants from cold-precipitated serum samples.

The patient was sequentially treated with non-steroid anti-inflammatory drugs, corticosteroids and -interferon, with no improvement of the symptoms. In February 1994, new purpuric lesions appeared accompanied by paresthesias and hypoesthesia in the distal region of both legs. The finding of a WBC count of 58,000 (80% lymphocytes) prompted us to evaluate a new aspirate of bone marrow that disclosed the presence of a monomorphous infiltration by plasmacytoid lymphocytes (CD19⁺, CD20⁺, -chain⁺, CD5⁻) compatible with bone marrow lymphoma. Chest X-ray and abdominal CT remained normal. Treatment with polychemotherapy (CVP) resulted in bone marrow remission but not in the amelioration of the cryoglobulinemia related symptoms. Several cycles of plasmapheresis improved the cutaneous lesion, but the treatment had to be interrupted due to catheter infection.

Given the persistence of purpuric lesions and neurological symptoms, we

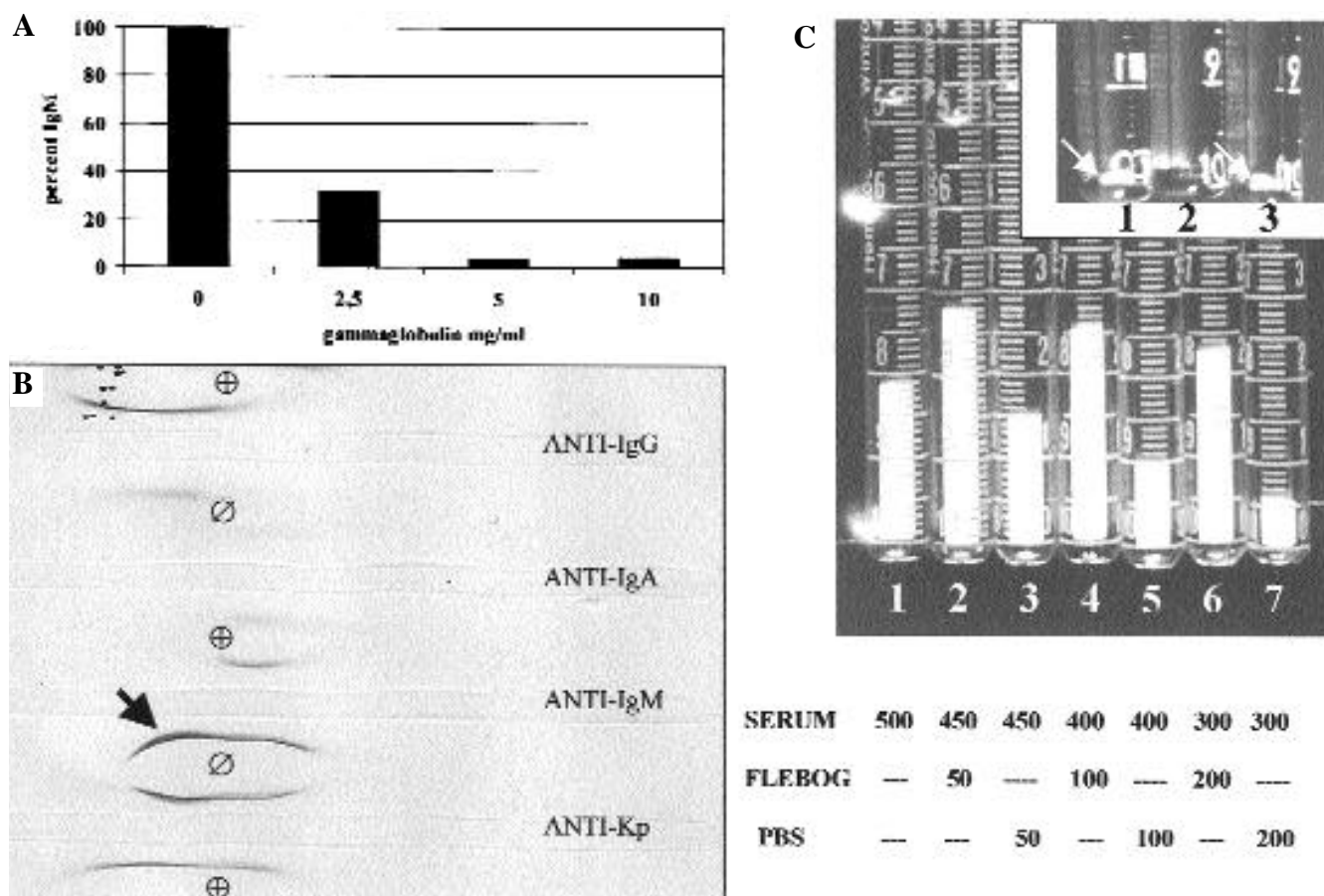


Fig. 1. (A) Percentage of IgM remaining in the supernatant of cold-precipitated serum samples after the addition of increasing amounts of gammaglobulin (Flebogamma). (B) IEF of supernatants of cold-precipitated serum samples before () or after () addition of gammaglobulin (5 mg/ml). The monoclonal IgM band (arrow) disappears after the addition of gammaglobulins. Cathode is on the left. (C) Cryoglobulin deposition in 0.5 ml samples of either undiluted serum (1) or serum diluted with PBS (3,5,7) or Flebogamma (2,4,6). The amounts () of either serum, Flebogamma or PBS added to each tube are indicated (C, bottom). A strong increment is found in samples diluted with the Flebogamma preparation in comparison with those diluted with PBS only. C, inset) A sample of serum from a different patient was treated identically. In this case, the addition of gammaglobulin prevented the formation of cryoprecipitate (2).

decided to start IVIG as an alternative treatment. The patient presented with normal haematological parameters and the serum concentration of IgG was 161 mg/dL, IgM 286 mg/dL, and IgA 44 mg/dL. Cryocrit was 6%. Twenty grams of a gammaglobulin preparation (Flebogamma, Instituto Grifols, Barcelona) was administered i.v. over 2 hrs. One hour after the infusion, the patient complained of severe chest pain with shortness of breath. Over the following 4 hours, she developed a dramatic purpuric rash affecting the thorax and both upper and lower extremities, with generalised oedema, thoracic and abdominal pain and diarrhoea that required hospital admission. A cutaneous biopsy revealed the presence of leukocytoclastic vasculitis. Chest X-ray, ECG, urinary parameters and plasma BUN and creatinine were all normal. Intensive

plasmapheresis and administration of corticosteroid pulses produced an improvement of the clinical symptoms. Meanwhile, we noted a huge precipitate in a plasmapheresis bag that was kept in the refrigerator for further analysis. A sample of it revealed a cryocrit of 85%. One week later, the cryocrit was 7% and the concentrations of serum immunoglobulins were IgG 252 mg/dL, IgM 29 mg/dL and IgA 18 mg/dL. Over the next 12 months, the serum IgG concentration varied between 70 and 160 mg/dL, whereas the IgM concentration and cryocrit levels rose steadily, reaching 2-3000 mg/dL and 30-60%, respectively. A monoclonal IgM kappa peak remained in the supernatant after cryoprecipitation. At present, the patient remains asymptomatic on low dose prednisone.

In order to understand the reason for

our patient's severe reaction to gammaglobulin administration, we decided to study the behaviour of the patient's cryoglobulin when exogenous gammaglobulin was added *in vitro*. The patient's blood was kept at 37°C during clotting and centrifugation. Different volumes of the gammaglobulin preparation used for the IVIG were added to the patient's serum for a final volume of 0.5 ml. Equivalent volumes of PBS were added as a control. The preparations were cooled at 4°C for 48 hours before the cryocrit determination. Quantitative analysis of the serum proteins was performed by nephelometry in a Beckman Immunochemistry System. Immuno-electrophoresis (IEF) was evaluated on Kallestad plates.

The addition of increasing increments of gammaglobulin resulted in a concomitant decrease in the concentration

of the IgM remaining in the supernatant after cryoprecipitation (Fig. 1A). IEF of the cryoglobulin-free serum revealed that the monoclonal IgM kappa arch disappeared in samples containing exogenous gammaglobulin (Fig. 1B). Cryoprecipitates of undiluted serum and serum diluted either with PBS or with a preparation of gammaglobulins are depicted in Figure 1C. The cryocrit value for undiluted serum was 40% (tube 1). Dilution of the serum with increasing amounts of PBS resulted in cryocrit values of 30%, 20% and 12% (tubes 3, 5, and 7). The dilution of the serum with equivalent volumes of gammaglobulin (tubes 2, 4, and 6) resulted in a marked increment in the cryocrit levels: 30% 56%, 20% 52% and 12% 46%, respectively. The final concentrations of gammaglobulins were: 2.5 mg/mL (tube 2), 5 mg/mL (tube 4) and 10 mg/mL (tube 6). Theoretically, the concentration of exogenous gammaglobulin in the patient's serum after IVIG should reach around 4 mg/mL. As an example of a different outcome, we treated identically the serum of another patient with a similar type II cryoglobulinemia. In this case, the addition of gammaglobulin prevented the formation of cryoprecipitate (see inset, tube 2 in Fig. 1C).

Discussion

Administration of IVIG is used in patients with certain autoimmune or systemic conditions (7-9). Although the treatment is generally regarded as safe, serious adverse reactions have also been reported (10-12). Controversial reports exist regarding the effect of the infusion of gammaglobulins in patients with type II cryoglobulinemia. Potential causes of poor outcome include changes in cryoprecipitability or increases in serum viscosity (4, 12). A patient with a low-grade lymphoma producing a monoclonal IgM rheumatoid factor received IV gammaglobulin as therapy for pulmonary infection (3). Renal failure attributed to deposits of newly formed immunocomplexes resulted in the death of the patient. In a second case of type II cryoglobulin associated with lymphoma reported by

Wooten *et al.* (4), recurrent infections required IV gammaglobulin therapy. A progressive change in cryoglobulin solubility was thought to be the cause of fatal vasculitis and glomerulonephritis. In these previous two cases where IVIG had deleterious effects, the patients also had concomitant hypogammaglobulinemia. Recently, Odum *et al.* (6) reported a patient with Guillain-Barre syndrome who developed cutaneous vasculitis, thrombocytopenia and glomerulonephritis following IVIG therapy. This patient was lately found to have NHL and type II cryoglobulin. The authors warn of the potential danger of giving such patients IVIG therapy. A fourth patient with type II cryoglobulinemia and cutaneous vasculitis showed a good clinical response after IVIG (5). In this case, the beneficial effect was attributed to a decrease in the amount of cryoprecipitate following gammaglobulin infusion.

The data reported herein seem to indicate that the addition of IgG to the patient's serum results in the displacement of the immunoprecipitation reaction towards a new state in which the monoclonal IgM component is incorporated into the cryoprecipitate. If the initial sample is properly located in the antibody (IgM) excess side of the curve of precipitation, the addition of antigen (IgG) would induce a shift in the equilibrium towards the equivalence point, with the appearance of higher amounts of precipitate. A similar mechanism could take place *in vivo* after the infusion of gammaglobulin. This may explain the dramatic increase in cryoprecipitate deposition found in the patient's plasma and the severe side effects observed after therapy. The composition of the Ag-Ab complex in other cryoglobulins can be located near the equivalence point. In these cases, the addition of antigen would result in smaller amounts of cryoprecipitate or even the absence of it, as illustrated by the example given in Fig 1 (inset C).

We think that before the implementation of IVIG in patients with type II cryoglobulinemia and low serum IgG concentration, the induction of cryoprecipitability must be assessed by *in*

vitro studies using exogenous addition of IgG. Findings such as those described in this report must be taken as a contraindication in the use of that therapy. Alternatively, we suggest that for such patients apheresis therapy should be considered before initiating IVIG.

Acknowledgements

We thank María V. Pérez for her excellent technical assistance.

References

1. TAVONI A, MOSCA M, FERRI C *et al.*: Guidelines for the management of essential mixed cryoglobulinemia. *Clin Exp Rheumatol* 1995; 13 (Suppl. 13): S191-S195.
2. MISIANI R, BELLAVISTA P, FENILI B *et al.*: Interferon alpha-2a therapy in cryoglobulinemia associated with hepatitis C virus. *N Engl J Med* 1994; 330: 751-6.
3. BARTON JC, HERRERA GA, GALLA JH, BERTOLI LF, WORK J, KOOPMAN WJ: Acute cryoglobulinemic renal failure after intravenous infusion of gammaglobulin. *Am J Med* 1987; 82: 624-9.
4. WOOTEN MD, JASIN HE: Mixed cryoglobulinemia and vasculitis: A novel pathogenic mechanism. *J Rheumatol* 1996; 23: 12278-281.
5. BOOM BW, BRAND A, BOWES BAVINK J-N, EERNISSE JG, DAHA MR, VERMEER V-J: Severe leukocytoclastic vasculitis of the skin in a patient with essential mixed cryoglobulinemia treated with high dose -globulin intravenously. *Arch Dermatol* 1988; 124: 1550-3.
6. ODUM J, D'COSTA D, FREETH M, TAYLOR D, SMITH N, MACWHANNELL A: Cryoglobulinemic vasculitis caused by intravenous immunoglobulin treatment. *Nephrol Dial Transplant* 2001; 16: 403-6.
7. BARRON KS, SHER MR, SILVERMAN ED: Intravenous immunoglobulin therapy: Magic or black magic. *J Rheumatol* 1992; 19 (Suppl. 33): 94-7.
8. JORDAN SC, TOYODA M: Treatment of autoimmune disease and systemic vasculitis with pooled human intravenous immune globulin. *Clin Exp Immunol* 1994; 97 (Suppl. 1): 31-38.
9. BAHADORAN PH, DE BANDT M, ECHARD M, JARROUSSE B, GUILLEVIN L: Echec des immunoglobulines intraveineuses au cours de certaines maladies systémiques. 5 observations. *Presse Med* 1993; 22: 1175-8.
10. DUHEM C, DICATO MA, RIES F: Side-effects of intravenous immune globulins. *Clin Exp Immunol* 1994; 97: 79-83.
11. HASHKES PJ, LOVELL DJ: Vasculitis in systemic lupus erythematosus following intravenous immunoglobulin therapy. *Clin Exp Rheumatol* 1996; 14: 673-5.
12. DALAKAS MC: High-dose intravenous immunoglobulin and serum viscosity: Risk of precipitating thromboembolic events. *Neurology* 1994; 44: 223-6.