

Hypergammaglobulinemic purpura of Waldenström: Report of 3 cases with a short review

A.N. Malaviya, P. Kaushik,
S. Budhiraja, M. Al-Mutairi,
M.R.N. Nampoory,
A. Hussein, A.O. Akanji

Department of Medicine, Faculty of Medicine, Kuwait University, and Department of Medicine, Mubarak Al-Kabeer Hospital, Ministry of Health, Kuwait

A.N. Malaviya, Professor of Medicine, Department of Medicine, Faculty of Medicine, Kuwait University; P. Kaushik, Senior Registrar in Medicine (Rheumatology); S. Budhiraja, Senior Registrar; Moudi Al-Mutairi, Senior Registrar in Medicine (Rheumatology); M.R.N. Nampoory, Consultant Nephrologist; Aisha Hussein, Senior Technologist, Biochemistry Division; A.O. Akanji, Associate Professor, Department of Pathology, Faculty of Medicine, Kuwait University, and Consultant Biochemist, Mubarak Al-Kabeer Hospital, Ministry of Health.

Please address correspondence and reprint requests to: Prof. A.N. Malaviya, Department of Medicine, Faculty of Medicine, P.O. Box 24923, Safat, Kuwait Code 13110. E-mail: anand@hsc.kuniv.edu.kw

© Copyright CLINICAL AND EXPERIMENTAL RHEUMATOLOGY 2000.

Key words: Purpura, hypergammaglobulinemic purpura of Waldenström, vasculitis.

ABSTRACT

Benign hypergammaglobulinemic purpura of Waldenström (HGPW) is an uncommon cause of non-thrombocytopenic purpura that may create diagnostic difficulties. The presence of constitutional symptoms associated with prominent immunological abnormalities may raise alarm, leading to extensive and often unnecessary investigations. This report describes 3 young women with HGPW. Clinical features were characterised by recurrent episodes of bilateral asymmetrical palpable purpuric lesions on the lower extremities that were precipitated by a prolonged increase in hydrostatic pressure (e.g. prolonged standing, tight stockings etc.) associated with constitutional features. In one patient the condition was secondary to Sjögren's syndrome with type IV renal tubular acidosis. Laboratory abnormalities included a persistently elevated erythrocyte sedimentation rate, marked polyclonal hypergammaglobulinemia, and high titers of rheumatoid factor and anti-nuclear antibody of the anti-SSA(anti-Ro)/anti-SSB(anti-La) subsets. This topic is reviewed briefly with the emphasis that in its 'primary' form this condition could be considered a 'benign' systemic immunoinflammatory disease that requires neither extensive investigations nor any aggressive form of therapy. Greater awareness of HGPW may increase the frequency of its diagnosis, especially in the patient group with non-thrombocytopenic purpura or the so-called cutaneous vasculitic syndromes with 'palpable purpura'.

Introduction

Hypergammaglobulinemic purpura of Waldenström (HGPW) is an unusual immune complex disorder that is one of the uncommon causes of non-thrombocytopenic purpura (1). On the basis of clinical, serologic, and immunogenetic features, it seems to be a clearly distinguishable entity among the systemic immunoinflammatory conditions, more specifically the cutaneous vasculitic syndromes (2). This report describes 3 cases of HGPW with a brief review of the condition. To the best of our knowledge this is the first report of this syndrome from the Gulf region.

Case 1

A 41 year-old Pakistani woman presented with a 15-year history of waxing and waning purpuric lesions on both lower legs and occasionally on the buttocks. These were related to posture and appeared after prolonged standing or the wearing of tight stockings. The lesions would last for 3-4 days and recur every 2-4 months. Occasionally nonspecific body aches and pains were also noted. In recent times the lesions had started to itch. There was no history of photosensitivity, alopecia, oral ulcers, Raynaud's phenomenon, dry eyes or mouth, parotid swelling, thyroid disease, or neurological problems. The past social and personal history was non-contributory. In the family, her mother and two maternal cousins were bed-bound with rheumatoid arthritis.

On examination, there were multiple palpable purpuric lesions ranging in size from pinhead to several millimeters, bilaterally but asymmetrically distributed on the thighs, the legs and dorsa of both feet (Fig. 1, a-b). The rest of the systemic examination was normal.

The results of the laboratory investigations are given in Table I. Complete blood counts, blood urea nitrogen, serum creatinine, serum lipids, platelet functions, thyroid function and thyroid auto-antibodies, and Coombs' test, hepatitis B and C screening tests were normal/negative. Serum electrophoresis with immunofixation showed a polyclonal increase in gamma globulins mainly in the IgG and IgA fractions (Fig. 2, a-b). Chest radiograph, abdominal ultrasonogram, electrocardiogram, echocardiogram, an eye examination and the Schirmer's test were within normal limits.

With the diagnosis of HGPW she was prescribed hydroxychloroquine 400 mg orally daily for 4 months followed by 200 mg daily. Due to the only partial improvement in her condition, colchicine 0.5 mg twice per day was added to her treatment. Over the next one-year period the frequency and distribution of the skin lesions decreased. However, after another period of 9 months follow-up she developed acute uveitis requiring 60 mg prednisolone daily for 6 weeks with complete recovery of the eyes. This short course of high-dose prednisolone led to

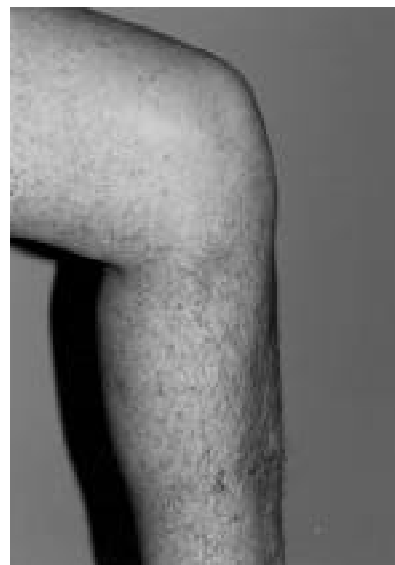
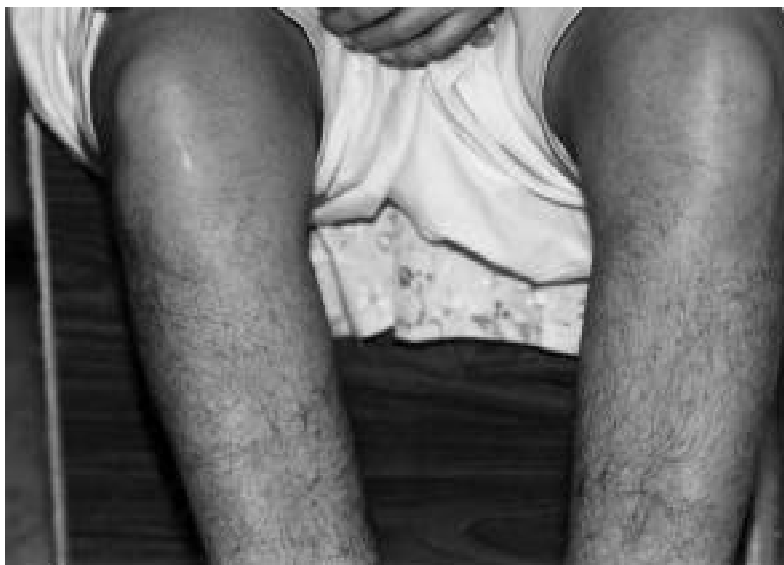
Fig. 1. Bilateral asymmetrical purpuric lesions on the lower extremities; some were palpable.

marked improvement in the purpuric symptoms. After 6 weeks the dose of prednisolone was reduced to 60 mg once every week.

After 1 month of reverting to the weekly dose of prednisolone, she started to notice the reappearance of the skin lesions on prolonged standing. Also, the repeat laboratory parameters showed similar abnormalities to those seen at the first visit (Table I). She was last seen in the first week of February 2000. She was advised to discontinue colchicine, continue hydroxychloroquine and to start taking 7.5 mg of methotrexate orally once every week with 5 mg of folic acid every other day.

Case 2

A 14-year-old Egyptian girl was seen by the paediatric service for the first time in early 1993, with a one-year history of recurrent purpura on the legs, pain and swelling in both knees and edema of both legs of 6 months duration. Complete blood counts, blood urea nitrogen, serum creatinine, serum lipids, and screening for hepatitis B and C were normal/negative. Other relevant investigation results are given in Table I. With the diagnosis of 'vasculitis' she was treated with corticosteroids and azathioprine with relief of the symptoms. The patient was non-compliant to drug treatment and did not keep follow-up appointments. Nine months later she was readmitted with cramps in the legs followed by the

sudden development of flaccid quadri-paresis. A systematic review was negative with no symptoms suggestive of dry eyes or dry mouth. However, several attacks of purpuric skin lesions on the legs had been noted since her last visit to the hospital. There was a history of otitis media and increased dental caries. On examination the patient had flaccid paraparesis of all 4 limbs. Follow-up investigations are given in Table I. Additional investigations showed serum potassium 1.9 mmol/L, chloride 117 mmol/L, bicarbonate 13 mmol/L, urine pH (repeatedly) >7, and arterial blood pH 7.26. Serum electrophoresis and immunofixation showed a polyclonal hypergammaglobulinemia (gamma globulins 42 gm/L with increased IgG, IgA and IgM). Eye examination showed reduced visual acuity with unstable tear film and exposure keratitis. Schirmer's test showed mild dryness in the eyes with readings of less than 10 mm in both eyes. Lip biopsy for minor salivary glands yielded insufficient tissue. Parotid scan was inconclusive. Renal biopsy showed interstitial nephritis. A diagnosis of primary Sjögren's syndrome (SS) with type IV renal tubular acidosis (distal RTA) associated with hypokalemia and secondary HGPW was made.

The patient was treated with potassium supplementation, azathioprine and prednisolone. The recovery from flaccid paralysis was dramatic. However, the recurrent attacks of purpuric skin lesions

on the legs persisted. In 1995 azathioprine was replaced by hydroxychloroquine. Throughout her illness the patient has been living in Egypt and visited Kuwait infrequently for medical advice. In recent years she has had frequent hospital admissions in Egypt with flaccid paraparesis that disappeared on potassium supplementation. She continued to be non-compliant to the treatment. She was last seen in June 1999. Recent follow-up investigations were not available.

Case 3

A 27-year-old Indian woman was referred from another hospital as a 'diagnostic problem with some unusual immunological disease'. The patient had been unwell since June 1998 with vague constitutional symptoms and weight loss. During her diagnostic work-up elsewhere she developed a gluteal abscess. Surgical drainage was followed by a biopsy that was interpreted as 'tuberculosis'. The patient was prescribed anti-tuberculous drugs. However, these medicines could not be continued due to intolerable nausea and vomiting.

The biopsy was reviewed and the diagnosis was revised to nonspecific inflammatory changes. She was advised to undergo symptomatic treatment and was followed in the out-patient clinic. Vague arthralgias, myalgias and general ill health persisted. Further investigations at that hospital showed a persistently negative Mantoux test, high ESR (> 80

Table I. Laboratory investigations in 3 patients with hyperglobulinaemic purpura of Waldenström.

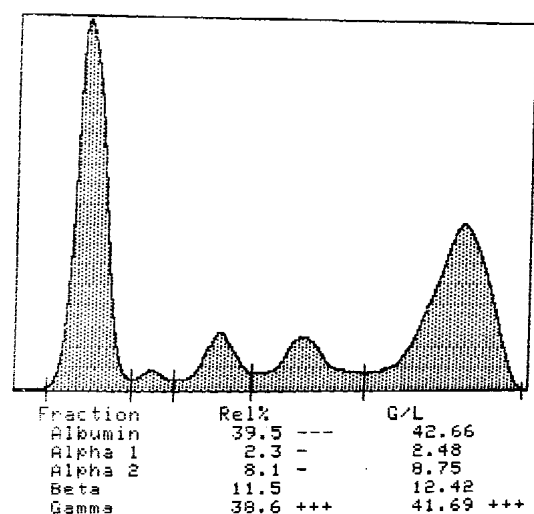
Parameters	Normal range	Patient 1		Patient 2		Patient 3	
		Baseline	21 mo. Follow-up	Baseline	9 mo. Follow-up	Baseline	12 mo. Follow-up
ESR* (mm/1st hr.)	< 30	135#	-	50	48	96	55
Total serum protein (g/l)	63-80	100	91	90	86	94	77
Albumin	35-47	40	34	42	37	33	35
Total globulins (g/l)	28-33	60	57	48	49	61	42
RF* units	< 20 units	1550	-	-	640	1650	nd
ANA* titers	< 1:40	1:40	-	-	1:1280	1:2560	nd
Anti-SSA (Ro) antibody	neg	pos	-	-	pos	pos	-
Anti-SSB (La)	neg	neg	-	-	pos	pos	-
Other anti-ENA*	neg	neg	-	-	neg	pos	-
Anti-DNA*	neg	neg	-	-	neg	neg	-
ANCA*	neg	neg	-	-	neg	nd	neg
C-reactive protein (mg/dL)	0-0.8	< 0.95	-	-	< 0.8	0.40	-
C3/C4 (g/l)	0.5-1.2 / 0.2-0.5	1.42/1.3	-	-	-	0.86/0.29	-
Cryoproteins	neg	neg	-	-	neg	neg	-
Cryofibrinogen	neg	ND	neg	ND	ND	ND	neg

repeatedly > 100 mm/1st hr.

*ESR: erythrocyte sedimentation rate by Westergren's method; WBC: white blood cell count; RF: rheumatoid factors; ANA: anti-nuclear antibody; anti-ENA: antibodies against extractable nuclear antigens; ANCA: anti-neutrophil antibodies by immunofluorescence technique; neg: negative; pos: positive.

**Antiphospholipid antibodies included screening for anti-cardiolipin antibodies, lupus anti-coagulants, and VDRL serological test for syphilis.

Patient: shagufta
 Test: SPE Gel 1 - 3 15-12-98
 Lab # & Hosp# 7134 Strip # 387



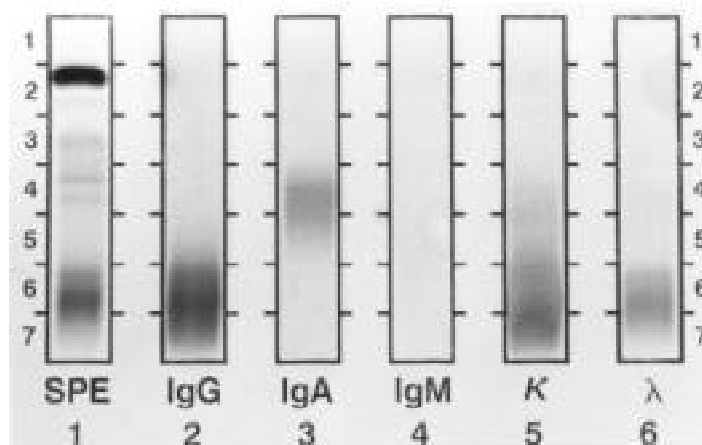
Total G/L 108.00 A/G: 0.65

Comments:

Reference Ranges:

Fraction	Rel%	G/L
Albumin	56.0 - 68.0	32.00 - 50.00
Alpha 1	2.5 - 4.5	1.00 - 4.00
Alpha 2	9.0 - 14.0	6.00 - 10.00
Beta	8.0 - 12.0	6.00 - 13.00
Gamma	10.0 - 18.0	7.00 - 15.00

(a)



(b)

Fig. 2. (a) Serum electrophoresis showing a polyclonal increase in gamma globulins. (b) Immunofixation study on the electrophoresed serum sample; note the staining with both the anti-IgG and the anti-IgA antibodies, confirming the polyclonality of the gamma band.

mm 1st hr), mild anemia (< 110 gm/L), very high total serum globulins (> 60 gm/L), normal albumin (> 30 gm/L), and normal liver and renal parameters. Thyroid parameters were normal. Chest radiograph and abdominal ultrasound studies were also normal. Rheumatoid factor, anti-nuclear antibody, and C-reactive protein were reported as 'positive' without quantitation.

At her first presentation at this institution in early March 1999 the clinical assessment was non-contributory. There was no history of skin rash, oral ulcers, photosensitivity, joint swellings, Raynaud's phenomenon, chest or abdominal symptoms, any type of eye symptoms, or neurological symptoms. The family, past, social and personal histories were non-contributory. Within the first few days of her re-investigations at this institution, she developed a purpuric rash bilaterally on the lower extremities in an asymmetrical distribution, left-sided lesions being the most widespread and numerous. At least a few of the lesions were palpable. Complete blood counts, blood urea nitrogen, serum creatinine, serum lipids and screening for hepatitis B and C were normal/negative. Other relevant investigation results are given in Table I. Serum electrophoresis and immunofixation showed a polyclonal increase in gamma globulins mainly in the IgG and IgA fraction (gamma globulins 52 gm/L). Thyroid function tests, eye examination and a Schirmer's test were normal (> 20 mm wetting).

The diagnosis of primary HGPW was made and the patient was prescribed hydroxychloroquine 400 mg daily. Over the next 3 months she continued to have purpuric lesions on the legs even with trivial exertion. She was then prescribed 80 mg of prednisolone once every week that she was still taking when she was last seen in the last week of January 2000 (total follow-up 11 months). The episodes of purpura had become much less frequent, with some improvement in the laboratory investigations (Table I).

Discussion

In 1943 Waldenström first described a rare, chronic, but benign disorder usually seen in young to middle-aged females characterised by recurrent purpura

(usually on the legs), a polyclonal increase in gammaglobulins, high ESR, mild anaemia, and at times circulating IgG-anti IgG immune complexes (3, 4). Since then this syndrome has been termed HGPW. Because of the palpable purpuric lesions, it is one of the differential diagnoses among the cutaneous vasculitic syndromes, the other conditions being hypersensitivity vasculitis, Henoch-Schönlein's purpura, essential mixed cryoglobulinaemia, hypocomplementaemic vasculitis, vasculitis secondary to collagen vascular diseases, certain infections and malignancies. (5). There is another disease with a similar name, i.e. Waldenström's macroglobulinaemia, a malignancy of the mature IgM-producing plasma cells with which it should not be confused. HGPW may be primary if no associated disease develops within 2 years of onset or secondary to autoimmune diseases such as Sjögren's syndrome, systemic lupus erythematosus, rheumatoid arthritis, polymyositis etc. (6, 7). It may also be associated with Hashimoto's thyroiditis, sarcoidosis, diabetes mellitus, cirrhosis of the liver, inflammatory bowel disease, renal tubular acidosis (8) and, rarely, with some infections and neoplasms. However, associated diseases may occasionally develop up to 10 or more years after the onset of HGPW, and cannot ever be completely excluded (9).

The clinical features include recurrent attacks of sudden onset purpura that may last up to 7 days, and may recur as often as 3 times a week or as infrequently as once a year. These lesions show a fairly constant pattern in a given patient and can be precipitated by a sustained increase in hydrostatic pressure (e.g., prolonged standing, walking, tight-fitting garments, and heat). They are bilateral but asymmetry is usually prominent. Systemic manifestations may occur in the form of arthralgias (often adjacent to areas of purpura), fever, malaise, weight loss, serositis and, rarely, renal involvement. Common laboratory abnormalities include mild hypochromic anemia, mild leukopenia, and pronouncedly elevated ESR contrasting towards normal plasma reactants believed to be secondary to the increase in immunoglobulins (10, 11). Rheumatoid factor is almost always pre-

sent in high titers and very commonly anti-nuclear antibodies towards Ro/SSA are present. A polyclonal increase in gamma globulins is mainly due to increased IgG and IgA (rarely IgM) fractions (5). Cryoglobulins are usually absent (12).

All 3 patients presented in this report showed the characteristic clinical and laboratory features described above. All of them had bilateral but prominently asymmetrical lower extremity non-thrombocytopenic purpura, high levels of polyclonal gammaglobulins, a diffuse increase in the levels of immunoglobulins G and A, high titers of RF and a positive ANA of the anti-Ro/anti-La subtypes. Patient 1 did not develop features of any other autoimmune disease over a period of 15 years. Thus, she could be definitely labelled as 'primary' HGPW. Case 2 had features of Sjögren's syndrome with type IV RTA associated with features of HGPW. She would be classified as HGPW 'secondary' to SS. Case 3 had symptoms of the disease for about 1 year. Although she had no features of any other underlying autoimmune disease, the follow-up is too short to label her as 'primary' HGPW. Only time will tell whether she will evolve features of SS or some other systemic autoimmune disease.

The exact pathogenesis of this condition is unknown. The characteristic histopathology of HGPW is that of neutrophilic inflammation in and around small blood vessels (venules) with leukocytoclasia (13). Immunofluorescence often shows C3 deposits and, less commonly, immunoglobulins (IgG and IgM) (14). Hence it may be a Type III hypersensitivity disease of the small blood vessels. IgG2 deficiency has been reported in some cases (15). The significance of ANA of anti-Ro/SSA specificity is its association with SS, the kidneys are often involved and distal renal tubular acidosis may develop. Of note is that anti-Ro/SSA antibodies are prevalent even in the primary form of HGPW (16). There is a subset of SS that is more prone to HGPW, especially if HLA DR3 is associated with it. Hence screening for anti-Ro/SSA antibodies has been considered important in the diagnosis of HGPW, as it is helpful in predicting the prognosis (17).

HGPW is an uncommon condition. Therefore, controlled trials are not available and there is no consensus on the treatment of this disease. In milder disease hydroxychloroquine and indomethacin, as well as colchicine, have been reported to be effective; however, for severe disease short courses of prednisolone (30 mg per day) are recommended (18).

Acknowledgement

The help provided by the Medical Illustration Unit of the Faculty of Medicine is gratefully acknowledged.

References

1. PINES A, BEN-BASSAT I: Waldenström's hypergammaglobulinemic purpura: An unusual immune complex disorder. *Clin Rheumatol* 1984; 3: 263-6.
2. INVERNIZZI F, CATTANEO R, FENINI MG *et al.*: Hypergammaglobulinemic purpura of Waldenström. (A report of serologic and immunogenetic studies and long-term follow-up in 18 patients). *Ric Clin Lab* 1988; 18: 23-6.
3. WALDENSTRÖM J: Clinical methods for the determination of hyperproteinemia and their practical value for diagnosis. *Nord Med* 1943; 20: 2288-95.
4. LOPEZ LR, SCHOCKET AL, CARR RI, KOHLER PF: Lymphocytotoxic antibodies and intermediate immune complexes in hypergammaglobulinemic purpura of Waldenström. *Ann Allergy* 1988; 61: 93-6.
5. COLLIER BS, SCHNEIDERMAN P: Clinical evaluation of hemorrhagic disorders: The bleeding history and differential diagnosis of purpura. In: HOFFMAN R, BENZ EJ, SHATTIL SJ, FURIER B and COHEN HJ (Eds.): *Hematology. Basic Principles and Practice*. 1st ed. New York, Churchill Livingstone, 1991: 1252-66.
6. KYLE RA, GLEICH GJ, BAYRD ED, VAUGHAM JH: Benign hypergammaglobulinemic purpura of Waldenström. *Medicine (Baltimore)* 1971; 50: 113-23.
7. FERREIRO JE, PASARIN G, QUESADA R, GOULD E: Benign hypergammaglobulinemic purpura of Waldenström associated with Sjögren's syndrome. Case report and review of immunological aspects. *Am J Med* 1986; 81: 734-40.
8. GROGGER GC, BORDER WA, WESTENFELDER C: The kidney in hypergammaglobulinemic purpura. *Am J Kidney Dis* 1987; 9: 172-5.
9. ZAHARIA L, HILL JM, LOEB E, MACLELLAN A, KHAN A, HILL NO: Systemic lupus erythematosus in twin sisters following ten years of hypergammaglobulinemic purpura (Waldenström). *Acta Med Scand* 1976; 199: 429-32.
10. CARR RD, HEISEL EB: Purpura hyperglobulinemia. *Arch Dermatol* 1966; 94: 536-41.
11. FINDER KA, MCCOLLOUGH ML, DIXON SL, MAJKA AJ, JAREMKO W: Hypergammaglobulinemic purpura of Waldenström. *J Am Acad Dermatol* 1990; 23: 669-76.
12. WINFIELD JB: Cryoglobulinemia. *Hum Pathol* 1983; 14: 350-4.
13. PERKS WH, GREEN F, GLEESON MH: A case of purpura hypergammaglobulinemia of Waldenström studied by skin immunofluorescence. *Br J Dermatol* 1974; 95: 563-8.
14. OLMSTEAD AD, ZONE JJ, LASALLE B, KRUEGER GG: Immune complexes in the pathogenesis of hypergammaglobulinemic purpura. *J Am Acad Dermatol* 1980; 3: 174-9.
15. ERIKSSON P, ALMROTH G, DENNEBERG T, LINDSTROM FD: IgG2 deficiency in primary Sjögren's syndrome and hypergammaglobulinemic purpura. *Clin Immunol Immunopathol* 1994; 70: 60-5.
16. HABIB GS, STIMMER MM, QUISMORIO FP JR: Hypergammaglobulinemic purpura of Waldenström associated with systemic lupus erythematosus: Report of a case and review of literature. *Lupus* 1995; 4: 19-22.
17. MIYAGAWA S, FUKUMOTO T, KANAUCHI M *et al.*: Hypergammaglobulinemic purpura of Waldenström and Ro/SSA antibodies. *Br J Dermatol* 1996; 134: 919-23.
18. SENECAJL, CHARTIER S, ROTHFIELD N: Hypergammaglobulinemic purpura in systemic autoimmune rheumatic diseases: predictive value of anti-Ro(SSA) and anti-La(SSB) antibodies and treatment with indomethacin and hydroxychloroquine. *J Rheumatol* 1995; 22: 868-75.