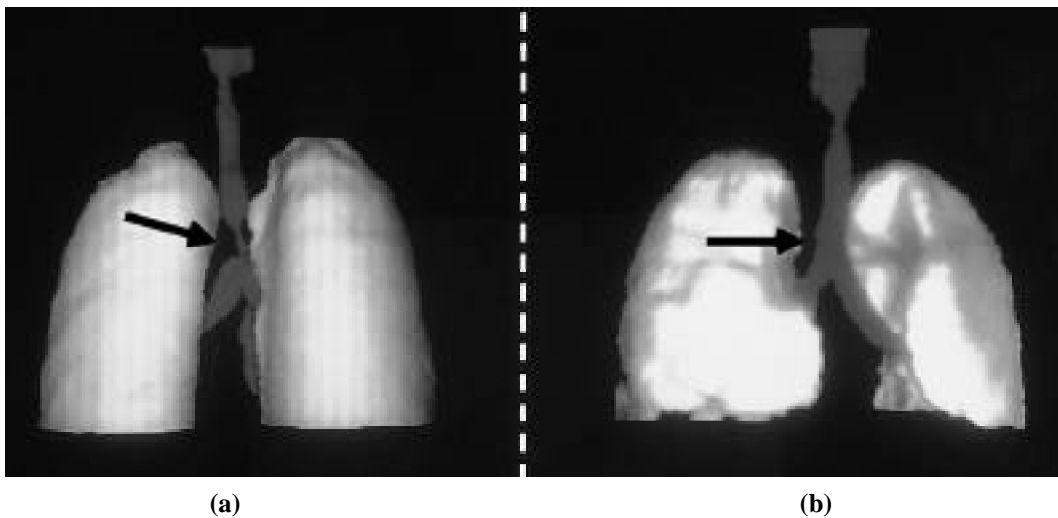

Clinical vignette

Systemic lupus erythematosus and tracheal stenosis



A 45-year-old woman with an 18-year history of systemic lupus erythematosus and Sjögren's syndrome was intubated because of cerebral hemorrhage of the right parietal lobe, pneumonia and acute respiratory distress syndrome.

Five months later she was re-admitted because of stridor. Spiral reconstruction computerized tomography showed stenosis of the trachea at 9.5 cm downwards from the vocal cords (**Fig. 1a**). The patient was operated on and end-to-end anastomosis was performed. Tomography one week after surgery confirmed that the anastomosis was successful (**Fig. 1b**).

Tracheal stenosis in systemic lupus erythematosus can be either post-traumatic or due to an autoimmune inflammatory process such as relapsing polychondritis. Histological examination of the removed tracheal portion revealed ulcerative inflammation and fibrosis compatible with post-traumatic damage.

A. ZERA¹, MD

T. DOSIOS², MD, FACS

H.M. MOUTSOPOULOS¹, MD, FACP, FRCP (Ed)

Department of Pathophysiology¹ and

2nd Department of Propedeutic Surgery²,

Division of Thoracic Surgery, National University,

Athens 115 27, Greece.