

Pernicious anemia in a patient with giant cell arteritis in long-term remission

Sir,

The association between giant cell (temporal) arteritis (GCA) and other autoimmune diseases such as autoimmune thyroiditis (1-5), primary biliary cirrhosis (6), Sjögren syndrome (7), systemic lupus erythematosus (1, 8) and progressive systemic sclerosis (9) has occasionally been reported. Although the association of GCA with most of these disorders is essentially anecdotal, it provides additional support for the concept that immune mechanisms play a role in the pathogenesis of GCA. Among the associated autoimmune disorders, it appears to be clear that thyroiditis is more prevalent among patients with GCA than in the general population.

Since the initial description by Fauchald *et al.* in 1972 of the development of autoimmune thyroiditis in a patient with GCA (1), several additional cases have been reported. In a series of 59 patients with GCA the prevalence of thyrotoxicosis was 8.5% and hypothyroidism 3.4%, while in the control population it was 1.5% and 2%, respectively (3). Recent studies have also demonstrated a remarkable prevalence of anti-thyroid antibodies and hypothyroidism among patients with GCA or polymyalgia rheumatica (4, 5). In this report we describe a patient who developed pernicious anemia ten years after the diagnosis of GCA.

An 88-year-old woman was admitted because of progressive fatigue and pallor over the past 4 months. Ten years earlier, because of a clinical picture encompassing headache, jaw claudication and a high sedimentation rate, she underwent a left temporal artery biopsy which showed classical GCA. She received corticosteroid treatment for 2 years and her clinical course was uneventful with no relapses. Her past medical history also included mild hypertension and mild non-insulin dependent diabetes mellitus, while 7 months before admission she had a transient cerebral ischemic attack with full recovery.

Her physical examination was unremarkable except for an intense pallor and weakly pulsatile temporal arteries. Hematologic laboratory values disclosed hemoglobin 58 gr/L, hematocrit 17%, MCV 137 fL, and reticulocytes $28 \times 10^9/L$. Blood chemistry determinations revealed an ESR of 16 mm, lactate dehydrogenase 508 IU/L, total bilirubin 2.4 mg/dL and unconjugated bilirubin 1.6 mg/dL. Folic acid levels were normal, and the cobalamin quantitation was below a 50 pg/

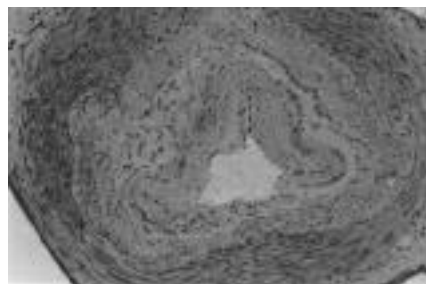


Fig. 1. Irregular intimal hyperplasia, fragmented elastic lamina and scarce small inflammatory foci.

ml detection threshold (NV: 200 - 1000 pg/ml). A Schilling's test confirmed the diagnosis of pernicious anemia. Anti-parietal cell antibodies were positive at a 1/50 dilution. Antinuclear antibodies and anti-thyroid antibodies were negative. An endoscopic gastric biopsy disclosed atrophic gastritis. A right temporal artery biopsy showed irregular intimal hyperplasia, a fragmented elastic lamina and scattered small foci of inflammatory cells consistent with a healing GCA pattern (10) (Fig. 1). She was treated with intramuscular B₁₂ vitamin with good recovery.

In older published series the finding of pernicious anemia in GCA patients has been reported as an exceptional occurrence (1, 2). Given the high prevalence of autoimmune thyroid diseases found by several authors among patients with GCA (3-5), however, and given the well-known association between autoimmune thyroid diseases and pernicious anemia (11), one might expect a higher incidence of pernicious anemia among GCA patients. Our patient developed pernicious anemia 10 years after the diagnosis of GCA, when the latter was in remission and a second temporal artery biopsy showed a healing GCA pattern. GCA patients must be subjected to a long-term follow-up, not only because of the tendency of GCA to relapse and the possibility of late complications (12), but also because of the potential development of additional immune-mediated disorders.

J. HERNÁNDEZ-RODRÍGUEZ, MD
E. AGUILERA, MD
J.M. GRAU, MD
F. CARDELLACH, MD
M.C. CID, MD

Department of Internal Medicine, Institut d'Investigacions Biomèdiques August Pi i Sunyer, Hospital Clínic, Facultat de Medicina, University of Barcelona, Barcelona, Spain.

Address correspondence and reprint requests to: Maria C. Cid, Department of Internal Medicine, Hospital Clínic, Villarroel 170, 08036 Barcelona, Spain.

References

1. FAUCHALD P, RYGVOLD O, OYSTESE B:

Temporal arteritis and polymyalgia rheumatica. *Ann Intern Med* 1972; 77: 845-52.

2. KLEIN RG, HUNTER GG, STANSON AW: Large artery involvement in giant cell (temporal) arteritis. *Ann Intern Med* 1975; 83: 806-12.
3. THOMAS RD, CROFT DN: Thyrotoxicosis and giant-cell arteritis. *Brit Med J* 1974; 2: 408-9.
4. HOW J, BEWSHER PD, WALKER W: Giant-cell arteritis and hypothyroidism. *Br Med J* 1977; 2: 99.
5. BOWNES P, SHOTLIFF K, MIDDLEMISS A, MYLES AB: Prevalence of hypothyroidism in patients with polymyalgia rheumatica and giant cell arteritis. *Br J Rheumatol* 1991; 30: 349-51.
6. GAGNERIE F, TAILLAN B, EULLER-ZIEGLER L, ZIEGLER G: Primary biliary cirrhosis, temporal arteritis (giant cell arteritis) and polymyalgia rheumatica in a single patient. *Scand J Rheumatol* 1988; 17: 231-2.
7. SEMBLE EL, AGUDELO CA, CHALLA VR, HEISE ER, PISKO EJ: Temporal arteritis in Sjögren's syndrome. *Clin Exp Rheumatol* 1985; 3: 345-7.
8. BUNKER CB, DOWD PM: Giant cell arteritis and systemic lupus erythematosus. *Br J Dermatol* 1988; 119: 115-20.
9. HUPP SL: Giant cell arteritis associated with progressive systemic sclerosis. *J Clin Neuroophthalmol* 1989; 9: 126-30.
10. ALLSOP CJ, GALLAGHER PJ: Temporal artery biopsy in giant cell arteritis. A reappraisal. *Am J Surg Pathol* 1981; 5: 317-23.
11. HEYMANS G, LUSTMAN F: Diabete et pathologies immunitaires. *Acta Clin Belg* 1971; 26: 380-7.
12. EVANS JM, BOWLES CA, BJÖRNSSON J, MULLANY CJ, HUNTER GG: Thoracic aortic aneurysm and rupture in giant-cell arteritis: A descriptive study of 41 cases. *Arthritis Rheum* 1994; 37: 1539-47.

"Pray sign" and giant cell arteritis

Sir,

Physician awareness has contributed to the progressive increase in the incidence of giant cell arteritis (GCA) in different populations (1-4). A detailed clinical history and careful physical examinations are of capital importance in the search for clues to support a diagnosis of GCA in the elderly. Indeed, a rapid diagnosis and early treatment may be useful in preventing ominous complications of the disease (5, 6). Cranial manifestations such as headache or jaw claudication are the most commonly reported features of GCA (1). In general, patients with GCA and jaw claudication notice this symptom on chewing, especially when they are eating solid food. Characteristically jaw claudication improves after stopping mastication.

We recently reported a patient presenting with jaw claudication along with spontaneous facial pain that improved after corticosteroid