

Spinal cord involvement in pediatric systemic lupus erythematosus: Case report and literature review

S.M. Al-Mayouf, S. Bahabri

Department of Pediatrics, King Faisal Specialist Hospital and Research Center, Riyadh, Saudi Arabia.

Sulaiman M. Al-Mayouf, MD;
Sultan Bahabri, MD.

Please address correspondence and reprint requests to: Dr. Sulaiman M. Al-Mayouf, Consultant, Rheumatology Section, Department of Pediatrics (MBC 58), King Faisal Specialist Hospital and Research Center, P.O. Box 3354, Riyadh 11211, Saudi Arabia.

Received on January 19, 1999; accepted in revised form on March 24, 1999.

© Copyright CLINICAL AND EXPERIMENTAL RHEUMATOLOGY 1999.

Key words:

Systemic lupus erythematosus, discoid lupus, spinal cord, cyclophosphamide, transverse myelitis.

ABSTRACT

Transverse myelitis is a rare but serious complication of systemic lupus erythematosus (SLE). We describe the youngest patient with transverse myelitis ever recorded in SLE. Clinical improvement was observed after prednisone and cyclophosphamide therapy. The English language literature from 1966 to the present on the subject are reviewed.

Introduction

Systemic lupus erythematosus (SLE) is a chronic inflammatory disorder of unknown etiology, characterized by multi-system involvement. Neuropsychiatric lupus (NPL) has been reported to occur in 13-45% of pediatric SLE patients (1, 2). NPL has a wide spectrum of clinical presentations including seizures, organic brain syndrome and psychosis (3, 4). Transverse myelitis is a rare manifestation of SLE, occurring in less than 1% of patients (3, 5). It is rarely associated with pediatric SLE, with only 11 reported cases in the English language literature (1, 6-9, 12, 14-17). We describe the youngest case of transverse myelitis ever recorded in SLE. We emphasize the importance of this complication in the clinical presentation in SLE patients. Our patient also had discoid type lesions and magnetic resonance imaging (MRI) showed the presence of an abnormal signal in the basal ganglia.

Case report

A 3-year-old girl was well until the age of 2 years, when she presented to the local hospital with a progressive oozing, ulcerative rash on her face (mainly on the cheeks), hair loss, intermittent fever, poor appetite and weight loss. She had a history of photosensitivity and mouth ulcers. Over the next few months she developed a disturbed gait, which was rapidly progressive to the point that she was unable to walk or even move her lower limbs. At that time, the facial rash was extensive, involving the scalp, both ears and lips. She had no history of eye involvement, abdominal pain, diarrhea, bleeding tendency, seizure or abnormal movements. She had no history of spinal trauma, joint swelling or a history suggesting Raynaud's phenomenon. She

was not taking antibiotics, namely those containing sulfa components. She was not toilet-trained, so it was difficult to know whether she had sphincter incontinence. She was treated with topical steroid cream and 5 mg prednisolone orally, but the rash persisted with intermittent fever and without any improvement in her ability to walk. The patient was referred to us one year from the onset of her symptoms. Developmental milestones had been normal until the onset of her disease. She had no family history of autoimmune disease.

Physical examination disclosed a weight and height below the 5th percentile (10.7 Kg and 89 cm respectively); the vital signs were normal. She had an extensive, disfiguring, excoriated crusty facial rash with oozing of blood. The rash involved the scalp, cheeks, nasal bridge, lips and ears. She had a similar rash involving the forearms and inguinal areas. She also had alopecia and oral ulcerations. Neurological examination revealed spastic tone, grade III muscle weakness, and brisk tendon reflexes without Babinski sign in the lower limbs. No appreciable sensory loss was noted. The cranial nerves and upper limbs were normal. There was no arthritis.

Laboratory investigations showed a normal total white cell count and differential, low hemoglobin (7.1 g/dL) with a picture of iron deficiency anemia, a erythrocyte sedimentation rate (ESR) of 55 mm/hr, and normal C3 and C4 levels, but low serum total hemolytic complement CH50 230 (345 - 485 μ /ml). C1q component was normal. She had positive antinuclear antibody (ANA) to a dilution of 1:80. Anti-Smith 31 (0-16 EU/ml) and anti-RNP 149 (0-16 EU/ml) were positive, but anti-DNA, anti-RO, and anti-La were negative. The coagulation profile was normal; however, anticardiolipin IgM was mildly elevated 16 (0 - 12.5 MpLu/ml). A urinalysis was normal. A cerebrospinal fluid study was not performed.

A punch biopsy of the skin from the right forearm showed compact hyperkeratosis with follicular plugging and basal cell destruction. Moderate perivascular lymphocytes and plasma cell infiltrates were present. These findings were suggestive of discoid lupus. Magnetic resonance

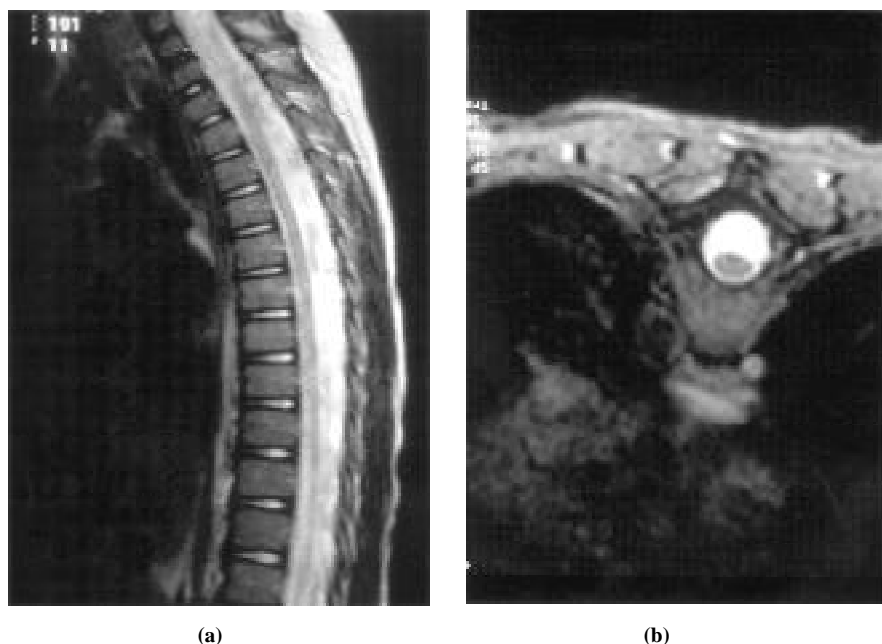


Fig. 1. Sagittal (a) and transverse (b) T2 weighted MRIs showing diffuse atrophy of the thoracic cord.

imaging (MR1) of the brain showed increased signal intensity in the basal ganglia bilaterally suggesting vasculopathy, while the spinal cord MRI showed atrophic changes in the thoracic region with signal abnormalities involving the central areas of the cord (Fig. 1). Based on the skin and nervous system involvement, positive serology (ANA, anti-Smith) and MRI findings, a diagnosis of SLE with transverse myelitis was made. The child was treated with intravenous pulse methylprednisolone (30 mg/Kg/day) for 3 days, and then oral prednisone (1-2 mg/Kg/day) and low dose aspirin (5 mg/Kg/day). She was also started on monthly cyclophosphamide infusions (500 - 750 mg/m²/dose).

Over the next few months her skin lesions showed significant improvement. Neurologically, she recovered the ability to walk unaided with only residual spasticity. However, there were no significant changes in her serology or complement levels.

Discussion

Transverse myelitis is a rare but serious complication of SLE occurring in less than 1% of patients (3). It usually appears late during the course of the illness. However, it may also be seen as an initial manifestation of SLE (9, 10). NPL constitutes the third most common cause of death in lupus patients (11). Trans-

verse myelitis has a poor prognosis with severe morbidity and mortality, especially if there is a delay in diagnosis and treatment (5). The cause of transverse myelitis in SLE is unknown. However, the pathogenesis may include changes related to immune complex-mediated vasculitis causing ischemic necrosis of the spinal cord or an antiphospholipid antibody (APLA)-related mechanism such as coagulopathy complicated by vascular thrombosis or APLA crossreacting with spinal cord phospholipid (3, 9).

Our patient had constitutional symptoms of recurrent fever, malaise and weight loss, alopecia, extensive facial and groin discoid rash, oral ulceration and positive antinuclear antibody (ANA) with elevated anti-Smith antibody. She also had spastic paraparesis due to long-standing transverse myelopathy and bilateral vasculitic changes of the basal ganglia. The transverse myelopathy developed as a late manifestation of her SLE. Although spinal cord MRI showed localized atrophic changes in the thoracic region, she improved on intensive therapy, which suggests an inconsistency between the MRI findings and the outcome.

Transverse myelitis in pediatric SLE is rare, and there is little literature on this complication. We therefore reviewed the medical literature from 1966 to the present for reports of pediatric lupus associated with transverse myelitis and found

a total of 11 cases (Table I). Some of the patients had been included in adult series, with only limited information provided.

All of the pediatric patients, including ours, fulfilled the revised American College of Rheumatology (ACR) criteria for SLE (13). All were female; 9 were teenagers at the onset of their disease. Our patient is the youngest lupus patient with myelopathy to be reported. Of the 12 cases (with only limited information on 2 pts.), 5 presented with myelopathy late (12-72 mos.), and 5 early (2-9 mos.) in the course of their SLE. This pattern is similar to that reported for adult series (9, 15).

Despite the small number of cases reported, pediatric patients seem to be similar to adults in that there is no particular organ involvement associated with the myelopathy (9). The onset of myelopathy is often rapid, occurring within a few hours. All patients presented with sphincter incontinence and flaccid paraplegia; two patients had quadriplegia. Our patient presented with spastic paraparesis due to a delay in the diagnosis. One patient had seizure and organic brain syndrome concomitant with myelopathy. One patient had hemiparesis and cranial nerve involvement 48 months before the onset of myelopathy, while others developed recurrent transverse myelitis. Eight patients underwent cerebrospinal fluid (CSF) analysis, and 5 showed low glucose and high protein levels in their CSF. MRI of the spinal cord was obtained in 4 patients, and abnormal signals and cord swelling or atrophy were evident in 3 of them. MRI in both our patient and others showed basal ganglia abnormalities consistent with vasculitis.

Current tools for the investigation of myelopathy in SLE, including CSF analysis, autoantibody assays, and neuroimaging studies are relatively inconclusive because of the low sensitivity and specificity of these procedures (2,12,18). However, such tests together with the clinical presentation should allow the clinician to confirm the diagnosis of myelopathy and exclude other differential diagnoses, including compressive lesions such as epidural or paraspinal abscesses, hematoma or tumor. The prog-

Table I. Clinical findings and investigations of transverse myelitis in 12 pediatric patients.

| Ref. | Sex | Age | Interval betw. diagnosis of SLE & TM | Clinical findings | Other major organ involvement | Brain/spinal MRI | CSF | Rx | Outcome |
|----------|-----|---------|--------------------------------------|--|---|--|------------------------|----------------------------------|-----------------------------------|
| 1 | F | 9 yrs. | NA | Paraparesis, sphincter incontinence | NA | NA | NA | Prednisone ± Cy | NA |
| 6 | F | 11 yrs. | 5 mos. | Sphincter incontinence, flaccid paraplegia areflexia, sensory loss below T11 | Severe anemia, subarachnoid bleeding | ND | Bloody | Cortisone acetate | Died |
| | F | 12 yrs. | 72 mos. | Flaccid quadriplegia, sensory loss at C6, sphincter incontinence | Nephritis, severe thrombocytopenia | ND | Normal | Prednisone | Residual spasticity and weakness |
| 7 | F | 17 yrs. | NA | Numbness of the legs, sensory loss below C4, Paraplegia, areflexia, incontinence | Polyarthritis nephritis IV | ND | ↓ Glucose ↑ Protein | Prednisone | Died |
| 8 | F | 13 yrs. | 52 mos. | Paraparesis, sphincter incontinence | Chorea, pericardial effusion | ↓ Signal intensity and swelling at T2-6 | Normal | iv MP, Cy | Improved |
| 9 | F | 16 yrs. | 9 mos. | Quadriplegia, sphincter incontinence | Cerebral lupus (with seizure, organic brain syndrome) | Normal spinal cord, bilateral vasculitic hemorrhage of the basal ganglia | ↓ Glucose ↑ Protein | iv MP, Cy | Residual spasticity and weakness |
| 12 | F | 14 yrs. | 36 mos. | Paraplegia, sphincter incontinence | Encephalopathy, panniculitis | ND | ↓ Glucose ↓ C4 | iv MP, AZA | Improved |
| 14 | F | 16 yrs. | 8 mos. | Numbness of the legs, paraplegia, sensory loss below T7, incontinence | Raynaud's phenomenon, polyarthritis | ND | ↓ Glucose ↑ Protein | Prednisone, Cy, plasma exchange | Improved with residual weakness |
| 15 | F | 16 yrs. | 2 mos. | Quadriplegia, incontinence | Cranial nerve involvement, hemiparesis, Raynaud's phen., meningeal syndrome | ND | NA | NA | NA |
| 16 | F | 16 yrs. | 2 mos. | Paraparesis (recurrent) | Arthritis | Multiple cervical cord lesions | NA | Prednisone, AZA, plasma exchange | Residual spasticity, paraparesis |
| 17 | F | 10 yrs. | 48 mos. | Paraparesis, sphincter incontinence | Nephritis, cerebral lupus | ND | ↓ Glucose ↑ Protein | iv MP, Cy | Improved |
| Our case | F | 3 yrs. | 12 mos. | Paraparesis, incontinence | Severe discoid lupus | Vasculitic changes in the basal ganglia, spinal cord necrosis | ND | iv MP, Cy | Improved with residual spasticity |

ND = not done; NA = not available; Cy = cyclophosphamide; iv MP = intravenous methylprednisolone.

nosis of myelopathy is guarded and should be considered as an emergency situation that demands rapid intervention.

Even with the current recommendation of aggressive treatment with intravenous methylprednisolone and immunosuppressive medication (19, 20) the outcome of myelopathy can be variable. Of the 12 pediatric patients reported, 8 had been treated with prednisone and cytotoxic drugs (6 cyclophosphamide, 2 azathioprine). Seven showed improvement (2 recovered fully, while 5 improved with residual spasticity and weakness), while 2 patients who had been treated with steroids alone died.

In conclusion, transverse myelitis is a rare complication of SLE. However, it should be treated early with intravenous methylprednisolone and cyclophosphamide. Patients presenting with myelitis late in their disease course should also be treated aggressively.

References

1. YANCEY C, DOUGHTY R, ATHREYA B: Central nervous system involvement in childhood systemic lupus erythematosus. *Arthritis Rheum* 1981; 24: 1389-95.
2. STEINLIN M, BLASER S, GILDAY D *et al.*: Neurologic manifestations of pediatric systemic lupus erythematosus. *Pediatr Neurol* 1995; 13: 191-7.
3. KAVACS J, UROWITZ M, GLADMAN D: Dilemmas in neuropsychiatric lupus. *Rheum Dis Clin North Am* 1993; 19: 795-814.
4. WEST S: Lupus and the central nervous system. *Curr Opin Rheum* 1996; 8: 408-14.
5. ANDRIAN KOS A, DUFFY J, SUZUKI M, SHARP J: Transverse myelopathy in systemic lupus erythematosus: Report of three cases and review of the literature. *Ann Intern Med* 1975; 83: 616-24.
6. PENN A, ROWN A: Myelopathy in systemic lupus erythematosus. *Arch Neurol* 1968; 18: 337-49.
7. SCHARF I, NAHIR M, HEMLI J: Transverse myelitis with systemic lupus erythematosus. *J Neurol* 1977; 215: 231-2.
8. BACA V, SANCHEZ-VACA G, MARTINEZ-MUNIZ I, RAMIREZ-LACAYO M, LAVALLE C: Successful treatment of transverse myelitis in a child with systemic lupus erythematosus. *Neuro Pediatr* 1996; 27: 42-4.
9. MOK C, LAU C, CHAN E, WOND R: Acute transverse myelopathy in systemic lupus erythematosus: Clinical presentation, treatment and outcome. *J Rheumatol* 1998; 25: 467-73.
10. LOPEZ DUPLA M, KHAMASHTA M, SHANCHEZ A, INGLES F, URIOL P, AGUADO A: Transverse myelitis as a first manifestation of systemic lupus erythematosus: A case report. *Lupus* 1995; 4: 239-42.
11. WHITE P: Pediatric systemic lupus erythematosus and neonatal lupus. *Rheum Dis Clin North Am* 1994; 20: 119-27.
12. WARREN R, KREDICH D: Transverse myelitis and acute central nervous system manifestations of systemic lupus erythematosus. *Arthritis Rheum* 1984; 27: 1058-60.
13. TAN E, COHEN A, FRIES J *et al.*: The 1982 revised criteria for the classification of the systemic lupus erythematosus. *Arthritis Rheum* 1982; 25: 1271-7.
14. PROPPER D, BUCKNALL R: Acute transverse myelopathy complicating SLE. *Ann Rheum Dis* 1989; 48: 512-5.
15. LAVALLE C, PIZARRO S, DRENKEND C: Transverse myelitis: A manifestations of SLE. *J Rheumatol* 1990; 17: 34-7.
16. TOLA M, GRANIERI E, PAOLINO E: SLE presenting with neurological disorders. *J Neurol* 1992; 239: 61-4.
17. DAVIES U, ANSELL B: Central nervous system manifestations in juvenile systemic lupus erythematosus: A problem of management. *J Rheumatol* 1988; 15: 1720-1.
18. HUGHES G: Central nervous system lupus diagnosis and treatment. *J Rheumatol* 1980; 7: 406-11.
19. BOUMPAS D, YAMADA H, PANTRONAS N, SCOTT D, KLIPPEL J, BALOW J: Pulse cyclophosphamide for severe neuropsychiatric lupus. *QJM* 1991; 296: 975-84.
20. BARILE L, LAVALLE C: Transverse myelitis in SLE. The effect of IV pulse methylprednisolone and cyclophosphamide. *J Rheumatol* 1992; 19: 370-2.