Clinicopathological characteristics of severe aortic valve regurgitation caused by Behçet's syndrome

M. Zhang[1], X. Wang[2], Y. Liu[1], X. Liu[3], X. Yu[1], L. Sun[4], Z. Wang[1], L. Zhang[5], J. Liu[1], G. Ma[3], W. Chen[6], W. Wang[2], Q. Miao[3], W. Zheng[1]

[1]Department of Rheumatology and Clinical Immunology, Peking Union Medical College Hospital, Chinese Academy of Medical Sciences & Peking Union Medical College; National Clinical Research Center for Dermatologic and Immunologic Diseases, Ministry of Science & Technology, Beijing; [2]Department of Pathology, Peking Union Medical College Hospital, Chinese Academy of Medical Sciences and Peking Union Medical College, Beijing; [3]Department of Cardiac Surgery, Peking Union Medical College Hospital, Dongcheng District, Beijing; [4]Department of Respiratory and Critical Care Medicine, Peking Union Medical College Hospital, Chinese Academy of Medical Sciences and Peking Union Medical College, Beijing; [5]Division of Infectious Diseases, Department of Internal Medicine, State Key Laboratory of Complex Severe and Rare Disease, Peking Union Medical College Hospital, Beijing; [6]Department of Cardiology, Peking Union Medical College Hospital, Chinese Academy of Medical Sciences & Peking Union Medical College, Beijing, China.

Abstract

Objectives

Aortic valve regurgitation (AR) caused by Behçet's syndrome (BS) has high mortality. Preoperative biologics reduced systemic inflammation, but their effect on lesion inflammation remains unclear.

Methods

Twenty-two BS patients with severe AR who underwent cardiac surgery with retained pathological specimens were included. The pathology of the aortic wall and/or valve was re-analysed based on their preoperative disease activity and treatment strategy. Immunohistochemistry (IHC) assessed the distribution of $CD4^+$, $CD8^+$, $CD20^+$ and $CD68^+$ cells.

Results

The mean diagnosis age was 39.6±13.1 years, with a median disease duration of 9 (3-35) years. Seven (31.8%) underwent cardiac surgery during the active phase due to uncontrollable disease progression, while 15 (68.2%) were in remission. Pathologically, severe AR caused by BS is characterised by mixed inflammatory cell infiltration in the aortic wall. Active cases showed significantly more diffuse infiltration of $CD4^+$ (100% vs. 8.3%, p=0.0002) and $CD8^+$ (71.4% vs. 20%, p=0.058) T cells in the aortic adventitia, with more neutrophil infiltration in the aortic valve (60% vs. 7.7%, p=0.044). Notably, less $CD68^+$ macrophage infiltration (57.2% vs. 0%, p=0.045), $CD4^+$ T cell diffusion (57.1% vs. 0%, p=0.045), and vasa vasorum mucoid degeneration (85.7% vs. 20%, p=0.017) were observed in the aortic adventitia of patients receiving preoperative biologics, together with less aortic valve necrosis (71.4% vs. 0%, p=0.023).

Conclusion

Overall, our study provides valuable insights into the pathology of severe AR caused by BS as a mixed inflammatory infiltration and provides the first pathological rationale for achieving preoperative remission and early biologics to improve the prognosis.

Key words

Behçet's syndrome, aortic regurgitation, pathology, biologics.

*Menghao Zhang, PhD**
*Xun Wang, PhD**
*Yeling Liu, PhD**
Xinpei Liu, MD
Xin Yu, MD
Luxi Sun, MD
Zhimian Wang, PhD
Lifan Zhang, MD
Jinjing Liu, MD
Guotao Ma, MD
Wei Chen, MD
Wenze Wang, MD
Qi Miao, MD
Wenjie Zheng, MD

**M. Zhang, X. Wang and Y. Liu equally contributed.*

Please address correspondence to:
Wenze Wang
Department of Pathology,
Peking Union Medical College Hospital,
Chinese Academy of Medical Sciences and
Peking Union Medical College,
Beijing 100730, China.
E-mail: wwzvssxy@126.com

and to

Qi Miao
Department of Cardiac Surgery,
Peking Union Medical College Hospital,
Dongcheng District,
Beijing, 100730, China.
E-mail: miaoqipumc@hotmail.com

and to

Wenjie Zheng
Department of Rheumatology and
Clinical Immunology,
Peking Union Medical College Hospital,
No.1 Shuaifuyuan, Dongcheng District,
Beijing 100730, China.
E-mail: zhengwj@pumch.cn

Received on August 11, 2024; accepted in revised form on January 21, 2025.

© Copyright Clinical and Experimental Rheumatology 2025.

Funding. This work was supported by National Natural Science Foundation of China [grant number 82171800, 82371822, 32300632], Natural Science Foundation of Beijing [grant number 7232124], Fundamental Research Funds for the Central Universities [3332023113 and 3332023125], National High Level Hospital Clinical Research Funding [2022-PUMCH-C-008], and CAMS Innovation Fund for Medical Sciences [2023-I2M-C&T-B-049].

Competing interests: none declared.

Introduction

Behçet's syndrome (BS) is a chronic, relapsing, systemic vasculitis of unknown aetiology (1, 2). Cardiac involvement in BS, particularly severe aortic regurgitation (AR), has a poor prognosis (3, 4). Severe AR caused by BS primarily involves significant changes in the aortic wall and aortic valve (5, 6). In particular, aortic wall dilatation is observed in most patients with severe AR caused by BS, which may lead to aneurysm formation (7-11). Therefore, the Bentall procedure is now considered to have better efficacy and prognosis than the isolated aortic valve replacement (AVR) for the treatment of AR caused by BS (12-15). In addition, BS-induced inflammation thickens, elongates, and disrupts the alignment of the aortic valve leaflets (16, 17). The severe AR caused by BS is associated with a high incidence of serious postoperative complications such as paravalvular leak (PVL), valve detachment, and aortic root pseudoaneurysm, significantly increasing the risk of reoperation and potentially life-threatening conditions that impose a significant social burden (13, 18). However, the etiopathogenesis and pathophysiology of severe AR caused by BS remain largely to be elucidated. It is crucial to control inflammation before surgery, as high inflammatory indicators correlate with an increased risk of postoperative PVL and mortality (19, 20). Preoperative immunosuppressive therapy (IST), including glucocorticoids (GCs) and immunosuppressants has been indicated to prevent postoperative PVL (19, 21, 22), but some patients may not respond adequately. Our team has recently demonstrated that perioperative biologics rapidly reduce systemic inflammation in patients with severe AR caused by BS, as clinically evidenced by a reduction in Erythrocyte Sedimentation Rate (ESR) and C-Reactive Protein (CRP), leading to a notably reduced incidence of postoperative PVL (5, 23). However, the pathological evidence of their potential effectiveness in reducing inflammation of the aortic wall and valve remains to be investigated.

The pathological features of severe AR caused by BS have been reported in only a few case series and case reports (6, 24-27). Most of them have a poor prognosis due to delayed diagnosis and lack of preoperative IST. A study of 9 cases revealed cystic degeneration, fibrosis, and acute inflammatory cell infiltration in the aortic wall of patients with severe AR caused by BS (27). The aortic valve exhibited extensive mucinous degeneration and fibrous deposition, with focal necrosis in 1 case. None of these patients received preoperative IST, resulting in multiple valve replacements, complications, and even death. Another study highlighted endothelial damage, mixed inflammatory infiltrates, and granulation tissue in 8 cases (6). They demonstrated that BS-induced AR and intracardiac thrombosis share a common pathology with acute endothelialitis caused by extensive and persistent neutrophil infiltration. Notably, serious postoperative complications occurred in patients without preoperative IST (6).

In this study, we comprehensively evaluated the clinical and pathological features of severe AR caused by BS. To the best of our knowledge, this is the first and largest study to combine haematoxylin and eosin (H&E) and immunohistochemical (IHC) staining to analyse the histopathological features of severe AR caused by BS stratified by preoperative disease activity and treatment strategy. It provides a pathological rationale for promoting active preoperative management and improving the prognosis of severe AR caused by BS.

Materials and methods

Patient enrolment and pathology tissue acquisition

This retrospective study was based on a registry database of BS patients at Peking Union Medical College Hospital (PUMCH) from January 2012 to September 2023 and patients diagnosed with severe AR who underwent surgical procedures with pathological specimens of the aortic wall and (or) aortic valve obtained in our institution were included. BS was diagnosed according to the 2014 International Criteria

for Behçet' Disease (ICBD)(28), and patients who did not meet the ICBD criteria were clinically diagnosed with BS by the unanimous consensus of a cardiologist, rheumatologist, cardiac surgeon and pathologist. Confirmation of severe AR caused by BS was based on the subject's clinical manifestations, imaging findings (echocardiography and computed tomography angiography), and pathological evaluation of surgical specimen (29). Multiple characteristic echocardiographic manifestations of AR caused by BS were observed, including aneurysmal aortic valve changes, vegetation-like lesions, and aortic lesions, as previously reported (18, 30, 31). Patients with the presence of other known causes of aortic valve (AV) diseases were excluded, such as rheumatic fever, Marfan syndrome, congenital heart disease, infective endocarditis, syphilis, and AV degeneration. This study complied with the Declaration of Helsinki and was approved by the Institutional Review Board of PUMCH (approval number: K3295). Patient information was anonymized and de-identified for pathology evaluation.

Data collection

We collected the demographic characteristics, clinical manifestations (including cardiac involvement and extracardiac involvement) of BS patients, the number of aortic surgeries during the disease course, and their prognosis (Table I). Additionally, surgical procedures for collecting pathological specimens, perioperative disease activity and treatment strategies were recorded. The disease activity was assessed using the Behçet Disease Current Activity Form (BDCAF) 2006 (http://www.Behçet.ws/pdf/BehçetDiseaseCurrentActivityForm.pdf), and laboratory tests of inflammatory markers such as ESR and CRP. Active BS was defined as those with elevated inflammatory markers and/ or BDCAF≥1 (32, 33). In addition, echocardiography is routinely performed every 3 to 6 months during follow-up to assess PVL after surgery. The poor prognosis of severe AR caused by BS has been defined as the development of PVL.

Table I. Demographic and clinical characteristics of BS patients.

Parameter	Value
Sex (male/female)	15/7
Age at diagnosis (mean ± SD, years)	39.6 ± 13.1
Disease course (medium (range), years)	9 (3-35)
Cardiac involvement	
Severe aortic valve regurgitation	22 (100%)
Aortic root or ascending aorta dilation/aneurysm/pseudoaneurysm	18 (81.8%)
Aortic valve vegetation	5 (22.7%)
Mitral regurgitation (moderate/severe)	8 (36.4%)
Tricuspid regurgitation (moderate/severe)	3 (13.6%)
Extracardiac manifestations	
Oral ulceration	22 (100%)
Genital ulceration	14 (63.6%)
Skin lesion	16 (72.7%)
Ocular involvement	2 (9.1%)
Gastrointestinal involvement	1 (4.6%)
Extracardiac vascular involvement	4 (13.6%)
Arthritis/arthralgia	4 (18.2%)
Type of surgery	
Aortic valve replacement	4 (18.2%)
Bentall	17 (77.3%)
Cabrol/Modified Cabrol	1 (4.6%)
Follow-up (medium (range), month	19.5 (3-120)
Number of surgeries (medium (range), times	1 (1-3)

Tissue samples and pathological assessment

Nineteen cases of aortic wall and 18 cases of aortic valve were neutral-buffered formalin-fixed and paraffin-embedded. Blocks were serially sectioned (4μm) and stained with HE. Two specialists from the Department of Pathology of PUMCH reviewed the archived histopathological sections and recorded the pathological profiles in detail. Given the variable degree of mucoid degeneration in different cases and locations and its potential correlation with the activity of inflammation, we differ using a magnification-based dichotomy: 'severe' when the characteristic colour of mucin deposition could be observed under a low-power lens, and 'mild' otherwise. Likewise, based on different distribution patterns of lymphocytes, we define 'scattered' as lymphocytes sparsely distributing, 'diffuse' as lymphocytes infiltrating across the whole layer, and 'focal' as lymphocytes gathering around a certain spot, usually a vasa vasorum. IHC staining for T cells, B cells and macrophages was carried out for 19 cases of aortic walls and 10 cases of valves using monoclonal antibodies of CD4 (Cat. ZA-0519), CD8 (Cat. ZA-0508), CD20 (Cat. ZM-0039) and CD68 (Cat. ZM-0060) from ZSGB-BIO company (China).

Statistical analysis

Data with Gaussian distribution was presented as mean value ± standard deviation. Data with non-Gaussian-distributed data were described as median values (range). Categorical variables were expressed as numbers (percentages). Between-group comparisons were performed using the Student's t-test or Mann-Whitney test of the continuous variables and Fisher's exact test for the categorical variables. P values<0.05 were considered a statistically significant difference. Statistical analyses were performed using the SPSS (version 23.0, IBM Corp, Armonk, NY, USA).

Results

Demographic and clinical characteristics of patients

Twenty-two patients with severe AR caused by BS were enrolled. Among them, 21 patients (95.5%) fulfilled the 2014 ICBD criteria, and 1 (4.6%) was clinically diagnosed. The mean age at diagnosis was 39.6±13.1 years; the median disease duration was 9 (range 3–35) years; and the median number of operations was 1 (1-3) time. All patients had severe AR on preoperative echocardiography, with aortic root or ascending aortic dilation/aneurysm in 18 (81.8%) cases (pseudoaneurysm, n=1), aortic valve vegetations in 5

Table II. Pathological parameter of the aortic wall in patients with severe AR caused by BS.

Pathological parameter of aortic wall			Intima		Media		Adventitia	
			Active BS	Remission BS	Active BS	Remission BS	Active BS	Remission BS
Inflammatory cell infiltration			5/7 71.4%)	12/12 (100%)	7/7 (100%)	12/12 (100%)	7/7 (100%)	11/12 (91.7%)
HE assessment	Cell type	Neutrophils	0/5 (0%)	0/12 (0%)	1/7 (14.3%)	0/12 (0%)	5/7 (71.4%)	4/11 (36.4%)
		Eosinophils	0/5 (0%)	0/12 (0%)	0/7 (0%)	0/12 (0%)	5/7 (71.4%)	6/11 (54.6%)
		Lymphocytes	5/5 (100%)	12/12 (100%)	7/7 (100%)	12/12 (100%)	7/7 (100%)	11/11 (100%)
		Plasma cells	0/5 (0%)	0/12 (0%)	0/7 (0%)	0/12 (0%)	7/7 (100%)	11/11 (100%)
	Distribution	Diffuse	2/5 (40%)	1/12 (8. 3%)	1/7 (14.3%)	0/12 (0%)	3/7 (42.9%)	1/11 (9.1%)
		Scattered/Focal	4/5 (80%)	11/12 (91.7%)	6/7 (85.7%)	12/12 (100%)	4/7 (57.1%)	10/11 (90.9%)
IHC assessment	**$CD4^+$ T cell infiltration**		4/7 (57.2%)	6/12 (50%)	4/7 (57.2%)	3/12 (25%)	7/7 (100%)	12/12 (100%)
	Distribution	Diffuse	2/4 (50%)	1/6 (16.7%)	2/4 (50%)	0/3 (0%)	7/7 (100%)*	1/12 (8.3%)*
		Scattered/Focal	2/4 (50%)	5/6 (83.3%)	2/4 (50%)	3/3 (100%)	0/7 (0%)*	11/12 (91.7%)*
	$CD8^+$ T cell infiltration		5/7 (71.4%)	11/12 (91.7%)	4/7 (57.2%)	9/12 (75%)	7/7 (100%)	10/12 (83.3%)
	Distribution	Diffuse	1/5 (20%)	1/11 (9.1%)	1/4 (25%)	0/9 (0%)	5/7 (71.4%)	2/10 (20%)
		Scattered/Focal	4/5 (80%)	10/11 (90.9%)	3/4 (75%)	9/9 (100%)	2/7 (28.6%)	8/10 (80%)
	$CD20^+$ B cell infiltration		1/7 (14.3%)	0/12 (0%)	3/7 (42.9%)*	0/12 (0%)*	7/7 (100%)	9/12 (75%)
	Distribution	Diffuse	0/1 (0%)	/	0/3 (0%)	/	0/7 (0%)	0/9 (0%)
		Scattered/Focal	1/1 (100%)	/	3/3 (100%)	/	7/7 (100%)	9/9 (100%)
	$CD68^+$ macrophage infiltration		3/7 (42.9%)	4/12 (33.3%)	3/7 (42.9%)	2/12 (16.7%)	5/7 (71.4%)	3/12 (25%)
	Distribution	Diffuse	0/3 (0%)	0/4 (0%)	0/3 (0%)	0/2 (0%)	2/5 (40%)	0/3 (0%)
		Scattered/Focal	3/3 (100%)	4/4 (100%)	3/3 (100%)	2/2 (100%)	3/5 (60%)	3/3 (100%)
Mucoid degeneration			4/7 (57.1%)	10/12 (83.3%)	3/7 (42.9%)	8/12 (66.7%)	1/7 (14.3%)	1/12 (8.3%)
Fibrous tissue proliferation			5/7 (71.4%)	12/12 (100%)	7/7 (100%)	12/12 (100%)	6/7 (85.7%)	11/12 (91.7%)
Vasa vasorum			/	/	/	/	7/7 (100%)	11/12 (91.7%)
Classical vasculitis			/	/	/	/	7/7 (100%)	8/11 (72.7%)
Mucoid degeneration			/	/	/	/	4/7 (57.1%)	3/11 (27.3%)
Granulation tissue			/	/	/	/	4/7 (57.1%)	2/12 (16.7%)

HE: haematoxylin and eosin; IHC: immunohistochemistry; /: not applicable. *indicates a statistically significant difference between active BS and remission BS, with $p<0.05$.

(22.7%) cases (Table I). In addition, moderate to severe mitral and tricuspid regurgitation were present in 8 (36.4%) and 3 (13.6%) cases, respectively. Notably, 6 (27.3%) patients had suffered severe PVL in previous operations.

Except for cardiac valve involvement, oral ulcers were present in all 22 patients during BS, followed by genital ulcers (63.6%), skin lesions (72.7%, including pseudo-folliculitis, erythema nodosum, and pathergy), extracardiac vascular involvement (13.6%), arthralgia/arthritis (18.2%), ocular involvement (9.1%) and gastrointestinal involvement (4.6%) (Table I).

Perioperative interventions and prognosis in patients with severe AR caused by BS

All patients underwent surgery by experienced cardiac surgeons. Seven (31.8%) were inadequately treated with high disease activity indicators (ESR 18 (2-75); CRP 14.03 (7.47-109); BDCAF 1 (0-2)) and underwent cardiac surgery due to uncontrolled disease progression. The remaining 15 were managed in remission, receiving GCs, immunosuppressants, and biologics (n=5) for a median of 6 (0.25-24) months. Surgeries included AVR in 4 (18.2%) cases, Bentall procedures in 17 (77.3%) cases, and Cabrol procedures in 1 (4.6%) case (Table I). Additionally, 8 (36.4%) received postoperative immunosuppressants and biologics therapy. After a median follow-up of 19.5 (3-120) months, 20 (90.9%) patients were free of postoperative complications such as PVL, and 2 (9.1%) were lost to follow-up.

Pathological characteristics of the aortic wall in patients with severe AR caused by BS

Two pathologists independently and anonymously reviewed the archived HE and IHC staining of the 19 aortic walls. HE analysis revealed the infiltration of lymphocytes, neutrophils, and plasma cells, which is consistent with previous reports (6, 34). Notably, active cases are characterized by prominent neutrophil infiltration (Table II and Fig. 1A). Detailed analysis of the three aortic layers (intima, media, and adventitia) in each subject indicated that active cases had more diffuse inflammatory infiltration in the intima (40% *vs*. 8.3%), media (14.3% *vs*. 0%), and adventitia (42.9% *vs*. 9.1%), with more neutrophil infiltration in the media (14.3% *vs*. 0%) and adventitia (71.4% *vs*. 36.4%). Furthermore, active cases exhibited increased mucoid degeneration (14.3% *vs*. 8.3%), granulation tissue (57.1% *vs*. 16.7%), vasa vasorum mucoid degeneration (57.1% *vs*. 27.3%) and vasculitis (100% *vs*. 72.7%) in the adventitia (Fig. 1B-1D and Supplementary Fig. S1A-1B), as well as neurofibril thickening (Fig. 1E). IHC analysis revealed that active cases had significantly higher $CD4^+$ (100% *vs*. 8.3%, p=0.0002) and $CD8^+$ (71.4% *vs*. 20%, p=0.058) T cell diffuse infiltration in the aortic adventitia (Fig. 1F-1H and Supplementary Fig. S1C-1E). Consistent with the aortic valve, $CD20^+$ B cells distribution was only scattered/focal (Fig. 1 (and Supplementary Fig. 1F). Pathologically, our findings provide the first evidence that preoperative remission mitigates the aortic wall inflammation and tissue fragility.

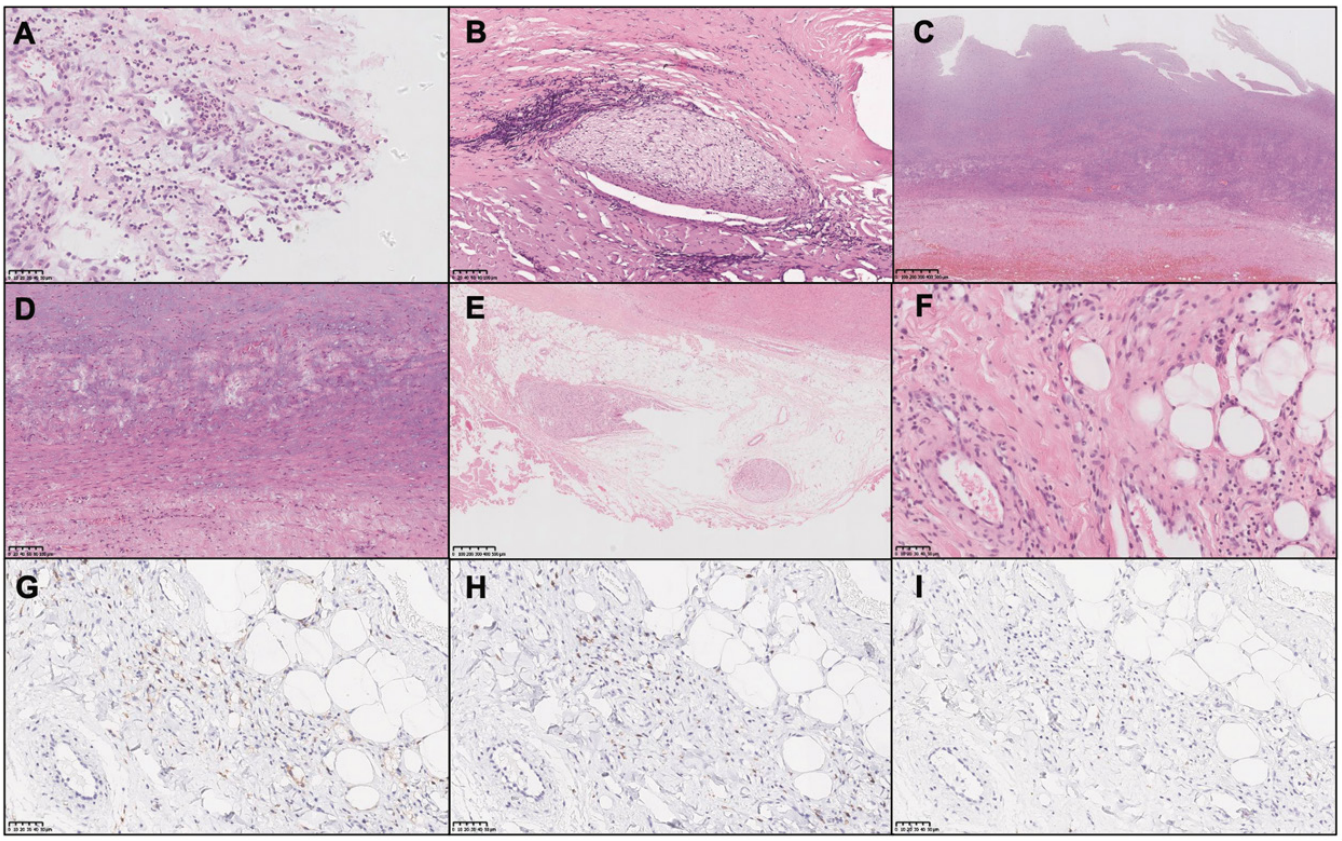

Fig. 1. Representative images of the aortic wall in active patients with severe AR caused by BS.
A) Neutrophils diffuse in the adventitia of aortic wall (HE); **B)** The abnormal vasa vasorum with wall thickening and lumen narrowing is accompanied by both severe mucoid degeneration and vasculitis (HE); **C-D)** Significant mucoid degeneration and thickness of aortic intima and media (HE); **E)** Thickened nerve fibre in the adventitia (HE); **F-I)** The IHC image of HE (**F**), $CD4^+$ (**G**). $CD8^+$ (**H**) and $CD20^+$ (**I**) at the corresponding location in the serial sections.

Pathological characteristics of the aortic valve in patients with severe AR caused by BS

Consistent with the pathology of aortic wall, HE analysis of 18 aortic valves revealed a mixed inflammatory cell infiltration, including neutrophils, lymphocytes, eosinophils, and plasma cells. Active cases showed more diffuse inflammatory cell infiltration compared to remission cases (80% *vs*. 30.8%) (Supplementary Table S1). Remarkably, active cases exhibited significantly higher neutrophil infiltration (60% *vs*. 7.7%, p=0.044) (Fig. 2A-2B). Fibrosis was present in all cases. Mucoid degeneration was diffuse in active cases and mild to moderate in remission cases (Fig. 2C-2D and Supplementary Fig. S2A-2B). Necrosis, an indicator of tissue fragility and vulnerability, was more common in active cases (80% *vs*. 46.2%) (Fig. 2D and Supplementary Fig. S2B). Neovascularisation, which is not typically observed in normal aortic valves, was more frequent in active cases (80% *vs*. 53.9%). IHC analysis demonstrated that all aortic valves showed $CD4^+$ T cells infiltration, with a more diffuse infiltration in active cases (60% *vs*. 20%). Active cases had a more diffuse infiltration of $CD8^+$ T cells (75% *vs*. 25%) and $CD68^+$ macrophages (75% *vs*. 0%). In contrast, the distribution of $CD20^+$ B cells was only scattered/focal (Fig. 2E-2I and Supplementary Fig. S2C-2F). These findings suggest that achieving preoperative remission may reduce acute inflammation and destruction of the aortic valve, potentially preventing PVL development (35).

Reduce aortic wall and valve inflammation in patients treated with preoperative biologics

Our previous study demonstrated that perioperative biologics reduced the incidence of postoperative PVL (5). To further investigate their involvement in improving pathology, we analysed BS in groups according to preoperative treatment strategies. Of note, patients treated with preoperative biologics showed less infiltration of neutrophils (61.6% *vs*. 20%), $CD20^+$ B cells (85.7% *vs*. 80%), $CD68^+$ macrophages (57.2% *vs*. 0%, p=0.045), and less diffusion of $CD4^+$ T cells (57.1% *vs*. 0%, p=0.045) and $CD8^+$ T cells (50% *vs*. 20%) in the aortic adventitia (Supplementary Table S2). Moreover, less vasa vasorum mucoid degeneration (85.7% *vs*. 20%, p=0.017), neurofibril thickening (71.4% *vs*. 20%), and granulation tissue (42.9% *vs*. 0) were also noted in the aortic adventitia of the preoperative biologics group (Supplementary Table S2). In Addition, patients receiving preoperative biologics showed reduced infiltration of neutrophils (28.6% *vs*. 0) and $CD20^+$ B cells (75% *vs*. 0%), less diffusion of $CD4^+$ T (50% *vs*. 0%), $CD8^+$ T (57.14% *vs*. 0%) and $CD68^+$ macrophages (50% *vs*. 0%), and less necrosis (71.4% *vs*. 0, p=0.023) in the aortic valves (Supplementary Table S3) were observed. The above observa-

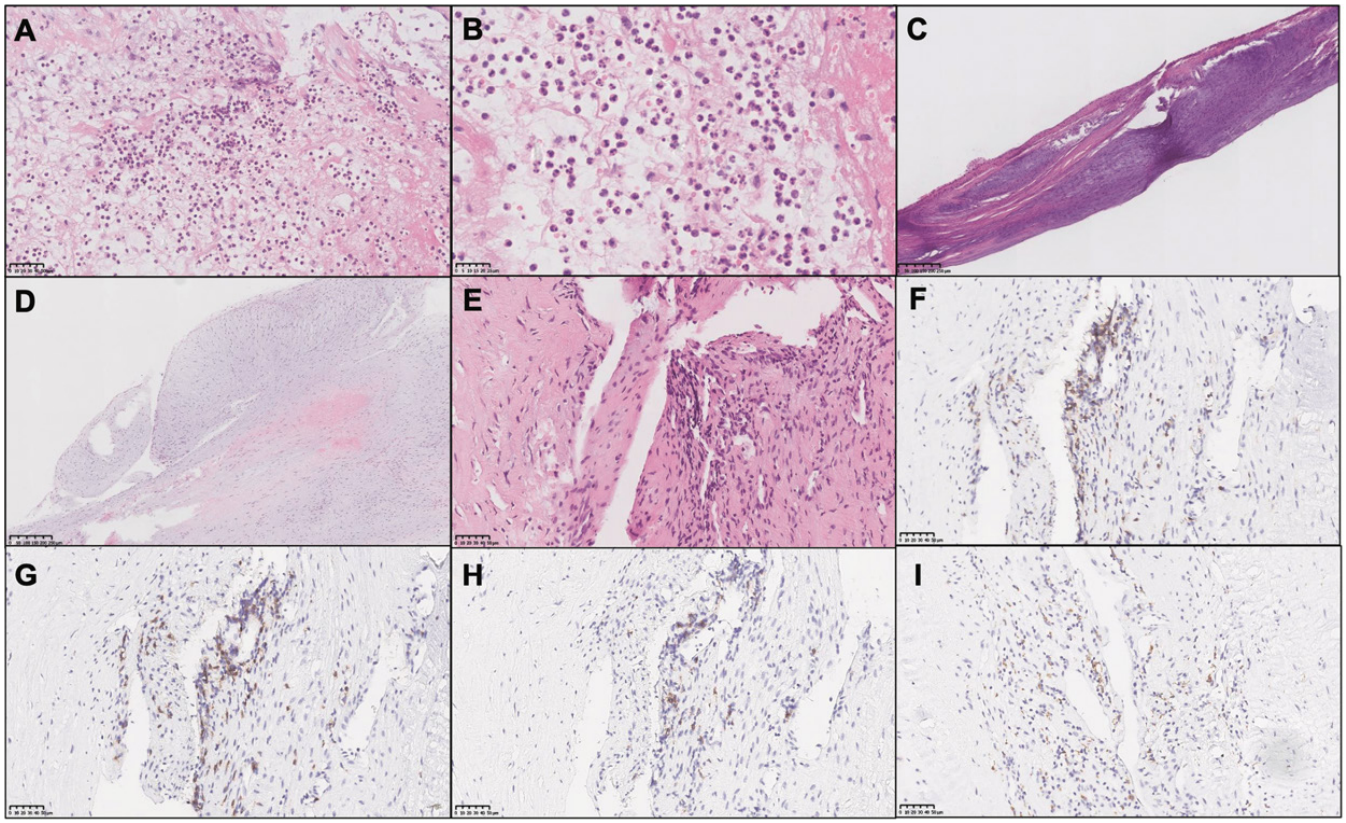

Fig. 2. Representative images of the aortic valve in active patient with severe aortic valve reggurgitation caused by BS.
A-B) Neutrophils diffuse in the inflammatory exudate around the valve at different powers (HE); **C)** Low power shows diffused mucoid degeneration, and the normal structure of aortic valve is severely disrupted (HE); **D)** High power shows typical stellar cells in the mucoid degeneration background with focal fibrosis (HE); **E-H)** Lymphocytes aggregate focally in the IHC image of HE (**E**), $CD4^+$ (**F**), $CD8^+$ (**G**) and $CD20^+$ (**H**) at the corresponding location in the serial sections. **I**) $CD68^+$ at a different location of the same patient.

tion suggests that early biologic treatment may reduce the inflammation and improve the prognosis of severe AR caused by BS.

Discussion

In this study, we demonstrated that severe AR caused by BS is histopathologically characterised by a mixed inflammatory cell infiltration, with neutrophil and $CD4^+$ T cell infiltration being the most prominent manifestation. Of note, active cases showed significantly more diffuse infiltration of $CD4^+$ and $CD8^+$ T cells in the aortic adventitia, and more neutrophil infiltration in the aortic valve. Compared to the conventional IST, preoperative biologics notably reduced $CD68^+$ macrophage infiltrations, and $CD4^+$ T cells diffusions in the aortic adventitia. These findings indicate that preoperative biologics play a pivotal role in alleviating tissue inflammation and preserving structural and functional integrity, thereby preventing life-threatening complications. This is the first study to pathologically evaluate severe AR caused by BS stratified by preoperative disease activity and treatment strategy, with the largest cohort and longest follow-up.

Innate immune activation, particularly neutrophil hyperactivation plays a central role in BS pathogenesis (36-39), and thus BS has also been recognized as a "neutrophilic vasculitis" (40-42). Neutrophil infiltration has been demonstrated in the cutaneous, vascular, articular, ocular, intestinal, and neurological systems in patients with BS (40, 43-49). Previous studies have indicated that the pathology of AR caused by BS is characterised by a mixed inflammatory infiltration, with a notable presence of neutrophils and $CD3^+$ T cells (6, 27, 34, 50, 51). In particular, neutrophil infiltration was thought to persist in pathological cardiac BS tissues, regardless of predilection sites or disease stage (6). However, our study found a substantial reduction in neutrophil infiltration in both the aortic wall and valve of remission cases, possibly due to appropriate preoperative management. Furthermore, our study identified extensive infiltration of $CD68^+$ macrophages and $CD4^+$ T cells in the aortic wall and valve by large-scale IHC staining analyses, especially in active cases. A histological layer-by-layer analysis of the aortic wall was also performed and revealed that all active cases exhibited diffuse infiltration of $CD4^+$ T cells in the aortic adventitia, whereas the majority of remission cases demonstrated only focal infiltration. B-cell infiltration in BS lesions is extremely rare and has only been sporadically reported in intestinal (52) and synovial tissues (47). Upon careful review, we found that some cases showed $CD20^+$ B cells infiltration, especially in active cases. This suggests a potential involvement of B cells in BS pathogenesis, which requires further investigation. Eosinophils are involved in inflammatory disease progression (53), but there are currently no reports

of eosinophilic infiltration in BS lesions. In this study, eosinophils were observed in some cases, especially active ones, which might be a sign of progressive inflammation, despite normal peripheral blood eosinophil levels in these cases. Our results demonstrate a mixed inflammatory cell infiltration in the aortic valve and wall in patients with severe AR caused by BS, and that achieving preoperative remission contributes to the reduction of tissue inflammation.

Surgery during active disease in BS patients with severe AR carries a high risk of life-threatening complications (25, 35, 54, 55), and control of perioperative inflammation is crucial to reduce postoperative PVL (5, 19, 22, 29, 56). For BS patients who are refractory to conventional IST, perioperative biologics have been clinically proven to be effective in reducing systemic inflammation and improving prognosis (5, 23). This study provides the first evidence that patients treated with preoperative biologics showed significantly lower diffuse infiltration of multiple inflammatory cells, including neutrophils, $CD4^+$ T cells, $CD8^+$ T cells, and $CD68^+$ macrophages, in both aortic wall and valve. These findings indicate that preoperative biologics may improve structural integrity and reduce the vulnerability of aortic tissue by reducing inflammation. They provide pathological evidence for the potential benefits of preoperative biologics in reducing tissue inflammation.

Fibrous tissue proliferation is well-documented in patients with AR caused by BS (6, 27, 50). Consistently, almost all aortic walls and valves in our study showed fibrous tissue proliferation. Granulomatous reactions, although reported in some cases (6, 27), were rare in our study and appeared related to surgery-related foreign material, rather than BS itself, given the visible foreign material around vessel. Interestingly, we found granulation tissue at the periphery of the aortic adventitia, particularly in active cases. The cause remains unclear, but insidious inflammation in adjacent areas (like the pleural space) might be involved. Furthermore, calcification and complete necrosis indicate tissue vulnerability and potential complications (6, 27). In our cohort, complete aortic wall necrosis was absent, and calcification was present in only 3 (15.8%) cases. In addition, 10 (55.6%) and 3 (16.8%) cases had necrosis and calcification of the aortic valve, respectively, but all had good prognoses, likely due to preoperative IST. Notably, none of the patients receiving preoperative biologics developed aortic valve calcification or necrosis, implying that early biologic therapy might improve aortic valve fragility. Taken together, preoperative remission and biologics potentially reduce the inflammation and damage of lesions, indicating their importance in improving prognosis.

Limitations

We acknowledge some limitations of this study. First, the number of patients enrolled in this study was relatively limited due to the low incidence of severe AR caused by BS, and the requirement to re-analyse pathological specimens from patients who underwent surgery at our institution. Despite this, our pathological cohort represents the largest, with longest follow-up, and best prognostic data for severe AR caused by BS to date. Second, as a retrospective single-centre study, there is a potential for selection bias. Third, disease controls were not included in this study, as the aim of this study is to focus on the relationship between systemic preoperative disease activity and lesion inflammation. Finally, some recently enrolled patients require long-term follow-up. Future longer follow-up and the inclusion of more patients from potentially multiple centres are needed.

Conclusion

Our study highlights the pathology of severe AR caused by BS as a mixed inflammatory infiltration. A comprehensive histological examination, combining HE and IHC analysis, revealed a significant reduction in acute inflammation, characterized by neutrophils, and chronic inflammation, dominated by $CD4^+$ T cell infiltration, in patients who underwent surgery in remission or received preoperative biologics. It provides the first pathological rationale for achieving preoperative remission and early biologics therapy to improve the prognosis of severe AR caused by BS.

Acknowledgments

We thank the health professional staff from the Department of Rheumatology and Clinical Immunology, Peking Union Medical College Hospital and appreciate the participation of all the patients in this study.

References

1. MCHUGH J: Different phenotypes identified for Behçet syndrome. *Nat Rev Rheumatol* 2021; 17(4): 188. https://doi.org/10.1038/s41584-021-00587-1
2. ZOU J, LUO JF, SHEN Y, CAI JF, GUAN JL: Cluster analysis of phenotypes of patients with Behçet's syndrome: a large cohort study from a referral center in China. *Arthritis Res Ther* 2021; 23(1): 45. https://doi.org/10.1186/s13075-021-02429-7
3. GAO N, HAN W, CI WP, LIAO H, DU J: [Clinical data analysis of cardiovascular involvement in Behçet's disease]. *Zhonghua Yi Xue Za Zhi* 2016; 96(19): 1523-6. https://doi.org/10.3760/cma.j.issn.0376-2491.2016.19.013
4. QU W, CHEN Y, ZHANG Z: Clinical and pathological spectrum of aortitis in a Chinese cohort. *Cardiovasc Pathol* 2024; 71: 107651. https://doi.org/10.1016/j.carpath.2024.107651
5. SUN L, LIU J, JIN X *et al*.: Perioperative management with biologics on severe aortic valve regurgitation caused by Behçet syndrome: the experience from a single center. *Ther Adv Chronic Dis* 2021; 12: 20406223211026753. https://doi.org/10.1177/20406223211026753
6. LEE I, PARK S, HWANG I *et al*.: Cardiac Behçet disease presenting as aortic valvulitis/aortitis or right heart inflammatory mass: a clinicopathologic study of 12 cases. *Am J Surg Pathol* 2008; 32(3): 390-8. https://doi.org/10.1097/PAS.0b013e31814b23da
7. DESBOIS AC, WECHSLER B, CACOUB P, SAADOUN D: [Aortic inflammatory lesions in Behçet's disease]. *Rev Med Interne* 2016; 37(4): 230-8. https://doi.org/10.1016/j.revmed.2015.10.351
8. CHAU EM: Aortitis. *Curr Treat Options Cardiovasc Med* 2007; 9(2): 109-14. https://doi.org/10.1007/s11936-007-0004-7
9. FAROUK H, ZAYED HS, EL-CHILALI K: Cardiac findings in patients with Behçet's disease: Facts and controversies. *Anatol J Cardiol* 2016; 16(7): 529-33. https://doi.org/10.14744/AnatolJCardiol.2016.7029
10. MARZBAN M, MANDEGAR MH, KARIMI A *et al*.: Cardiac and great vessel involvement in "Behçet's disease". *J Card Surg* 2008; 23(6): 765-8. https://doi.org/10.1111/j.1540-8191.2008.00607.x
11. TAI YT, FONG PC, NG WF *et al*.: Diffuse aortitis complicating Behçet's disease leading to severe aortic regurgitation. *Cardiology* 1991;

79(2): 156-60. https://doi.org/10.1159/000174874
12. MA WG, ZHENG J, ZHU JM, LIU YM, LI M, SUN LZ: Aortic regurgitation caused by Behçet's disease: surgical experience during an 11-year period. *J Card Surg* 2012; 27(1): 39-44. https://doi.org/10.1111/j.1540-8191.2011.01392.x
13. TANG C, SONG Y, HUANG X *et al*.: Surgical treatment of Behçet's disease with severe aortic regurgitation. *Front Cardiovasc Med* 2023; 10: 1290615. https://doi.org/10.3389/fcvm.2023.1290615
14. CHENG Z, KANG Z, JI Y, GUO Y: Behçet's disease involved the root of aorta in the treatment with modified Bentall procedure: a case report. *J Cardiothorac Surg* 2020; 15(1): 30. https://doi.org/10.1186/s13019-020-1070-0
15. HUANG XM, HUANG CJ, SHA Y, WANG Q, ZENG XJ: [Cardiac valve involvement in Behçet's disease: a clinical study of 10 patients]. *Zhonghua Yi Xue Za Zhi* 2010; 90(33): 2357-9.
16. COCCO G, GASPARYAN AY: Behçet's Disease: an Insight from a Cardiologist's Point of View. *Open Cardiovasc Med J* 2010; 4: 63-70. https://doi.org/10.2174/1874192401004020063
17. CHOI E, MATHEWS LM, PAIK J *et al*.: Multimodality Evaluation of Aortic Insufficiency and Aortitis in Rheumatologic Diseases. *Front Cardiovasc Med* 2022; 9: 874242. https://doi.org/10.3389/fcvm.2022.874242
18. LI R, PU L, SUN Z *et al*.: Echocardiographic findings of cardiovascular involvement in Behçet's disease and post-operative complications after cardiac surgery. *Clin Exp Rheumatol* 2018; 36 (Suppl. 115): S103-9.
19. GUO X, TIAN Z, LIU Y, LI M, ZENG X, FANG Q: Preoperative immunosuppressive therapy reduces paravalvular leakage after aortic valve surgery in patients with aortic regurgitation attributable to Behçet's disease. *Clin Exp Rheumatol* 2016; 34 (Suppl. 102): S26-33.
20. HA YJ, JUNG SY, LEE KH *et al*.: Long-term clinical outcomes and risk factors for the occurrence of post-operative complications after cardiovascular surgery in patients with Behçet's disease. *Clin Exp Rheumatol* 2012; 30 (Suppl .72): S18-26.
21. PARK MC, HONG BK, KWON HM, HONG YS: Surgical outcomes and risk factors for post-operative complications in patients with Behçet's disease. *Clin Rheumatol* 2007; 26(9): 1475-80. https://doi.org/10.1007/s10067-006-0530-9
22. LI X, WEN X, XU J, LIN Q, LIU L: Prognostic analysis of Behçet's disease with aortic regurgitation or involvement. *Neth Heart J* 2022; 30(3): 172-80. https://doi.org/10.1007/s12471-021-01567-6
23. SUN LX, LIU JJ, HOU YX *et al*.: [Clinical analysis of golimumab in the treatment of severe/refractory cardiovascular involvement in Behçet syndrome]. *Beijing Da Xue Xue Bao Yi Xue Ban* 2020; 52(6): 1056-62. https://doi.org/10.19723/j.issn.1671-167X.2020.06.011
24. CHIKAMORI T, DOI YL, YONEZAWA Y, TAKATA J, KAWAMURA M, OZAWA T: Aortic regurgitation secondary to Behçet's disease. A case report and review of the literature. *Eur Heart J* 1990; 11(6): 572-6. https://doi.org/10.1093/oxfordjournals.eurheartj.a059752
25. TSUI KL, LEE KW, CHAN WK *et al*.: Behçet's aortitis and aortic regurgitation: a report of two cases. *J Am Soc Echocardiogr* 2004;17(1):83-6. https://doi.org/10.1016/j.echo.2003.09.009
26. CHIU HH, WANG SS, WU MH, WANG JK: Aortitis with severe aortic regurgitation in Behcet's disease: a case report. *J Formos Med Assoc* 2010; 109(1): 82-4. https://doi.org/10.1016/s0929-6646(10)60025-3
27. LEE CW, LEE J, LEE WK *et al*.: Aortic valve involvement in Behçet's disease. A clinical study of 9 patients. *Korean J Intern Med* 2002; 17(1): 51-6. https://doi.org/10.3904/kjim.2002.17.1.51
28. THE INTERNATIONAL CRITERIA FOR BEHÇET'S DISEASE (ICBD): a collaborative study of 27 countries on the sensitivity and specificity of the new criteria. *J Eur Acad Dermatol Venereol* 2014; 28(3): 338-47. https://doi.org/10.1111/jdv.12107
29. CHOI HM, KIM HK, PARK SJ *et al*.: Predictors of paravalvular aortic regurgitation after surgery for Behçet's disease-related severe aortic regurgitation. *Orphanet J Rare Dis* 2019; 14(1): 132. https://doi.org/10.1186/s13023-019-1083-8
30. PU L, LI R, XIE J *et al*.: Characteristic Echocardiographic Manifestations of Behçet's Disease. *Ultrasound Med Biol* 2018; 44(4): 825-30. https://doi.org/10.1016/j.ultrasmedbio.2017.12.010
31. SONG JK, JEONG YH, KANG DH *et al*.: Echocardiographic and clinical characteristics of aortic regurgitation because of systemic vasculitis. *J Am Soc Echocardiogr* 2003; 16(8): 850-7. https://doi.org/10.1067/s0894-7317(03)00406-1
32. EMMI G, BAGNI G, LASTRAIOLI E *et al*.: A unique circulating miRNA profile highlights thrombo-inflammation in Behçet's syndrome. *Ann Rheum Dis* 2022; 81(3): 386-97. https://doi.org/10.1136/annrheumdis-2021-220859
33. CHENG L, WANG D, WANG Z *et al*.: Proteomics Landscape Mapping of Organ-Resolved Behçet's Disease Using In-Depth Plasma Proteomics for Identifying Hyaluronic Binding Protein 2 Expression Associated with Vascular Involvement. *Arthritis Rheumatol* 2023; 75(3): 424-37. https://doi.org/10.1002/art.42348
34. STONE JR, BRUNEVAL P, ANGELINI A *et al*.: Consensus statement on surgical pathology of the aorta from the Society for Cardiovascular Pathology and the Association for European Cardiovascular Pathology: I. Inflammatory diseases. *Cardiovasc Pathol* 2015; 24(5): 267-78. https://doi.org/10.1016/j.carpath.2015.05.001
35. JEONG DS, KIM KH, KIM JS, AHN H: Long-term experience of surgical treatment for aortic regurgitation attributable to Behçet's disease. *Ann Thorac Surg* 2009; 87(6): 1775-82. https://doi.org/10.1016/j.athoracsur.2009.03.008
36. HUANG L, YU X, LI L *et al*.: Aberrant FcγRIIb and FcγRIII expression on monocytes from patients with Behçet's disease. *Clin Immunol* 2020; 219: 108549. https://doi.org/10.1016/j.clim.2020.108549
37. GAZZITO DEL PADRE TC, BELEM J, DE AGUIAR MF *et al*.: Distribution of monocytes subpopulations in the peripheral blood from patients with Behçet's disease - Impact of disease status and colchicine use. *Clin Immunol* 2021; 231: 108854. https://doi.org/10.1016/j.clim.2021.108854
38. NEVES FS, SPILLER F: Possible mechanisms of neutrophil activation in Behçet's disease. *Int Immunopharmacol* 2013; 17(4): 1206-10. https://doi.org/10.1016/j.intimp.2013.07.017
39. ZHANG M, KANG N, YU X *et al*.: TNF inhibitors target a mevalonate metabolite/TRPM2/calcium signaling axis in neutrophils to dampen vasculitis in Behçet's disease. *Nat Commun* 2024; 15(1): 9261. https://doi.org/10.1038/s41467-024-53528-3
40. HAYASAKI N, ITO M, SUZUKI T *et al*.: Neutrophilic phlebitis is characteristic of intestinal Behçet's disease and simple ulcer syndrome. *Histopathology* 2004; 45(4): 377-83. https://doi.org/10.1111/j.1365-2559.2004.01954.x
41. BECATTI M, EMMI G, SILVESTRI E *et al*.: Neutrophil Activation Promotes Fibrinogen Oxidation and Thrombus Formation in Behçet Disease. *Circulation* 2016; 133(3): 302-11. https://doi.org/10.1161/circulationaha.115.017738
42. PERAZZIO SF, ANDRADE LEC, DE SOUZA AWS: Understanding Behçet's Disease in the Context of Innate Immunity Activation. *Front Immunol* 2020; 11: 586558. https://doi.org/10.3389/fimmu.2020.586558
43. SAFI R, KALLAS R, BARDAWIL T *et al*.: Neutrophils contribute to vasculitis by increased release of neutrophil extracellular traps in Behçet's disease. *J Dermatol Sci* 2018; 92(2): 143-50. https://doi.org/10.1016/j.jdermsci.2018.08.010
44. OZLUK E, BALTA I, AKOGUZ O *et al*.: Histopathologic Study of Pathergy Test in Behçet's Disease. *Indian J Dermatol* 2014; 59(6): 630. https://doi.org/10.4103/0019-5154.143568
45. YUE C, LI J, LI M, ZHANG F, ZHAO D, CUI Q: Cardiac mass in Behçet's disease. *Clin Exp Rheumatol* 2012; 30 (Suppl. 72): S27-31.
46. LE JONCOUR A, MARTOS R, LOYAU S *et al*.: Critical role of neutrophil extracellular traps (NETs) in patients with Behçet's disease. *Ann Rheum Dis* 2019;78(9):1274-82. https://doi.org/10.1136/annrheumdis-2018-214335
47. CAÑETE JD, CELIS R, NOORDENBOS T *et al*.: Distinct synovial immunopathology in Behçet disease and psoriatic arthritis. *Arthritis Res Ther* 2009; 11(1): R17. https://doi.org/10.1186/ar2608
48. MATSUO T, ITAMI M, NAKAGAWA H, NAGAYAMA M: The incidence and pathology of conjunctival ulceration in Behçet's syndrome. *Br J Ophthalmol* 2002; 86(2): 140-3. https://doi.org/10.1136/bjo.86.2.140
49. BORHANI HAGHIGHI A, SHARIFZAD HR, MATIN S, REZAEE S: The pathological presentations of neuro-Behçet disease: a case report and review of the literature. *Neurologist* 2007; 13(4): 209-14. https://doi.org/10.1097/01.nrl.0000263698.26284.cf
50. ZHU YL, WU QJ, GUO LL *et al*.: The clinical characteristics and outcome of intracardiac thrombus and aortic valvular involvement in Behçet's disease: an analysis of 20 cases.

Clin Exp Rheumatol 2012; 30 (Suppl. 72): S40-5.
51. MATSUMOTO T, UEKUSA T, FUKUDA Y: Vasculo-Behçet's disease: a pathologic study of eight cases. *Hum Pathol* 1991; 22(1): 45-51. https://doi.org/10.1016/0046-8177(91)90060-3
52. WU YC, FU YJ, XIA HJ, ZHU J, HUANG Y, JIANG ZN: Ileocecal involvement in intestinal Behçet's disease and Crohn's disease: comparison of clinicopathological and immunophenotypic features. *J Dig Dis* 2023; 24(11): 594-602. https://doi.org/10.1111/1751-2980.13236
53. JACKSON DJ, AKUTHOTA P, ROUFOSSE F: Eosinophils and eosinophilic immune dysfunction in health and disease. *Eur Respir Rev* 2022; 31(163). https://doi.org/10.1183/16000617.0150-2021
54. HAN JK, KIM HK, KIM YJ *et al*.: Behçet's disease as a frequently unrecognized cause of aortic regurgitation: suggestive and misleading echocardiography findings. *J Am Soc Echocardiogr* 2009; 22(11): 1269-74. https://doi.org/10.1016/j.echo.2009.07.025
55. TAKAYAMA T, OZAWA T, SANADA A *et al*.: Aortic Regurgitation Presenting with Recurrent Detachment of a Prosthetic Valve, as the First Presenting Symptom of Cardiovascular Behçet's Disease. *Intern Med* 2018; 57(6): 823-7. https://doi.org/10.2169/internalmedicine.9603-17
56. SONG JK, KIM MJ, KIM DH *et al*.: Factors determining outcomes of aortic valve surgery in patients with aortic regurgitation due to Behçet's disease: impact of preoperative echocardiographic features. *J Am Soc Echocardiogr* 2011; 24(9): 995-1003. https://doi.org/10.1016/j.echo.2011.06.006