

# HCV-related cryoglobulinemic vasculitis: An update on its etiopathogenesis and therapeutic strategies

C. Ferri, D. Giuggioli, M. Cazzato<sup>1</sup>, M. Sebastiani<sup>1</sup>, M.T. Mascia, A.L. Zignego<sup>2</sup>

Rheumatology Unit, Department of Internal Medicine, Medical School, University of Modena and Reggio Emilia, Modena; <sup>1</sup>Rheumatology Unit, Department of Internal Medicine, University of Pisa, Medical School, Pisa; <sup>2</sup>Department of Internal Medicine, University of Florence, Medical School, Florence, Italy.

Clodoveo Ferri, MD, Professor; Dilia Giuggioli, MD, Researcher; Massimiliano Cazzato, MD, Researcher; Marco Sebastiani, MD, Researcher; Maria Teresa Mascia, MD, Associate Professor; Anna Linda Zignego, MD, Professor.

Please address correspondence to: Prof. Clodoveo Ferri, MD, Reumatologia, Università di Modena e Reggio Emilia, Policlinico di Modena, Via del Pozzo no. 71, 41100 Modena, Italy.  
E-mail: clferri@unimo.it

Received on July 3, 2003; accepted in revised form on September 1, 2003.

*Clin Exp Rheumatol* 2003; 21 (Suppl. 31): S78-S84.

© Copyright CLINICAL AND EXPERIMENTAL RHEUMATOLOGY 2003.

**Key words:** Cryoglobulinemia, cryoglobulinemic vasculitis, hepatitis C virus.

### ABSTRACT

Cryoglobulinemic vasculitis (CV) is an immune-complex-mediated systemic vasculitis involving small-medium sized vessels. A causative role of hepatitis C virus (HCV) in over 4/5 patients has been definitely established on the basis of epidemiological, pathological, and laboratory studies. There is great geographical heterogeneity in the prevalence of CV as well as other HCV-related immuno-lymphoproliferative disorders. Thus, unknown environmental and/or genetic co-factors should contribute to the pathogenesis of these conditions. Due to its biological properties, HCV genomic sequences cannot be integrated into the host genome; the virus could trigger the immunological alterations only indirectly by exerting a chronic stimulus to the immune system. Recent laboratory observations gave us new important insights on the complex pathogenetic mechanism(s) of HCV-related CV. Firstly, the HCV envelop protein E2, able to bind CD81 molecule expressed on B-lymphocytes, might be involved in the first steps of HCV-driven autoimmune and lymphoproliferative phenomena. The interaction between HCV-E2 and CD81 may increase the frequency of VDJ rearrangement in antigen-reactive B-cell. One possible consequence may be the activation of anti-apoptotic Bcl-2 proto-oncogene that leads to extended B-cell survival. Interestingly, t(14, 18) translocation along with Bcl-2 activation have been demonstrated in B-lymphocytes of 80% HCV-related CV. The B-lymphocyte expansion is responsible for a wide autoantibody and immune-complex production, including mixed cryoglobulins.

CV shows a relatively benign clinical course; however, its cumulative survival is significantly worse if compared to general population. For a correct therapeutic approach to HCV-related

CV we must deal with conflicting conditions: HCV infection, autoimmune, and lymphoproliferative alterations. Therapeutic strategy of CV includes etiologic, pathogenetic, and/or symptomatic therapies, which should be tailored for the single patient according to the severity of clinical symptoms. A careful clinical monitoring of patients with HCV-related CV is mandatory in all cases, with particular attention to neoplastic complications.

### Cryoglobulinemic vasculitis

Cryoglobulinemia is defined as the presence of circulating immunoglobulins (Ig) that precipitate at temperatures below 37°C and redissolve on re-warming (1). Such an *in vitro* phenomenon is detectable in a wide number of chronic infectious and immunological disorders, as well as in some hematological malignancies (1-3).

Cryoglobulinemia is usually classified into three serological subsets according to the Ig composition of cryoprecipitates (4): monoclonal cryoglobulinemia (type I) composed by single monoclonal Ig; mixed cryoglobulinemia containing a mixture of polyclonal IgG and monoclonal (type II) or polyclonal (type III) IgM rheumatoid factor (RF). Type I cryoglobulinemia is frequently associated to a well known hematological disorder, such as Waldenström's macroglobulinaemia, multiple myeloma, immunocytoma; it is per se asymptomatic with the possible exception of the hyperviscosity syndrome.

Both type II and III mixed cryoglobulinemia (MC) can be classified as essential or secondary in the absence/presence of other well defined infectious, immunological or neoplastic diseases (1-5).

The so-called 'essential' MC was first described as distinct clinical syndrome in 1966 (5). MC is characterized by a

typical triad – purpura, weakness, arthralgias – and by multisystem organ involvement including chronic hepatitis, membranoproliferative glomerulonephritis (MPGN), peripheral neuropathy, skin ulcers, widespread vasculitis, and less frequently lymphatic and hepatic malignancies (2-6). Serological features of MC include a variety of circulating immune complexes, mainly mixed cryoglobulins with RF activity, and reduced hemolytic complement activity with markedly low C4 (2-7). Type II and type III MC do not differ with regard to clinical manifestations. However, the presence of monoclonal component in the cryoprecipitate, as well as among tissue lymphoid infiltrates, can suggest a rather oncogenic potential of type II MC, which in some individuals may evolve to malignant lymphoma (5,6). The analysis of cryoprecipitates is generally carried out by means of immunoelectrophoresis or immunofixation.

Using more sensitive methodologies, i.e. immunoblotting or 2-dimensional polyacrylamide gel electrophoresis, type II MC frequently shows a microheterogeneous composition (8). This particular subset, the type II-III MC composed of oligoclonal IgM or a mixture of polyclonal and monoclonal IgM, could fit together the most recent molecular studies showing the presence of oligoclonal B-lymphocyte proliferations in liver and bone marrow biopsies from MC patients (9-10). In two-thirds of type II MC cross-idiotype WA monoclonal RF has been demonstrated (3, 11). This WA (after the patient in whom it was first detected) almost invariably express a Vk light chain derived from a single germinal gene, the human KV 325 (3, 11). The same WA monoclonal IgMk RF has also been detected in type II MC secondary to lymphoid malignancies, probably expression of an antigen-independent clonal B-cell lymphoproliferation. The pathological hallmark of MC is a leukocytoclastic vasculitis, involving small and medium sized vessels responsible for cutaneous and visceral organ involvement (2-7). In the presence of the above clinico-serological and pathological alterations, the terms

MC and cryoglobulinemic vasculitis (CV) are referred to the same clinical syndrome.

CV is considered to be a relatively rare disorder; its prevalence among different countries shows a great geographical heterogeneity, being the disease more frequent in southern Europe than in northern Europe or North America (3-6). There are not available classification/diagnostic criteria for CV. In the clinical practice, the main diagnostic parameters are serum mixed cryoglobulins with RF activity, low C4, orthostatic skin purpura, and leukocytoclastic vasculitis of small/medium-sized blood vessels secondary to the deposition of circulating immune-complexes and complement (2-7). Diagnostic features may also include the presence of one or more organ involvement (peripheral nerves, renal and/or liver), as well as clonal B-lymphocyte expansion, which represents the underlying immune system alteration of the disease (2-7). Although cryoglobulin detection and characterization are necessary for a correct classification and diagnosis, the amount of serum cryoglobulins generally does not correlate with the severity/activity and prognosis of the disease (7).

#### *Etiopathogenesis of CV*

Given the frequent association between CV and liver involvement a causative role of hepatotropic viruses in the CV had long been hypothesized during the seventies (12-14), when a role of hepatitis B virus (HBV) in another systemic vasculitis – the polyarteritis nodosa – had been demonstrated (15). However, the presence of HBV antigenemia in patients with CV was seldom recorded (12-14); thus, HBV can represent an etiological factor of CV in a minority of individuals, probably less than 5% (6). Soon after its identification (16), a role of hepatitis C virus (HCV) in CV has been suggested by two preliminary studies reporting the presence of antibodies against HCV in a significant percentage of patients (17, 18). These initial observations were strongly supported by a virological study (19) on a large series of CV patients showing the presence of HCV viremia in the major-

ity of cases (86%). The prevalent role of HCV infection in CV has been definitely established during the last decade on the basis of epidemiological, pathological, and laboratory investigations (6, 19-24). In particular, immunohistochemical and molecular biology studies, including HCV RNA detection by *in situ* hybridisation in different target tissues, have reinforced the hypothesis of a direct involvement of HCV in the immune-complex-mediated vasculitic lesions, as well as in the underlying lymphoproliferative disorder (21-24). Being HCV the main triggering factor of CV the term 'essential' is no longer appropriate for the majority of cases (6, 21-24).

HCV has been recognized to be both hepato- and lymphotropic virus; in particular, the HCV lymphotropism has been demonstrated by the detection of active or latent viral replication in the peripheral lymphocytes from patients with type C hepatitis and/or CV (25, 26). Of interest, the infection of lymphoid tissue may explain the appearance of a constellation of autoimmune and lymphoproliferative disorders in chronically HCV-infected individuals (6, 22, 25, 26).

HCV-related types III and II MC are comparable with regard their organ involvement and clinical course, with the exception of their potential evolution to malignancy (6, 22). Although not definitely demonstrated, they might represent two different steps of the same disorder (Fig.1): MC type III may evolve to benign lymphoproliferative disorder, the mono- oligoclonal B-cell proliferation of MC type II, which in some individuals can be complicated by frank B-cell non-Hodgkin's lymphoma (NHL), usually after a long-term follow-up period (6,22). Circulating mixed cryoglobulins are frequently detectable in HCV-infected individuals (50%); whereas, overt CV develops in only a minority of cases (5%) (6,27, 28). HCV infection presents a homogeneous diffusion worldwide, which contrasts with the geographical heterogeneity in the prevalence of HCV-related CV as well as other immune system disorders (6). The involvement of particular HCV genotypes, environmental and/or host genet-

ic factors should contribute to the pathogenesis of CV; however, the actual role of the above co-factors remains still to be demonstrated (6, 22, 29, 30).

The above considerations suggest that HCV *per se* might be insufficient to drive the different autoimmune-lymphoproliferative disorders observed in infected individuals. In addition, HCV is a positive, single-stranded RNA virus without a DNA intermediate in its replicative cycle, so that viral genomic sequences cannot be integrated into the host genome. It is supposable that HCV infection exerts a chronic stimulus to the immune system, which facilitates clonal B-lymphocyte expansion (6, 22). More recent laboratory observations gave us new interesting insights on the complex pathogenetic mechanisms of HCV-related immunological disorders. Firstly, the presence of t(14; 18) translocation leading to Bcl-2 activation has been demonstrated in a significant percentage of peripheral blood lymphocytes in HCV-infected individuals, particularly in those with CV in the setting of type II mixed cryoglobulinemia (31-33). Besides, the identification of HCV envelop protein E2 able to bind CD81 molecule expressed on

both hepatocytes and B-lymphocytes (34) could help to clarify the first steps of HCV-driven autoimmunity (Fig. 1). The CD81 is a cell-surface protein that, on B-cell, is part of a complex with CD21, CD19, and Leu 13. This complex reduces the threshold for B-cell activation by bridging antigen specific recognition and CD21-mediated complement recognition. The interaction between HCV-E2 and CD81 might increase the frequency of VDJ rearrangement in antigen-reactive B-cell (Fig. 1). One possible consequence could be the above mentioned bcl-2 activation observed in HCV-related diseases, mainly CV (31-33). Bcl-2 proto-oncogene is able to inhibit the apoptosis leading to extended cell survival (35). The consequent B-lymphocyte expansion may be responsible for the wide autoantibody production observed in HCV-infected individuals (6, 22, 27, 28, 36).

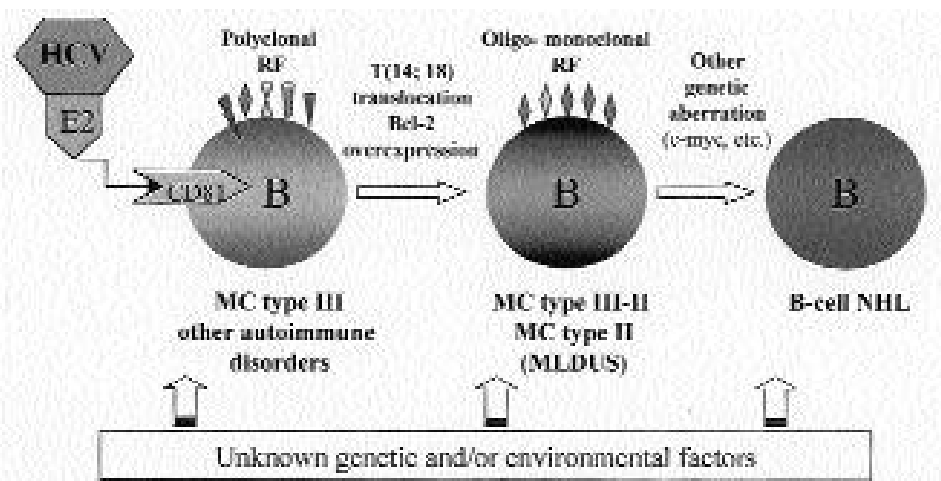
Other mechanisms such as molecular mimicry involving particular HCV antigens and host autoantigens can be involved in B lymphocyte activation and autoantibody production (6). On the other hand, prolonged B-cell survival can expose these cells to other genetic aberrations (6, 37) leading in

some individuals to overt malignant lymphoma (Fig. 1). HCV exerts a well-known oncogenic potential as definitely demonstrated for hepatocellular carcinoma; the same virus seems to be also involved in the lymphomagenesis and, possibly, in other malignancies such as thyroid cancer (38, 39).

Very recently, a role of both non-structural 5A (NS5A) and HCV core proteins in the pathogenesis of HCV-related disorders has been suggested by two distinct studies (40-41). The HCV NS5A protein modulates TNF signaling of the host cells, while HCV core protein has different effects on the Janus kinase (JAK)-signal transducer and activator transcription factor (STAT) pathway under interleukin-6 and interferon-gamma stimuli (40, 41). If confirmed, these preliminary results further support the above-mentioned hypothesis that HCV may be able to deeply dysregulate the immune system activity.

#### Therapeutic strategies of CV

The severity/activity and outcome of CV largely vary among patients; similarly, the disease behavior is often unpredictable in a given patient during



**Fig. 1.** Different immunophenotypes of mixed cryoglobulinemia: MC type III characterized by polyclonal rheumatoid factors and other autoantibodies; MC type III-II with a microheterogeneous composition (oligoclonal IgM or a mixture of poly-/monoclonal IgM); MC type II with a monoclonal component is frequently associated to monotypic lymphoproliferative disorder of undetermined significance (MLDUS); this is an indolent lymphoproliferative disorder that can be complicated by malignant B-cell non-Hodgkin's lymphoma (NHL).

Hepatitis C virus (HCV) envelop protein E2 binds CD81 molecule expressed on B-lymphocytes, the interaction HCV-E2/CD81 may reduce the threshold for B-cell activation. T(14; 18) translocation leads to the activation of anti-apoptotic protein Bcl-2.

The activation of other oncogenes (c-myc, etc.) should be involved in HCV-driven lymphomagenesis with the possible contribution of unknown genetic and environmental factors.

the follow-up (6). Usually, CV shows a relatively benign clinical course; it is often oligosymptomatic for long time intervals being characterized by mild weakness, arthralgias, and periodic flares of orthostatic purpura. However, in some patients the quality of life is particularly poor, especially in the presence of paresthesias due to peripheral sensory neuropathy. In other cases CV may start with or may be studied by one or more complications such as nephritic syndrome, sensory-motor peripheral neuropathy, widespread vasculitis, chronic hepatitis with or without cirrhosis, and/or neoplastic complications (6). The cumulative survival of MC shows a significantly worse prognosis if compared to the general population (42). In MC patients a possible evolution of the immune-mediated vascular damage to atherosclerosis should be taken in account. The atherosclerotic process might also be the result of other predisposing co-factors. In particular, the long-term steroid treatment, frequently administered to MC patients with moderate-severe clinical course, as well as the male gender, which is characterized by significantly worse prognosis (42).

Overall, the treatment of CV syndrome

is particularly challenging because of its complex etiopathogenesis (6). For a correct therapeutic approach to HCV-related CV we must deal with concomitant, conflicting conditions: HCV infection, autoimmune, and lymphoproliferative alterations. Following the pathogenetic process leading from HCV infection to CV (Fig. 2) we can treat the disease at three different levels by means of etiologic, pathogenetic, and/or symptomatic therapies. Since HCV represents the triggering factor of the disease and probably exerts a chronic stimulus on the immune system (Fig. 1 and Fig. 2), an attempt at HCV eradication should be done in all cases of HCV-associated CV.

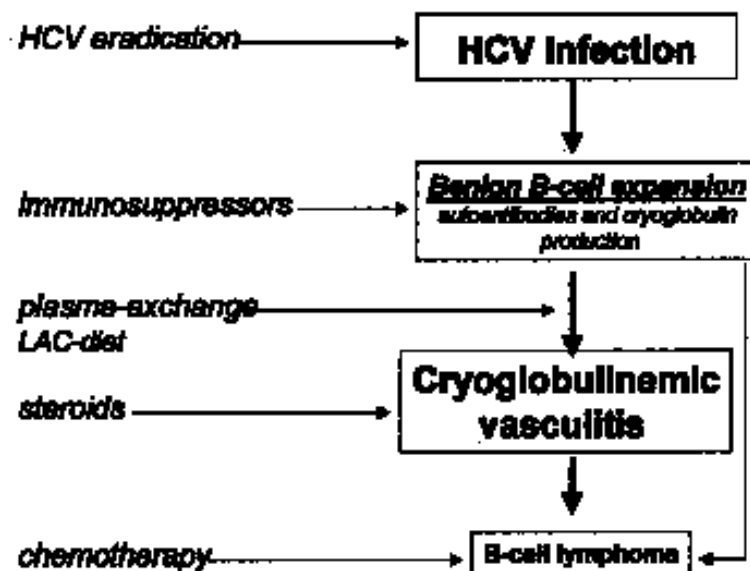
In this respect encouraging data came from some preliminary observations: in patients with CV repeated bone-marrow biopsies, before/after interferon therapy, showed a regression of indolent lymphoid infiltrates along with clinical improvement and HCV clearance (43). More recently, it has been observed that alpha-interferon/ribavirin combined therapy may induce the regression of t(14;18) bearing B-cell clones in HCV-positive patients (44). These observations suggest that antiviral therapy may improve or treat the

immune-lymphoproliferative disorder underlying the CV. However, HCV eradication is usually obtained in a small percentage of treated patients, while the clinical usefulness of antiviral treatment is often transient and not rarely associated with important immune-mediated complications (45-51). In particular, interferon may trigger or severely worsen the peripheral sensory-motor neuropathy (45,49, 50). Since there are no predictive parameters available for this harmful complication, interferon therapy should be avoided at least in those patients with clinically evident peripheral neuropathy.

Other important manifestations observable during alpha-interferon in patients with type C hepatitis and/or CV are rheumatoid-like polyarthritis, thyroid disorders, and erectile dysfunction (6, 52-54). It is supposable that in predisposed subjects, alpha-interferon, both an antiviral and immunomodulating agent, can trigger or exacerbate some pre-existing, often subclinical, symptoms (48-54). On the whole, the usefulness of alpha-interferon treatment in CV is limited by the low rate of responders and frequent side effects. Possibly the association of interferon and ribavirin might achieve the eradication of HCV infection in a rather significant number of treated subjects, as recently demonstrated in patients with type C chronic hepatitis and/or CV (55-57). Controlled clinical trials are necessary to definitely evaluate the usefulness of this antiviral therapy in HCV-related CV.

Hopefully, a vaccine against HCV may become available in the near future. One possible strategy is to interfere with the binding between HCV envelope protein E2 and CD81 on both hepatocytes and lymphocytes (58). In HCV-infected individuals a vaccine-based therapy with recombinant HCV proteins (36, 58) could be able to prevent the evolution from HCV infection to both hepatic and extra-hepatic complications, including CV, and could possibly interrupt the self-perpetuating autoimmune mechanism of this disease.

Corticosteroids alone or in association with immunosuppressors may represent the first-line intervention in the few cases of 'essential' CV. While in



**Fig. 2.** Etiopathogenic process of HCV-related cryoglobulinemic vasculitis and therapeutic interventions. Mixed cryoglobulinaemia is a combination of three main clinico-pathological alterations: chronic HCV infection, B-lymphocyte proliferation, immune-complex-mediated vasculitis. We can treat the disease at different levels by means of - etiologic, pathogenetic, and symptomatic - often combined therapies. LAC-diet: low-antigen-content diet.

HCV-related CV an attempt with the above treatments should be considered particularly in those patients who have failed to respond to alpha-interferon, or when this drug is contraindicated. An immunosuppressive treatment with cyclophosphamide often in association with steroids, and/or plasma exchange may be able to treat some severe MC complications such as nephropathy, sensory-motor neuropathy, or widespread vasculitis (2,6,59,60). Both traditional and double-filtration plasma exchange are able to achieve a dramatic reduction of circulating immune-complex levels, including the cryoglobulins, as well as the viral loading (6, 61). The beneficial effect of such 'symptomatic' treatment can be reinforced by means of oral cyclophosphamide during the slow tapering and after the discontinuation of apheresis sessions (50-100 mg/day for 4-8 weeks). In particular, the immunosuppressor can prevent the rebound phenomena that may be observed after the apheresis discontinuation. Plasma exchange is useful in CV patients with severe manifestations, particularly on active cryoglobulinemic nephropathy (59, 60). Low-antigen-content diet (LAC-diet) has been employed in some immune-complex-mediated disorders, namely CV and IgA-nephropathy (62, 63). In CV patients, this particular dietetic treatment can improve the serum clearance of immune-complexes by restoring the activity of the reticulo-endothelial system, overloaded by large amounts of circulating cryoglobulins (62). Low dosage of steroids and/or LAC-diet may be sufficient to improve mild-moderate manifestations of CV, i.e. purpura, arthralgias, peripheral sensory neuropathy, and etc. (6).

More recently, a pathogenetic treatment with rituximab, a monoclonal chimeric antibody that binds to the B-cell surface antigen CD20, has been proposed in HCV-positive CV patients (64, 65). After the selective B-cell blockade a clinico-serological improvement of CV was observed; of interest, it has been noticed that serum HCV RNA increased approximately twice the baseline levels in the responders (65). The long-term efficacy and safety of ritux-

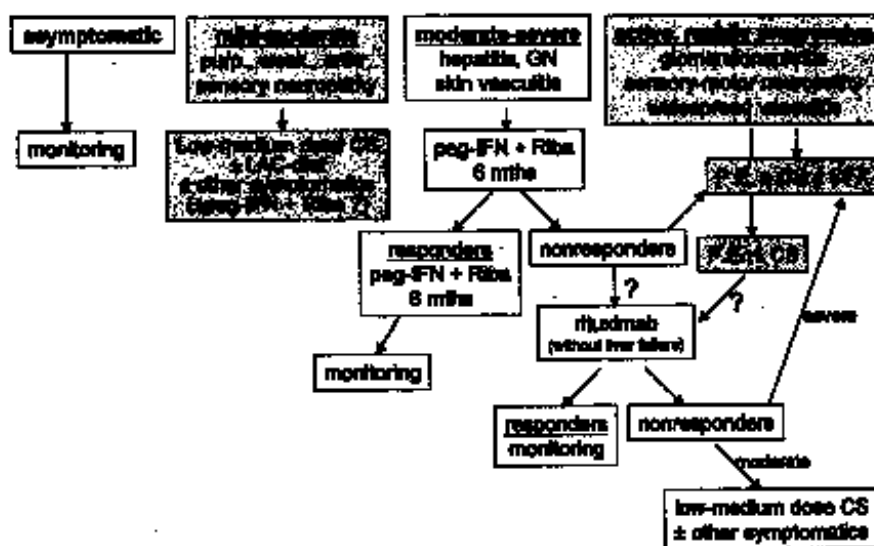


Fig. 3. Therapeutic strategies of HCV-related cryoglobulinemic vasculitis.

Purp.: purpura; weak.: weakness; arthr.: arthralgias; CS: corticosteroids; LAC-diet: low-antigen-content-diet; peg-IFN: pegylated interferon; Ribav: ribavirin; GN: glomerulonephritis; P.E.: plasma exchange; CFX: cyclophosphamide.

imab need to be investigated by controlled clinical trials. Usually, the treatment with cytotoxic drugs (cyclophosphamide) seems do not affect the progression of HCV infection and, in particular, the liver involvement. However, the impact of rituximab on HCV viremia (65), if confirmed, suggests the possible use of combined therapy with immunosuppressor and antiviral agents. On the whole, the treatment of CV should be tailored for the single patient according to the severity of clinical symptoms (Fig.3). During the asymptomatic phases of the disease patients usually do not need any treatment, even in the presence of high levels of cryocrit. While mild-moderate symptoms, such as palpable purpura, are particularly sensitive to the smallest variations of daily steroid dosage (1-2 mg). Peg-interferon/ribavirin may represent the choice treatment in patients with moderate-severe CV manifestations, especially in those with active hepatitis. On the contrary, severe, life-threatening vasculitic manifestations must be promptly treated with a combined therapy based on plasma exchange, high doses of steroids, and/or immunosuppressors (Fig. 3). A careful clinical monitoring of the disease is mandatory in all cases, with particular attention to neoplastic complications.

## References

- LOSPALLUTO J, DORWARD B, MILLER W JR, ZIFF M: Cryoglobulinemia based on interaction between a gamma macroglobulin and 7S gammaglobulin. *Am J Med* 1962; 32: 142-5.
- GOREVIC PD, KASSAB HJ, LEVO Y *et al.*: Mixed cryoglobulinemia: Clinical aspects and long-term follow-up of 40 patients. *Am J Med* 1980; 69: 287-308.
- GOREVIC PD, FRANGIONE B: Mixed cryoglobulinemia cross-reactive idiotypes: implication for relationship of MC to rheumatic and lymphoproliferative diseases. *Semin Hematol* 1991; 28: 79-94.
- BROUET JC, CLOUVEL JP, DANON F, KLEIN M, SELIGMANN M: Biologic and clinical significance of cryoglobulins. *Am J Med* 1974; 57: 775-88.
- MELTZER M, FRANKLIN EC, ELIAS K, MCCLUSKEY RT, COOPER N: Cryoglobulinemia. A clinical and laboratory study. II. Cryoglobulins with rheumatoid factor activity. *Am J Med* 1966; 40: 837-56.
- FERRI C, ZIGNEGO AL, PILERI SA: Cryoglobulins. *J Clin Pathol* 2002; 55: 4-13 (review).
- BOMBARDIERI S, FERRI C, MIGLIORINI P *et al.*: Cryoglobulins and immune complexes in essential mixed cryoglobulinemia. *La Ricerca Clin Lab* 1986; 16: 281-8.
- TISSOT JD, SCHIFFERLI JA, HOCHSTRASSER DF *et al.*: Two-dimensional polyacrylamide gel electrophoresis analysis of cryoglobulins and identification of an IgM-associated peptide. *J Immunol Methods* 1994; 173: 63-75.
- MAGALINI AR, FACCHETTI F, SALVI L, FONTANA M, PUOTI M, SCARPA A: Clonality of B-cells in portal lymphoid infiltrates of HCV-infected livers. *J Pathol* 1998; 185: 86-90.
- DE VITA S, DE RE V, GASPAROTTO D *et al.*:

- Type II mixed cryoglobulinemia is a non-malignant B-cell disorder. Clinical and molecular findings do not support bone marrow pathologic diagnosis of low grade B-cell lymphoma. *Arthritis Rheum* 2000; 43: 94-102.
11. ABEL G, ZHANG QX, AGNELLO V: Hepatitis C virus infection in type II mixed cryoglobulinemia (review). *Arthritis Rheum* 1993; 36: 1341-9.
  12. BOMBARDIERI S, FERRI C, DI MUNNO O, PASERO G: Liver involvement in essential mixed cryoglobulinemia. *La Ricerca Clin Lab* 1979; 9: 361-8.
  13. LEVO Y, GOREVIC PD, KASSAB HJ, ZUCKER-FRANKLIN D, FRANKLIN EC: Association between hepatitis B virus and essential mixed cryoglobulinemia. *N Engl J Med* 1977; 296: 1501-4.
  14. POPP JW, DIENSTAG JL, WANDS JR, BLOCH KJ: Essential mixed cryoglobulinemia without evidence for hepatitis B virus infection. *Ann Intern Med* 1980; 92: 379-83.
  15. GOCKE DJ, HSU K, MORGAN C, BOMBARDIERI S, LOCKSHIN M, CHRISTIAN CL: Association between polyarteritis and Australia antigen. *Lancet* 1970; 2: 1149-53.
  16. CHOO GL, KUO G, WEINER AJ, OVERBYLR, BRADLEY DW, HOUGHTON M: Isolation of a cDNA clone derived from a blood-borne non-A, non-B viral hepatitis genome. *Science* 1989; 244: 359-61.
  17. PASCUAL M, PERRIN L, GIOSTRA E, SCHIFFER JA: Hepatitis C virus in patients with cryoglobulinemia type II. *J Infect Dis* 1990; 162: 569-70.
  18. FERRI C, MARZO E, LONGOMBARDO G, LOMBARDINI F, GRECO F, BOMBARDIERI S: Alpha-interferon in the treatment of mixed cryoglobulinemia patients. Proceedings of the International Cancer Update. Focus on Interferon Alfa 2b (Cannes, France, 1-4 November 1990) *Eur J Cancer* 1991; 27: 81-2.
  19. FERRI C, GRECO F, LONGOMBARDO G *et al.*: Association between hepatitis C virus and mixed cryoglobulinaemia. *Clin Exp Rheumatol* 1991; 9: 621-4.
  20. AGNELLO V, CHUNG RT, KAPLAN LM: A role for hepatitis C virus infection in type II cryoglobulinemia. *N Engl J Med* 1992; 327: 1490-5.
  21. FERRI C, LA CIVITA L, LONGOMBARDO G, GRECO F, BOMBARDIERI S: Hepatitis C virus and mixed cryoglobulinemia (review). *Eur J Clin Invest* 1993; 23: 399-405.
  22. FERRI C, PILERI S, ZIGNEGO AL: Hepatitis C virus, B-cell disorders, and non-Hodgkin's lymphoma. In GOEDERT JJ (Ed.): *Infectious Causes of Cancer. Targets for Intervention*. Totowa (NJ) National Cancer Institute (NIH), *The Humana Press Inc.* 2000, Chapter 19; 349-368.
  23. SANSONNO D, DE VITA S, CORNACCHIULO V, CARBONE A, BAIOCCHI M, DAMMACCO F: Detection and distribution of hepatitis C-related proteins in lymph nodes of patients with type II cryoglobulinemia and neoplastic or non-neoplastic lymphoproliferation. *Blood* 1996; 88: 4638-45.
  24. AGNELLO V, ABEL G: Localization of hepatitis C virus in cutaneous vasculitic lesions in patients with type II cryoglobulinemia. *Arthritis Rheum* 1997; 40: 2007-15.
  25. ZIGNEGO AL, MACCHIA D, MONTI M *et al.*: Infection of peripheral mononuclear blood cells by hepatitis C virus. *J Hepatol* 1992; 15: 382-6.
  26. FERRI C, MONTI M, LA CIVITA L *et al.*: Infection of peripheral blood mononuclear cells by hepatitis C virus in mixed cryoglobulinemia. *Blood* 1993; 82: 3701-4.
  27. LUNEL F, MUSSET L, CACOUB P *et al.*: Cryoglobulinemia in chronic liver diseases: role of hepatitis C virus and liver damage. *Gastroenterology* 1994; 106: 1291-300.
  28. PAWLOTSKY J, MUSTAPHA B, ANDRE C *et al.*: Immunological disorders in C virus chronic active hepatitis: A prospective case-control study. *Hepatology* 1994; 19: 841-8.
  29. ZIGNEGO AL, FERRI C, GIANNINI C *et al.*: Hepatitis C virus genotype analysis in patients with type II mixed cryoglobulinemia. *Ann Intern Med* 1996; 124: 31-4.
  30. LENZI M, FRISONI M, MANTOVANI V *et al.*: Haplotype HLA-B8-DR3 confers susceptibility to hepatitis C virus-related mixed cryoglobulinemia. *Blood* 1998; 91: 2062-6.
  31. ZIGNEGO AL, GIANNELLI F, MARROCCHI ME *et al.*: T(14;18) translocation in chronic hepatitis C virus infection. *Hepatology* 2000; 31: 474-9.
  32. ZIGNEGO AL, FERRI C, GIANNELLI F *et al.*: Prevalence of bcl-2 rearrangement in patients with hepatitis C virus-related mixed cryoglobulinemia with or without B-cell lymphomas. *Ann Intern Med* 2002; 137: 571-80.
  33. KITAY-COHEN Y, AMIEL A, HILZENRAT N *et al.*: Bcl-2 rearrangement in patients with chronic hepatitis C associated with essential mixed cryoglobulinemia type II. *Blood* 2000; 96: 2910-2.
  34. PILERI P, UEMATSU Y, CAMPAGNOLIS *et al.*: Binding of hepatitis C virus to CD81. *Science* 1998; 282: 938-41.
  35. KORSMEYER SJ: Bcl-2: a repressor of lymphocyte death. *Immunol Today* 1992; 13: 285-7.
  36. LENZI M, JOHNSON PJ, MCFARLANE IG *et al.*: Antibodies to hepatitis C virus in autoimmune liver disease: evidence for geographical heterogeneity. *Lancet* 1991; 338ii: 277-80.
  37. ELLIS M, RATHAUS M, AMIELA, MANOR Y, KLEIN A, LISHNER M: Monoclonal lymphocyte proliferation and bcl-2 rearrangement in essential mixed cryoglobulinaemia. *Eur J Clin Invest* 1995; 25: 833-7.
  38. ANTONELLI A, FERRI C, FALLAHI P: Thyroid cancer in patients with hepatitis C infection. *JAMA* 1999; 281: 1588.
  39. ANTONELLI A, FERRI C, FALLAHI P, NESTI C, ZIGNEGO AL, MACCHERONI M: Thyroid cancer in HCV-related mixed cryoglobulinemia patients. *Clin Exp Rheumatol* 2002; 20: 693-6.
  40. PARK KJ, CHOI SH, CHOI DH *et al.*: Hepatitis C virus NS5A protein modulates c-Jun N-terminal kinase through interaction with TNF receptor-associated factor 2. *J Biol Chem* 2003; June 7 [E-pub ahead of print].
  41. HOSUI A, OHKAWA K, ISHIDA H *et al.*: Hepatitis C virus core protein differentially regulates the JAK-STAT signaling pathway under interleukin-6 and interferon-gamma stimuli. *J Biol Chem* 2003; 278: 28562-71.
  42. FERRI C, SEBASTIANI M, GIUGGIOLI D *et al.*: Mixed cryoglobulinemia: Demographic, clinical, and serological features, and survival in 231 patients. *Semin Arthritis Rheum* (in press).
  43. MAZZARO C, FRANZIN F, TULISSI P *et al.*: Regression of monoclonal B-cell expansion in patients affected by mixed cryoglobulinemia responsive to -interferon therapy. *Cancer* 1996; 77: 2604-13.
  44. GIANNELLI F, MOSCARELLA S, GIANNINI C *et al.*: Effect of antiviral treatment in patients with chronic HCV infection and t(14;18) translocation. *Blood* 2003; 102 (in press August 2003).
  45. FERRI C, MARZO E, LONGOMBARDO G *et al.*: Alpha-Interferon in mixed cryoglobulinemia patients: A randomized crossover controlled trial. *Blood* 1993; 81: 1132-6.
  46. MISIANI R, BELLAVITA P, FENILI D *et al.*: Interferon alfa-2a therapy in cryoglobulinemia associated with hepatitis C virus. *N Engl J Med* 1994; 330: 751-6.
  47. CASATO M, LAGANA B, ANTONELLI G, DIANZANI F, BONOMO L: Long-term results of therapy with interferon-alpha for type II essential mixed cryoglobulinemia. *Blood* 1991; 78: 3142-7.
  48. DI LULLO L, DE ROSA FG, COVIELLO R *et al.*: Interferon toxicity in hepatitis C virus-associated type II cryoglobulinemia. *Clin Exp Rheumatol* 1998; 16: 506.
  49. LA CIVITA L, ZIGNEGO AL, LOMBARDINI F *et al.*: Exacerbation of peripheral neuropathy during alpha-interferon therapy in a patient with mixed cryoglobulinemia and hepatitis B virus infection. *J Rheumatol* 1996; 23: 1641-3.
  50. LIDOVE O, CACOUB P, HAUSFATER P *et al.*: Cryoglobulinemia and hepatitis C: worsening of peripheral neuropathy after interferon alpha treatment. *Gastroenterol Clin Biol* 1999; 23: 403-6.
  51. CID MC, HERNANDEZ-RODRIGUEZ J, ROBERT J *et al.*: Interferon-alpha may exacerbate cryoglobulinemia-related ischemic manifestations: an adverse effect potentially related to its anti-angiogenic activity. *Arthritis Rheum* 1999; 42: 1051-5.
  52. BUSKILA D: Hepatitis C-associated arthritis. *Curr Opin Rheumatol* 2000; 12: 295-9 (review).
  53. FADDA P, LA CIVITA L, ZIGNEGO AL, FERRI C: Hepatitis C virus infection and arthritis. A clinico-serological investigation of arthritis in patients with or without cryoglobulinemic syndrome. *Reumatismo* 2002; 54: 316-23.
  54. FERRI C, BERTOZZI MA, ZIGNEGO AL: Erectile dysfunction and hepatitis C virus infection. *JAMA* 2002; 288 :698-9.
  55. MCHUTCHISON JG, GORDON SC, SCHIFFER *et al.*: Interferon alpha-2b alone or in combination with ribavirin as initial treatment for chronic hepatitis C. Hepatitis Interventional Therapy Group. *N Engl J Med* 1998; 339: 1485-92.
  56. MISIANI R, BELLAVITA P, BAILO P *et al.*: Successful treatment of HCV-associated cryoglobulinemic glomerulonephritis with a combination of interferon-alpha and rib-

- avirin. *Nephrol Dial Transplant* 1999; 14: 1558-60.
57. ZUCKERMAN E, KEREN D, SLOBODIN G *et al.*: Treatment of refractory, symptomatic, hepatitis C virus related mixed cryoglobulinemia with ribavirin and interferon-alpha. *J Rheumatol* 2000; 27: 2172-8.
58. ABRIGNANI S, ROSA D: Perspectives for a hepatitis C virus vaccine. *Clin Diagn Virol* 1998; 10: 181-5.
59. FERRI C, MORICONI L, GREMIGNAI G *et al.*: Treatment of renal involvement in essential mixed cryoglobulinemia with prolonged plasma exchange. *Nephron* 1986; 43, 246-51.
60. MORICONI L, FERRI C, PUCCINI R *et al.*: Double filtration plasmapheresis in the treatment of cryoglobulinemic glomerulonephritis. *Int J Art Org* 1989; 12/S4: 83-6.
61. KAPLAN AA: Apheresis for renal disease. *Ther Apher* 2001; 5: 134-41 (review).
62. FERRI C, PIETROGRANDE M, CECCHETTI C *et al.*: Low-antigen-content diet in the treatment of mixed cryoglobulinemia patients. *Am J Med* 1989; 87: 519-24.
63. FERRI C, PUCCINI R, LONGOMBARDO G *et al.*: Low-antigen-content diet in the treatment of patients with IgA nephropathy. *Nephrol Dial Transpl* 1993; 8: 1193-8.
64. ZAJA F, DE VITA S, MAZZARO C *et al.*: Efficacy and safety of rituximab in type II mixed cryoglobulinemia. *Blood* 2003; 101: 3827-34.
65. SANSONNO D, DE RE V, LAULETTA G, TUCCI FA, BOIOCCHI M, DAMMACCO F: Monoclonal antibody treatment of mixed cryoglobulinemia resistant to interferon alpha with an anti-CD20. *Blood* 2003; 101: 3818-26.