

Case report

Visceral leishmaniasis in a patient treated for polyarteritis nodosa

P. Scatena¹, F. Messina², S. Gori³, L. Ruocco³, C. Vignali⁴, F. Menichetti², M. Castiglioni¹

¹Department of Medicine IV; ²Department of Infective Diseases; ³Test Analysis Laboratory; and ⁴Department of Radiodiagnosis I, Azienda Ospedaliera Pisana, Pisa, Italy
Paola Scatena, MD; Francesco Messina, MD; Serena Gori, Biologist; Lucia Ruocco, MD; Claudio Vignali, MD; Francesco Menichetti MD; Maida Castiglioni, MD.

Please address correspondence and reprint requests to: Dr Paola Scatena, U.O. Medicina IV, Azienda Ospedaliera Pisana, Cisanello, via Paradisa 2, 56100 Pisa, Italy. E-mail: brulenz@tin.it

Received on April 23, 2002; accepted in revised form on October 14, 2002.

Clin Exp Rheumatol 2003; 21 (Supp. 32): S121-S123.

© Copyright CLINICAL AND EXPERIMENTAL RHEUMATOLOGY 2003.

Key words: Visceral leishmaniasis, polyarteritis nodosa, vasculitis.

ABSTRACT

We report a case of visceral leishmaniasis in a patient receiving steroids and cyclophosphamide for polyarteritis nodosa. The clinical presentation of leishmaniasis, with fever, pancytopenia and hypergammaglobulinemia may be confused with a reactivation of vasculitis or with other non-infectious conditions such as haematologic diseases.

In endemic areas, the case of latent leishmaniasis must be considered and serology for *Leishmania* should be performed before starting immunosuppressive treatment.

Introduction

Polyarteritis nodosa (PA) is a systemic vasculitides characterised by inflammation and necrosis of blood vessel walls. Blood vessels of all size may be implicated in the vasculitic process, especially those of kidney, liver, heart and mesenteric supply. PA is uncommon; it may be observed in children and the elderly, but is more common in middle age, and twice as common in men. It may be associated with HBV infection, rarely with HCV, HIV, CMV, Parvovirus B19, and HTLV I infections. Reports suggest an immunologic pathogenesis for PA and steroids and immunosuppressive agents are the treatment of choice (1, 2).

Visceral leishmaniasis (VL) is a systemic infection caused by the intracellular protozoa of the *L. donovani* complex. Leishmaniasis is endemic in tropical and subtropical areas in Latin America and in the Mediterranean basin. In this latter area, transmission is by *Phlebotomus* species, while rodents such as the black rat and dogs are the reservoirs. The incubation period is variable, but usually range from 2 to 6 months. Classic VL is characterized by fever, pancytopenia, hepatosplenomegaly, hypergammaglobulinemia (3).

Case report

A 60-year-old man, born and living in Sicily, an area with endemic leishmaniasis, without any clinical history of parasitic infection, was admitted into the Neurological Unit of S. Chiara Hospital, Pisa at the end of the August 2000 because of legs pain, weakness and wasting. The initial physical evaluation revealed hypoesthesia and hyporeflexia in both legs, and findings of peripheral neuropathy was documented at the ENG/EMG examination. A diagnosis of axonal neuropathy was tentatively done. Few days later, due to a coexisting anaemia, the patient was transferred to the Internal Medicine Department

Physical examination confirmed the clinical findings of peripheral neuropathy; the spleen was normal and lymphonodes were not enlarged. Laboratory tests showed an erythrocyte sedimentation rate of 132 mm/1 hour, a white cell count of 14,100 cells/mm³ with 85% neutrophils and 10% lymphocytes, normal platelet count, slight anemia (Hb 10.4g%, MCV 79 µc) with raised levels of ferritinemia (1,370 ng/ml) and renal failure (urea nitrogen 208 mg%, creatinine 4.30 mg%). ANA, ENA, ANCA, cryoglobulins, antibodies against *B. burgdorferi*, HIV, HCV, hepatitis B surface antigen were negative. Muscle enzyme levels, thyroid function tests and urine were normal. Bone marrow biopsy revealed only significant iron storage.

Two days after the admission the patient presented haematemesis due to hemorrhagic gastritis according to endoscopy and pericardial friction rubs with typical ECG findings of pericarditis. Fourteen days later, the patient presented abdominal pain and ultrasonographic examination of the abdomen revealed an hematoma around the right kidney. A contrast enhanced CT scan

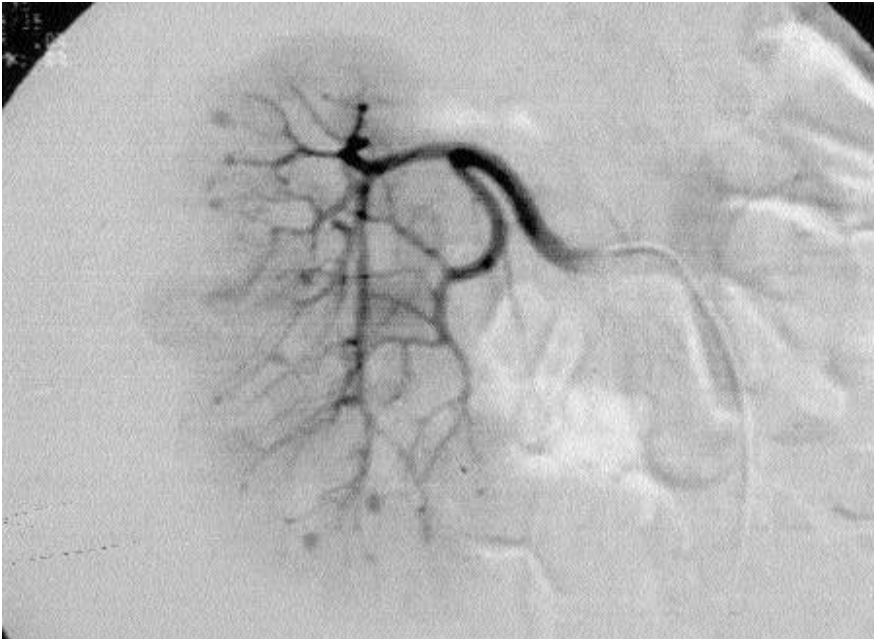

Fig. 1. Selective renal arteriography shows multiple sacciform aneurysms in the right kidney.

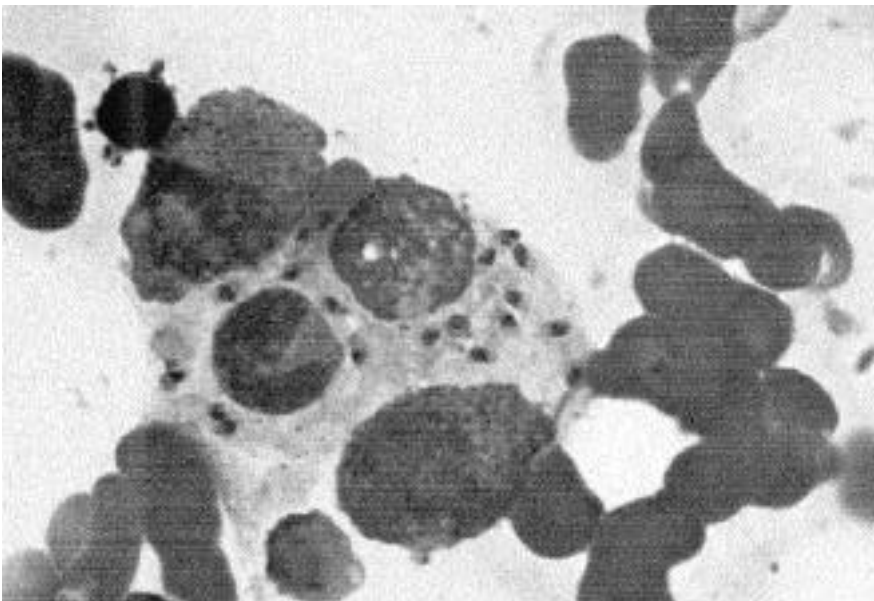


Fig. 2. Amastigotes of *Leishmania* spp in macrophage. Bone marrow aspirate (Giemsa, x630)

and a selective renal arteriography showed multiple sacciform aneurysms in the kidneys (Fig. 1). The hematoma was related to the rupture of a small aneurysm then embolized with metal coils.

On the basis of these findings the diagnosis of polyarteritis nodosa was done and the patient was treated with methylprednisolone 1g e.v. every day for 3 days, then 1 mg/Kg/die for one month followed by progressive reduction of the dose. Cyclophosphamide 500 mg

e.v. was administered monthly. A significant improvement (resolution of pericarditis, improvement of neuropathy with rescue of deambulation, improvement of renal failure (urea nitrogen 93 mg%, creatinine 1.45 mg%)) was obtained and after 20 days of treatment the patient was discharged from hospital and returned home to Sicily.

Two months later the patient presented with spiking fever (up to 39°C) and several ecchymotic skin lesions. Following these new clinical manifesta-

tions patient was again admitted to our Unit. On the admission, physical examination revealed worsened general conditions, hepatosplenomegaly, multiple ecchymotic and purpuric skin lesions. The hemoglobin level was 6.6 g/dl, the white blood cells count was 2,100/mm³, platelet count was 36,000/mm³, ferritinemia was 138,000 ng/ml, albumin was 2.6 g%, gammaglobulin was 24%, and ESR was 114 mm/1 hour.

Cultures of blood and urine, Widal test and seroagglutination test for *Brucella* were negative. The newly developed pancytopenia suggested a bone marrow aspirate that revealed amastigotes of *Leishmania* spp in macrophages (Fig. 2). Serodiagnosis for *Leishmania* (IFA) was positive (Ig titre: 1:640). The re-examination of previous marrow biopsy resulted negative for the presence of amastigotes.

The patient was treated with liposomal amphotericin B 3 mg/Kg (180 mg) i.v. for five days then again on day 14 and day 21. The follow-up evaluation two months later showed resolution of pancytopenia and splenomegaly. Unexpectedly, the patient died due to a CT-documented intra-cerebral hemorrhage one month later in another hospital.

Discussion

VL is endemic in many Italian regions: Campania, Puglia, Sicilia, Sardegna, Toscana. *L. infantum* is the species more commonly encountered, children less than 6 years-old are most frequently affected, *Phlebotomus perniciosus*, *P. ariasi* and *P. major* are the vectors; dogs, foxes and black rats are the reservoirs of infection (4). Although the inapparent/overt infection ratio is about 10/1, in recent years *Leishmania* has become an important opportunistic pathogen in immunocompromised people. After acute or subclinical *Leishmania* infection, the parasite survives in a latent form in the organism without causing clinical manifestations of disease, unless HIV infection or immunosuppressive therapy predispose the patient to develop overt clinical findings.

As for tuberculosis, re-activation of overt disease following immunosuppression result from old foci of infec-

tion that were controlled by an immune response (2)

The resolution of leishmanial infection in humans and animals is associated with expansion of leishmania-specific CD4+ T cells of the Th1 type, which secrete INF-gamma and interleukin-2 in response to leishmanial antigens. In persons with progressive VL, evidence of leishmania-specific Th1 response is absent.

Our patient had probably been infected in the past and treatment with steroids and cyclophosphamide was responsible for the reactivation of latent leishmaniasis. Serology for *Leishmania* performed on the patient's sera stored on August 2000 was positive (1:40). The time elapsing between the patient's return to Sicily and the development of

disease was not sufficient for the incubation of the parasite in case of primary infection.

VL associated with autoimmune diseases such as mixed cryoglobulinemia (5) or Wegener granulomatosis (6) has been described; this is the first report of VL complicating PA. Our report underlines the recommendation that, in endemic areas, the possibility of latent leishmaniasis should be considered and the serodiagnosis should be performed before beginning any immunosuppressive treatment. Although chronic suppressive therapy for VL is probably advisable in persons with HIV infection only, prophylaxis may be considered for patients with a history of previous VL who are candidates for immunosuppressive treatment.

References

1. HUNDER GC: Polyarteritis nodosa. In KLIPPERJH (Eds.): *Primer on the Rheumatic Diseases*. Atlanta, Arthritis Foundation 1997: 295-96.
2. HACHULLA E: Periarterite noueuse. *Rev Prat* 2000; 50: 261-7.
3. MAGILL AJ: Leishmaniasis. In STRICKLAND GT (Eds.): *Hunter's Tropical Medicine and Emerging Infectious Diseases*. Philadelphia, W.B. Saunders 2000: 665-79.
4. DE CARNERI I: Leishmaniosi viscerale. In DE CARNERI I (Eds.): *Parassitologia generale e umana*. Milan, Casa Editrice Ambrosiana 1981: 93-5
5. CASATO M, DEROSAFG, PUCILLO LP, ILARDI I *et al.*: Mixed cryoglobulinemia secondary to visceral Leishmaniasis. *Arthritis Rheum* 1999; 42: 2007-11.
6. ZANALDI H, ROSENTHAL E, MARTY P *et al.*: Leishmaniosi viscerale associée à une maladie de Wegener. *Presse Med* 1999; 28: 959-61.