

# Joint sonography in asymptomatic patients with HCV correlated hepatitis

A. Iagnocco, G. Coari, A. Mammarella<sup>1</sup>, S. Basili<sup>1</sup>, L. Donnarumma, G. Valesini, V. Paoletti<sup>1</sup>

---

*Rheumatology Unit and <sup>1</sup>Medical Therapy Department, University "La Sapienza", Rome, Italy.*

---

## Abstract

### Objectives

*Many different articular symptoms may appear in patients with HCV hepatitis, but in a relatively large number of patients no rheumatic symptoms are present. This sonographic study was undertaken to detect the possible presence of early articular changes in HCV patients without any rheumatic manifestations.*

---

### Methods

*The knee, hip and shoulder were evaluated in a cohort of 29 consecutive HCV patients without any rheumatic symptoms. Results were compared with those obtained by the evaluation of 29 healthy subjects who were negative for markers of HCV and HBV infections.*

---

### Results

*Results showed the presence of alterations in 96.5% of the patients, with significant differences in comparison to controls ( $p < 0.0001$ ). Slight inflammatory changes were found in all the joints examined. The knee was involved in 79.3% of the cases, the hip in 27.6% and the shoulder in 89.6%.*

---

### Conclusions

*Our preliminary study shows the presence of joint changes in the majority of cases. To the best of our knowledge this is the first ultrasonographic study to focus on joint evaluation in patients with HCV hepatitis. Broader epidemiological and virological investigations, in particular for the HCV subtype and HLA genotype, will be required to elucidate the relationship between HCV infection and rheumatic symptoms.*

---

### Key words

HCV hepatitis, joint sonography.

Annamaria Iagnocco, MD; Giulio Coari, MD; Antonio Mammarella, MD; Stefania Basili, MD; Lucia Donnarumma, MD; Guido Valesini, MD; Vincenzo Paoletti, MD.

Please address correspondence and reprint requests to: Annamaria Iagnocco, MD, Cattedra di Reumatologia, Dipartimento di Clinica e Terapia Medica Applicata, Università di Roma "La Sapienza", Viale del Policlinico 155, 00161 Rome, Italy. E-mail: aiagnocco@tiscali.it

Received on March 28, 2003; accepted in revised form on September 23, 2003.

© Copyright CLINICAL AND EXPERIMENTAL RHEUMATOLOGY 2004.

## Introduction

Great interest has recently focused on rheumatic manifestations in patients with HCV hepatitis (1-4). Polyarthralgias or polyarthritis are the most common rheumatic symptoms (4). In particular, a non-erosive and non-deforming polyarthritis mimicking rheumatoid arthritis (RA) is frequently associated with HCV infection. In acute onset it usually has a rheumatoid distribution but with frequent remissions (5,6). HCV RNA has been detected not only in the serum of patients but also in their synovial fluid and specific tropism of HCV for the synovial membrane has been suspected but never documented (7).

The high frequency of rheumatoid factor positivity in patients with HCV hepatitis usually makes it very difficult to make the differential diagnosis between RA and HCV-related polyarthritis (8-10). Another possible confounding factor is the documented capacity of IFN  $\alpha$ , which is employed in treatment of HCV infection, to precipitate or exacerbate some autoimmune diseases. Sonography is a highly sensitive imaging method for the identification of joint changes either in the presence or absence of articular symptoms. Both articular and periarticular soft tissues are accurately evaluated by sonographic analysis and hence, with its low cost and non-invasiveness, this technique is widely used for detection of joint alterations (11-13). The aim of the present study was to evaluate sonographically the prevalence of early joint involvement in a cohort of 29 consecutive HCV patients without any rheumatic symptoms, compared to 29 control healthy subjects without any markers of HCV or HBV infection. A secondary objective was to examine the association of joint alterations with the different genotypes.

## Materials and methods

### Patients

In order to study the prevalence of joint involvement in patients with HCV hepatitis we examined 29 subjects (13 men and 16 women; mean age 58.7 years, range 20-80) with chronic C hepatitis (disease duration 8-20 months) diagnosed on the basis of positive serological markers of infection assumed by the demonstration of positive serological

markers of infection, i.e. antibodies to HCV (anti-HCV), obtained by a third-generation enzyme-linked immunosorbent assay (ELISA) and successively confirmed by the more specific recombinant immunoblot assay (RIBA). Percutaneous liver biopsy and HCV-RNA detection by polymerase chain reaction (PCR) were performed in all patients. HCV genome was typed using the Line Probe Assay (LiPA, Innogenetics). 1b genotype was present in 44.8% patients, 1a in 10.3%, 2a in 34.5%, and 2a/2b in 10.3%. Liver biopsy specimens were graded with respect to the degree of piecemeal necrosis, portal and lobular inflammation and fibrosis according to the Scheuer score (9 pts were class 1; 4 were class 2; 5 were class 3; and 11 were class 4). Patients with previous treatment with IFN  $\alpha$ , hepatitis B surface antigen, hepatocellular carcinoma or other non-related cancers, cholestatic liver disease, acute hepatitis or other acute infections were excluded from the study.

Haematological evaluation and liver tests [alanine aminotransferase (ALT), aspartate aminotransferase (AST), bilirubin, albumin, prothrombin, gamma-glutamyl transpeptidase and alkaline phosphatase] were performed in all patients using standard procedures. Immunological tests [anti-nuclear antibodies (ANA), anti-mitochondrial antibodies (AMA), anti-smooth muscle antibodies (ASMA), anti-liver-kidney antibodies (LKM), antithyroid antibodies (anti-TPO), circulating immune complex (ICC), rheumatoid factor] were also performed by indirect immunofluorescence, nephelometric and RIA methods. Blood samples were kept at 37°C until completely coagulated and then analysed for the presence of cryoglobulinemia. A cryocrit >1% was considered to be an essential criterion for evidence of cryoglobulinemia.

In none of the subjects were signs or symptoms of joint involvement present. Twenty-nine healthy subjects were studied as controls; they comprised 13 men and 16 women with a mean age of 44.4 years (range 28-70 years).

### Sonography

In all subjects sonography of the knees, hips and shoulders was performed separately by 2 different experienced oper-

ators, who were blinded to the clinical data and repeated each exam twice. No significant intra-observer (intra-class correlation coefficient 0.80–0.91,  $p < 0.0001$ ) or inter-observer variability was found (intra-class correlation coefficient 0.84,  $p < 0.0001$ ). A 7.5 MHz linear transducer was used to evaluate the shoulder and knee joints, and a 5 MHz linear transducer for the hip joints (Philips, Image Point System, HX).

Sonographic examination of the knee included evaluation of the suprapatellar synovial bursa to study the synovial membrane and detect joint effusion. The calf was also examined for Baker's cysts. The examination of the synovial membrane included the measurement of its thickness and the detection of synovial proliferation.

With the patient supine and the knee in a neutral position, the thickness of the posterior wall of the synovial membrane (lining anterior surface of the femur) was measured in the suprapatellar synovial bursa. The posterior wall was chosen for the sonographic measurement, as sonographically it is better defined than anterior wall (lining posterior surface of the quadriceps muscle/tendon). Transverse and longitudinal scans were performed and measurements were taken in both scans 2 cm above the superior pole of the patella (14–16); then the mean value for each pair of results was calculated.

Previous studies reported that in normal subjects the thickness of the posterior wall of the synovial membrane in the suprapatellar bursa is between 2 and 3 mm (14–16). Consequently, when the thickness was higher than 3 mm synovial thickening was considered to be found (16). Effusion was revealed when hypoechoic or anechoic fluid collection appeared within the articular space (16). Baker's cysts were considered to be present when a hypoechoic or sonolucent image appeared within the gastrocnemius-semimembranous bursa, indicating the presence of effusion. The hip was studied, searching for signs of joint effusion and trochanteric bursitis, and studying the thickness of the joint capsule. When the longest distance between the bony surface of the femur and the joint capsule was greater than 7 mm effusion was diagnosed (17). The

appearance of a hypoechoic or sonolucent image within the trochanteric bursa with a thickening of the bursa  $> 2$  mm was considered to be a sign of bursitis (18). When the thickness of the joint capsule was at least doubled with respect to that in normal hips (1 mm), thickening was considered to be present and it was interpreted as a sign of long-lasting inflammatory process (18).

In all cases investigation of the shoulder included the long head of the biceps tendon, 3 rotator cuff tendons (supraspinatus, infraspinatus and subscapularis), the subacromial and subscapularis bursae, and the acromioclavicular and glenohumeral joints. The 4th rotator cuff tendon was not examined due to the frequent difficulties in its sonographic assessment. Evaluation of the tendons, bursae and joints of the shoulder girdle was carried out using a combination of reported techniques (14, 19–22). Sonographic assessment of the tendons was obtained by evaluating their thickness and studying their fibrillar pattern. Variations in thickness were evaluated with respect to the tendons of healthy subjects. Changes were considered to be significant when the variation was at least 1/3 of the normal thickness.

Tendon structure was evaluated by studying the homogeneity of their fibrillar pattern and irregularities in their margins. The presence of tendon tears was diagnosed when a hypoechoic discontinuity appeared within the tendon fibrillar pattern; a full-thickness tear was considered to be present when the defect extended through the entire tendon, and a partial-thickness tear when it was limited to only a part of the tendon thickness (20). With regard to the long head of the biceps tendon, the appearance of a hypoechoic or sonolucent area surrounding the tendon and within its sheath was interpreted as a sign of tenosynovitis (11,12).

Involvement of the subacromial and subscapularis bursae was diagnosed when a hypoechoic or sonolucent image appeared within the bursae, indicating the presence of effusion; the finding was considered significant when effusion caused a thickening of the bursa  $> 2$  mm (23–25). The presence of effusion within the acromioclavicular joint was indicated when the capsule was convex to

the articular space with the simultaneous appearance of a hypoechoic area within the joint (21). Effusion within the glenohumeral joint was considered to be present when the longest distance between the bony surface of the humerus and the joint capsule was  $> 4$  mm (22).

All changes were scored following a specific point scale as reported in Table I.

#### Statistical analysis

Statistical analysis was performed by chi-square statistics or Fisher's exact test (if  $n < 5$ ) for independence and by the appropriate t-test. When necessary, log transformation was used to normalise the data, or appropriate non-parametric tests were employed. Data are presented as the mean  $\pm$  SD and 95% confidence limits (95% CL) or as the median (range). Only two-tailed probabilities were used for testing statistical significance. P values lower than 0.05 were regarded as statistically significant (28). All calculations were made using the computer program Stat-View II (Abacus Concepts, Berkeley, CA).

#### Results

No significant differences were found between HCV patients and healthy subjects regarding the values for inflammation parameters (i.e., C-reactive protein, ESR). No differences between patients who showed joint alterations and patients who did not were observed regarding serum liver tests, such as ALT, AST, bilirubin, albumin, prothrombin, -glutamyl-transpeptidase and alkaline phosphatase.

Knodel's score for the serum HCV-RNA value did not distinguish patients with joint changes from the others. No significant correlation was found between the laboratory data and sonographic findings.

In the sera of HCV patients, ANA were present in 7 (24.1%), AMA in 3 (10.3%) and ASMA in 5 (17.2%). Seven (24.1%) patients showed evidence of cryoglobulinemia. No healthy subject had any of the above mentioned patterns.

Results of sonographic examinations are reported in Table I. In order to evaluate the differences between the two groups, the first step in the analysis focused on the prevalence of joint changes in each group independently of the

**Table I.** Sonographic findings.

Joint	Anatomic structure	Changes	Score	HS*	HCVp*		
Knee	Synovial thickening	Absent (< 4 mm)	0	50	20		
		Slight (4 – 5.9 mm)	1	8	24		
		Moderate (6 – 7.9 mm)	2	0	12		
		Severe (> 8 mm)	3	0	2		
	Synovial proliferation	Absent	0	58	51		
		Present	1	0	7		
	Effusion	Absent	0	58	44		
		Slight	1	0	8		
		Moderate	2	0	6		
		Abundant	3	0	0		
	Baker's cyst	Absent	0	58	54		
		Present	1	0	4		
Hip	Effusion (Bone–capsule distance)	Absent (< 7 mm)	0	58	48		
		Slight (7.1 – 8.9 mm)	1	0	4		
		Moderate (9 – 10.9 mm)	2	0	4		
		Severe (> 11 mm)	3	0	2		
	Bursitis	Absent	0	58	56		
		Present	1	0	2		
	Joint capsule	Normal	0	58	57		
		Thickened	1	0	1		
	Shoulder	Long head of the biceps tendon	Peritendineous fluid collection:				
			Absent	0	54	34	
			Slight	1	4	19	
			Moderate	2	0	5	
Abundant			3	0	0		
Tendon's changes**:							
Absent			0	57	54		
Slight			1	1	4		
Supraspinatus Tendon		Tendon changes**:					
		Absent	0	57	46		
		Slight	1	1	10		
		Moderate	2	0	2		
Infraspinatus tendon		Tendon changes**:					
		Absent	0	57	51		
		Slight	1	1	6		
		Moderate	2	0	1		
Subscapularis tendon		Tendon changes**:					
		Absent	0	58	51		
		Slight	1	0	6		
		Moderate	2	0	1		
Subacromialis bursitis		Tendon changes**:					
		Absent	0	58	54		
		Present	1	0	4		
		Subscapularis bursitis	Tendon changes**:				
Absent	0		58	56			
Present	1		0	2			
Effusion of the acromioclavicular joint	Tendon changes**:						
	Absent	0	53	41			
	Slight	1	5	7			
	Moderate	2	0	8			
Effusion of glenohumeral joint (Bone–capsule distance)	Tendon changes**:						
	Absent	0	57	57			
	Slight (4 – 5.9 mm)	1	1	0			
	Moderate (6 – 7.9 mm)	2	0	1			
	Tendon changes**:						
	Abundant (> 8 mm)	3	0	0			

\*Number of joints in healthy subjects (HS) and HCV patients (HCVp).

\*\*Tendon changes include: changes in the fibrillar pattern, margins, thickness, and the presence of tears.

score. The differences in score were also studied to evaluate whether any changes existed in terms of alterations between the two groups.

Contemporaneous involvement of more than one examined joint was found in 21 patients with HCV hepatitis (72.4%). In 7 cases (24.1%) only 1 joint was involved, while in 1 patient (3.4%) no alteration was found.

Taken together the prevalence of changes within the various anatomic structures was 154/986 (15.6%) among HCV patients and 21/986 (2.1%) in healthy subjects ( $p < 0.0001$ ).

Evaluation of the prevalence of sonographic joint alterations did not show any correlation with the different genotypes nor with the Scheuer score for the liver biopsy.

*Knee joint*

A higher prevalence ( $p < 0.0001$ ) of changes in the synovial membrane was found in HCV patients (38 joints; 65.5%) compared to controls (8 joints; 13.8%). Synovial proliferation was seen in 7 joints (12.1%) of patients with HCV hepatitis (Fig. 1) and in none of the control joints ( $p < 0.002$ ).

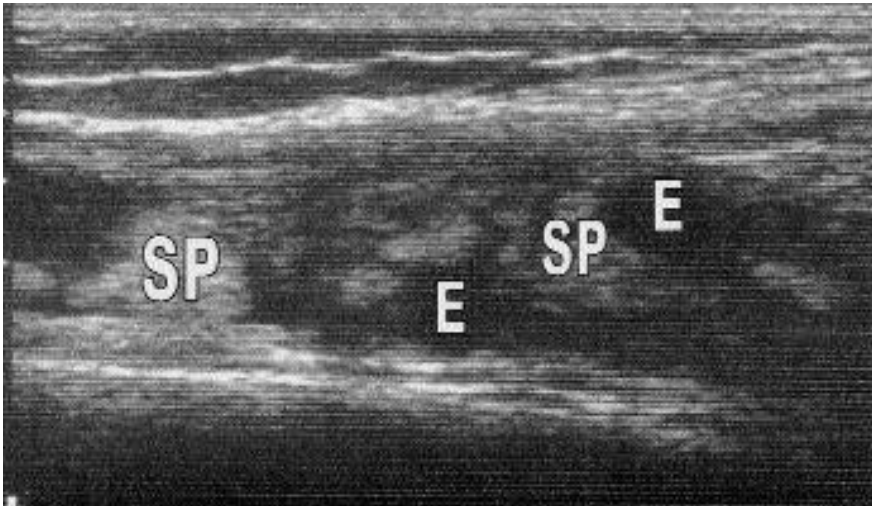
Knee joint effusion and Baker's cysts were not detected in healthy subjects. In contrast effusion was found in 14 joints (24.1%,  $p < 0.0001$ ) among HCV patients (fig. 1) and Baker's cysts in 4 (6.9%,  $p < 0.002$ ). Totally involvement of the knee was seen in 23 patients (79.3%) and in 8 controls (27.6%).

*Hip joint*

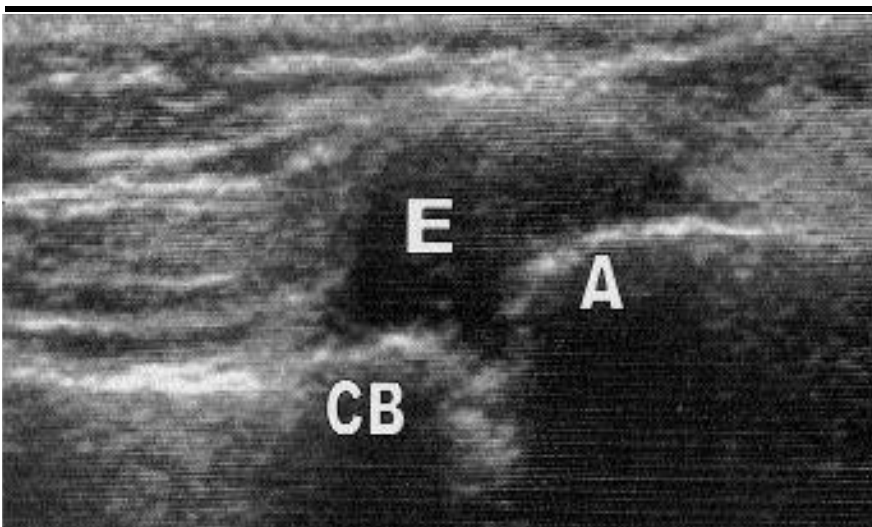
None of healthy subjects showed any changes of the hip. On the contrary, effusion was detected in 10 (17.2%,  $p < 0.0006$ ), bursitis in 2 (3.4%, n.s.) and capsule thickening in 1 (1.7%, n.s.) HCV joints. In total the hip was involved in 8 patients with HCV hepatitis (27.6%).

*Shoulder joint*

Significantly higher amounts of peritendinous fluid were collected at the long head of the biceps tendon in HCV patients compared to controls (24 joints, 41.3% versus 4, 6.9%;  $p < 0.0001$ ). In particular the 24 HCV patients showed a slight (19 cases) or moderate (5 joints) score, whereas all healthy subjects had a slight score. The differences



**Fig. 1.** Sonography of the knee. Evidence of joint effusion (E) and synovial proliferation (SP).



**Fig. 2.** Sonography of the acromioclavicular joint. Evidence of joint effusion (E). CB: clavicular bone. A: acromion.

in changes at the long head of the biceps tendon were not significant between the two groups (HCV patients 6.9% versus controls 1.7%). No subjects showed full-thickness tears of the long head of the biceps tendon.

Supraspinatus tendon changes were observed in 12 joints (20.7%) of HCV patients and in 1 (1.7%) of controls ( $p < 0.002$ ). Similar findings were observed regarding changes in the infraspinatus (7 joints or 12%, versus 1 or 1.7%;  $p < 0.03$ ) and subscapularis tendon (7 or 12.1% versus 0;  $p < 0.003$ ).

Bursitis was never found in healthy subjects. On the contrary, subacromial bursitis was present in 4 joints (6.9%;  $p < 0.05$ ) and subscapularis bursitis in 2 (3.4%; n.s) joints of HCV patients.

Effusion of the acromioclavicular joint (Fig. 2) was present in 17 shoulders

(29.3%) of patients with HCV hepatitis and only in 5 (6.8%) of healthy subjects ( $p < 0.004$ ). Only in 1 HCV patient was moderate effusion of the glenohumeral joint found. The same finding was present in controls.

Totally involvement of the shoulder was found in 26 patients (89.6%) and in 10 control subjects (34.5%).

#### Discussion

Many articular symptoms may appear during the course of HCV hepatitis (2, 26, 27). Arthritis and arthralgias are the most commonly reported manifestations (3, 4), but myalgia (28), myositis (29), fibromyalgia (27), mixed cryoglobulinemia (30-32), vasculitides (33) or sicca syndrome (34) may also be present. At the same time, in a relatively large number of patients no rheumatic symptoms

appear. Consequently, the present ultrasonographic study was undertaken to detect the possible presence of early articular changes in HCV patients without any rheumatic manifestations.

Using ultrasound we evaluated most of the anatomic structures of the knee, hip and shoulder. Ultrasonography is an imaging method that accurately detects joint changes and has been recently successfully applied to the evaluation of articular alterations in many different rheumatic disorders, even though the sonographic assessment procedure has not been standardized yet (11-14,16,20). The broad spectrum of articular symptoms that may appear in HCV patients has been examined in previous clinical (35,36) and serological (33,37) studies. To the best of our knowledge, this study represents the first ultrasonographic analysis aimed at detecting the appearance of possible early joint alterations in patients without any articular symptoms.

In particular, our results showed the presence of alterations in 96.5% of the patients, with significant differences with respect to the controls ( $p < 0.0001$ ). This finding confirms the high sensitivity of ultrasound in the detection of joint alterations. Wherever possible, changes were scored according to their severity (slight, moderate, severe). In most cases slight changes were demonstrated and a higher prevalence of inflammatory alterations was present. Prevalence of changes was significantly different between slight and both moderate and severe alterations, as well as between moderate and severe alterations. Signs of synovitis and/or tenosynovitis were the most common findings at all articular sites.

The knee was frequently involved (79.3% of patients), mostly with slight inflammatory characteristics, and a higher prevalence of slight to moderate joint effusion and synovial thickening. The hip joint was involved more rarely than the knee ( $p < 0.0002$ ) or the shoulder ( $p < 0.0006$ ), although even here joint effusion was detected, demonstrating the presence of inflammatory changes. The rare finding of joint capsule thickening confirmed the absence of a long-lasting inflammatory process in most cases.

Changes in the shoulder were also fre-

quent (89.6% of patients), with slight inflammatory characteristics and the frequent appearance of tenosynovitis of the long head of the biceps tendon and acromioclavicular joint effusion. Changes in tendon structure reflecting a possible long-lasting pathology were rarer. However, even involvement of the tendons but not the synovial sheath (such as the rotator cuff tendons) could possibly be explained as a sign of an inflammatory process within them, similarly to the changes that appear in RA (38, 39). Effusion within the gleno-humeral joint was present only in one case. Two hypotheses can be proposed to explain the latter finding: the low sensitivity of ultrasound in detecting very slight fluid collection in such a large joint; or the rarity of gleno-humeral joint involvement in patients with HCV hepatitis.

In conclusion our preliminary study demonstrated the presence of joint changes in most asymptomatic patients with HCV hepatitis, with the prevalence of slight inflammatory alterations. A possible hypothesis to explain our results is that these alterations are due to the presence of sub-clinical synovitis. Confirmation of this could be obtained by a follow-up of our patients. Larger epidemiologic and virologic investigations, in particular for HCV subtype and HLA genotype, will be required to elucidate the relationship between HCV infection and rheumatic symptoms. Based on the available data, HCV infection appears to be strongly associated with many rheumatic manifestations. It is recognized that the hepatitis C virus can replicate outside the liver and this may account for the well-known systemic involvement. It is thus recommended that patients with rheumatic symptoms should be tested for HCV and conversely that signs and symptoms of articular involvement should be evaluated in HCV patients.

An investigation of the risk factors for HCV infection is recommended in the presence of new or atypical rheumatic complaints and/or unexplained anomalies shown by ultrasonographic analysis.

## References

- FIETTA P, MANGANELLI P: Le manifestazioni reumatologiche dell'infezione da HCV [review]. *L'Internista* 2001; 9: 211-22.
- CACOUB P, POYNARD T, GHILLANI P *et al.*: Extrahepatic manifestations of chronic hepatitis C. *Arthritis Rheum* 1999; 42: 2204-12.
- MODER KG, LINDOR K: Musculoskeletal symptoms associated with hepatitis C. *Arthritis Rheum* 1995; 38: S200.
- UENO Y, KINOSHITA R, KISHIMOTO I, OKAMOTO S: Polyarthritis associated with hepatitis C virus infection. *Br J Rheumatol* 1994; 33: 289-91.
- SIEGEL LB, LOHN L, NASHEL D: Rheumatic manifestations of hepatitis C infection [review]. *Semin Arthritis Rheum* 1993; 23: 149-54.
- JENDRO MC, HULSEMAN JL, ZEIDLER H: Das hepatitis C-virus und rheumatische Erkrankungen. *Z Rheumatol* 1997; 56: 276-86.
- UENO Y, KINOSHITA R, TSUJINONE H, KATO M: A case of hepatitis C virus HCV-associated arthritis. Quantitative analysis of HCV-RNA of the synovial fluid and the serum. *Br J Rheumatol* 1995; 34: 691-2.
- MCMURRAY RW: Hepatitis C associated autoimmune disorders. *Rheum Dis Clin North Am* 1998; 24: 354-74.
- CLIFFORD B, DONAHNE D, SMITH L *et al.*: High prevalence of serological markers of autoimmunity in patients with chronic hepatitis C. *Hepatology* 1994; 19: 841-8.
- MAILLEFERT JF, MULLER G, FALGARONE G *et al.*: Prevalence of hepatitis C virus infection in patients with rheumatoid arthritis. *Ann Rheum Dis* 2002; 61: 635-7.
- NAREDO E, AGUADO P, DE MIGUEL E *et al.*: Painful shoulder: Comparison of physical examination and ultrasonographic findings. *Ann Rheum Dis* 2002; 61: 132-6.
- COARI G, PAOLETTI F, IAGNOCCO A: Shoulder involvement in rheumatic diseases. Sonographic findings. *J Rheumatol* 1999; 26: 668-73.
- RUBALTELLI L, FIOCCO U, COZZI L *et al.*: Prospective sonographic and arthroscopic evaluation of proliferative knee joint synovitis. *J Ultrasound Med* 1994; 13: 855-62.
- COARI G, IAGNOCCO A, MAGGI S *et al.*: Sonographic findings in haemodialysis-related chronic arthropathy. *Eur Radiol* 1996; 6: 890-4.
- COARI G, IAGNOCCO A, ZOPPINI A: Chondrocalcinosis: Sonographic study of the knee. *Clin Rheumatol* 1995; 14: 511-4.
- IAGNOCCO A, COARI G, PALOMBI G, VALDESINI G: Knee joint synovitis in Sjögren's syndrome. Sonographic study. *Scand J Rheumatol* 2002; 31: 291-5.
- KOSKI J, ANTILA PJ, ISOMAKI HA: Ultrasonography of the adult hip joint. *Scand J Rheumatol* 1989; 18: 113-7.
- COARI G, IAGNOCCO A, L'ANCA. In COARI G and IAGNOCCO A (Eds.): *Ecografia articolare*. Milan, Masson 1993; 36-43.
- MACK LA, NYBERG DA, MATSEN FA: Sonographic evaluation of the rotator cuff. *Radiol Clin North Am* 1988; 26: 161-77.
- VAN MOPPEL FI, VELDKAMP O, ROORDA J: Role of shoulder ultrasonography in the evaluation of the painful shoulder. *Eur J Radiol* 1995; 19: 142-6.
- COARI G, IAGNOCCO A: La Spalla. In COARI G and IAGNOCCO A (Eds.): *Ecografia articolare*. Milan, Masson 1993; 13-21.
- KOSKI JM: Axillar ultrasound of the gleno-humeral joint. *J Rheumatol* 1989; 16: 664-7.
- HOLLISTER MS, MACK LA, PATTEN RM, WINTER TC III, MATSEN FA III, VEITH RR: Association of sonographically detected subacromial subdeltoid bursal effusion and intraarticular fluid with rotator cuff tear. *Am J Roentgenol* 1995; 165: 605-8.
- ALASAARELA E, TAKALO R, TERVOONEN O, HAKALA M, SURAMO I: Sonography and MRI in the evaluation of the painful arthritic shoulder. *Br J Rheumatol* 1997; 36: 996-1000.
- VAN HOLSBECK M, STROUSE PJ: Sonography of the shoulder: Evaluation of the subacromial-subdeltoid bursa. *Am J Roentgenol* 1993; 160: 561-4.
- GUMBER SC, CHOPRA S: Hepatitis C. A multi-faceted disease. Review of extra-hepatic manifestations. *Ann Intern Med* 1995; 123: 615-20.
- BUSKILA D, SHNAIDER A, NEUMANN L *et al.*: Musculoskeletal manifestations and autoantibody profile in 90 hepatitis C infected Israeli patients. *Semin Arthritis Rheum* 1998; 28: 107-13.
- GARCÍA-MONFORTE A, ROMERO M, DE DIEGO A, RIVERA J: Rheumatic and autoimmune manifestations in chronic hepatitis C virus infection. *Arthritis Rheum* 1995; 38: S200.
- NISHIKAI M, MIYAIRI M, KOSAKA S: Dermatomyositis following infection with hepatitis C virus. *J Rheumatol* 1994; 21: 1584-5.
- CACOUB P, LUNEL FABIANI F, MUSSET L *et al.*: Mixed cryoglobulinemia and hepatitis C virus. *Am J Med* 1994; 96: 124-32.
- FERRI C, LA CIVITA L, LONGOBARDO G, GRECO F, BOMBARDIERI S: Hepatitis C virus and mixed cryoglobulinemia. *Eur J Clin Invest* 1993; 23: 399-405.
- AGNELLO V: The aetiology of mixed cryoglobulinemia associated with hepatitis C virus infection. *Scand J Immunol* 1995; 42: 179-84.
- MANNA R, TODARO L, LATTERI M *et al.*: Leukocytoclastic vasculitis associated with hepatitis C virus antibodies. *Br J Rheumatol* 1997; 36: 124-5.
- HADDAD J, DONY P, MUNZ-GOTHEIL C *et al.*: Lymphocytic sialadenitis of Sjögren's syndrome associated with chronic hepatitis C virus liver disease. *Lancet* 1992; 339: 321-323.
- RIVERA J, GARCÍA-MONFORTE A, PINEDA A, NUNEZ-CORTES JM: Arthritis in patients with chronic hepatitis C virus infection. *J Rheumatol* 1999; 26: 420-4.
- WENER MH, JOHNSON RJ, SASSO EH, GRETCH DR: Hepatitis C virus and rheumatic disease. *J Rheumatol* 1996; 23: 953-9.
- VALENTINI G, MANTELLI A, PERSICO M *et al.*: Serological and clinical markers of autoimmune disease in HCV-infected subjects with different disease conditions. *Clin Exp Rheumatol* 1999; 17: 75-9.
- FREDIANI B, FALSETTI P, STORRI L *et al.*: Ultrasound and clinical evaluation of quadriceps tendon enthesitis in patients with psoriatic arthritis and rheumatoid arthritis. *Clin Rheumatol* 2002; 21: 294-8.
- NARANJO A, MARRERO-PULIDO T, OJEDA S *et al.*: Abnormal sonographic findings in the asymptomatic arthritic shoulder. *Scand J Rheumatol* 2002; 31: 17-21.