

Tumoral calcinosis in systemic sclerosis

Sirs,

Systemic sclerosis (SSc) is a systemic inflammatory disorder affecting many organs, particularly the lungs, the gastrointestinal tract and the skin (1). Calcinosis is also a frequent manifestation in SSc, being encountered in 8 to 40% of patients (2-4). While calcinosis most often involve the hands (85% of cases), it may also affect other troublesome sites, including peri-articular areas (3,4). Moreover, although calcinosis may vary in size, it rarely leads to tumoral masses (5). We recently observed a case of particular interest, as the patient with limited SSc (lcSSc) developed a pseudo-tumor involving the anterior part of the left shoulder related to tumoral calcinosis. A 61-year-old woman was diagnosed with lcSSc in 1995. Systemic manifestations of lcSSc included: 1) Raynaud's phenomenon associated with telangiectasia, pitting scars and cutis calcinosis involving the hands; 2) esophageal impairment characterized by the absence of peristalsis in the lower two-thirds of the esophageal body and low pressure in the lower esophageal sphincter; and 3) interstitial lung disease. Autoantibody screening tests were positive for antinuclear (1:1000) and anticentromere antibodies. Nailfold capillaroscopy revealed enlarged capillary loops. The patient received combination treatment with diltiazem, cisapride and omeprazole. In July 2001, she presented with a painful tumoral mass on the anterior part of the left shoulder, which had developed over 5 months and was exquisitely tender to gentle palpation (Fig.1a). Laboratory data included: ESR 12 mm/ hour, hemoglobin 8.5 mmol/L, white blood cell

count $5.9 \times 10^9/L$, and platelet count $259 \times 10^9/mm^3$. Results of renal and liver tests, blood protein electrophoresis, serum calcium and phosphorous levels were within normal limits. Bone radiographs revealed marked conglomerate of soft tissue calcifications along the anterior part of the left shoulder (Fig. 1b), and CT-scan demonstrated calcific deposits with a focal cortical clavicle erosion underlying the extensive calcifications (Fig. 1c). Because the patient exhibited both discomfort and stiffness caused by the location of tumoral calcinosis, local excision surgery of the mass (composed of hydroxyapatite crystals) was made with a favorable outcome.

Calcinosis is a frequent complication, occurring mainly during the course of lcSSc with anticentromere antibodies (2,4). It usually remains asymptomatic, calcific deposits being detected by systematic bone radiographs showing linear and punctuate patterns of a few millimeters (2). In contrast, calcinosis mimicking a tumoral process is uncommon, occurring in less than 1% of SSc patients (5). In this instance, our patient presented with tumoral calcinosis involving the anterior part of her left shoulder, which was a marked cause of disability compared with the other components of lcSSc. CT-scan was further useful in accurately revealing the detailed anatomic extent of calcinosis and underlying bone clavicle erosion. Because of both severe discomfort and decreased dignity related to the location of the tumoral calcinosis, our patient underwent surgical excision of the lesion, as suggested previously (3).

Finally, although tumoral calcinosis is uncommon in SSc, our findings suggest that when this type of complication is noted, an evaluation for systemic sclerosis,

including a clinical evaluation, a search for antinuclear antibodies and nailfold capillaroscopy should be systematically performed.

I. MARIE¹, MD, PhD

F. DUPARC², MD, PhD

A. JANVRESSE³, MD

H. LEVESQUE¹, MD, PhD

H. COURTOIS¹, MD, PhD

Departments of ¹Internal Medicine, ²Orthopedic Surgery, and ³Radiology, Centre Hospitalier Universitaire de Rouen-Boisguillaume, Rouen, France.

Address correspondence to: Dr. Isabelle Marie, Department of Internal Medicine, Centre hospitalier universitaire de Rouen-Boisguillaume, 76031 Rouen Cedex, France.

References

1. MARIE I, DOMINIQUE S, LEVESQUE H *et al.*: Esophageal involvement and pulmonary manifestations in systemic sclerosis. *Arthritis Rheum* 2001; 45: 346-54.
2. BLOCKA K: Organ involvement: musculoskeletal. In CLEMENTS PJ and FURST DE (Eds.): *Systemic Sclerosis*. Baltimore, Williams & Wilkins 1996: 409-24.
3. HUSSMANN J, RUSSELL RC, KUCAN JO, KHARDORI R, STEINAU HU: Soft-tissue calcifications: Differential diagnosis and therapeutic approaches. *Ann Plast Surg* 1995; 34: 138-47.
4. NISHIKAI M, ITOH K, SATO A: Calcinosis and the anticentromere antibody: its clinical, radiological and immunogenetic aspects. *Br J Rheumatol* 1992; 31: 9-12.
5. KATAYAMAI, HIGASHI K, MUKAI H, NISHIOKAK, NISHIYAMA S: Tumoral calcinosis in scleroderma. *J Dermatol* 1989; 16: 82-5.

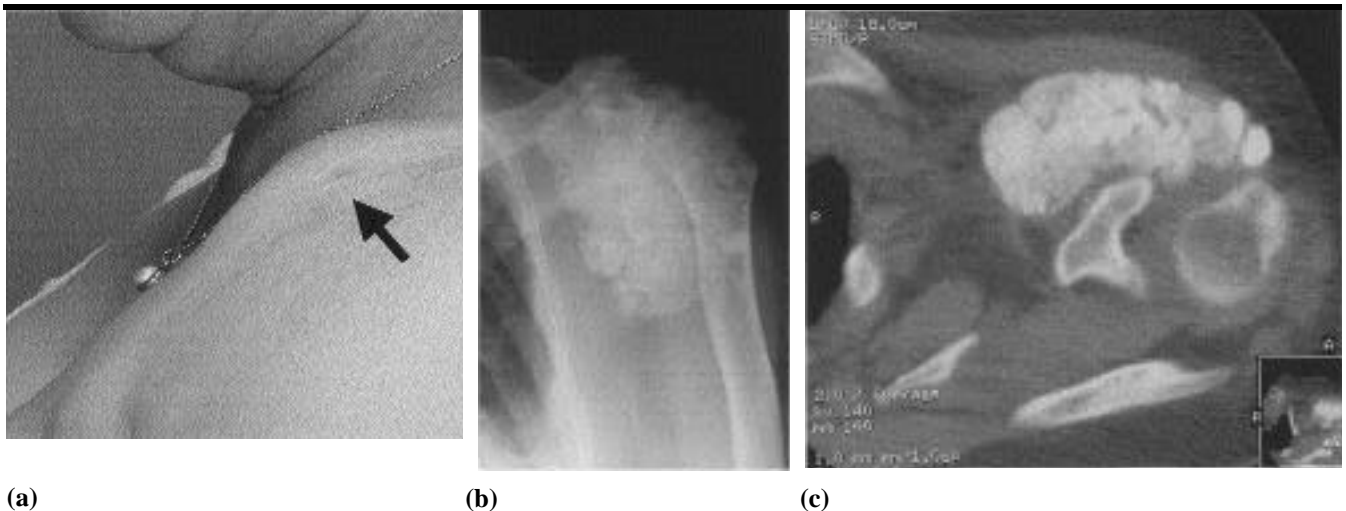


Fig. 1. (a) Voluminous pseudo-tumor along the anterior part of the left shoulder. (b) Bone radiographs revealed marked soft tissue calcifications conglomerating along the anterior part of the left shoulder. (c) CT-scan demonstrated tumoral calcific deposits in the left shoulder area with a focal cortical clavicle erosion underlying the extensive calcifications.