IgG4-related prostatitis: expanding the spectrum of IgG4-related disease. A systematic review

C. Pamfil[1,2], M.I. Mihon[2], V. Surdu[3], C. Bucșa[4], G. Cabău[5,6], L. Damian[2], I. Felea[2], T.N. Onea[7], S. Rednic[1,2], R. Talarico[8]

[1]Department of Rheumatology, Iuliu Hațieganu University of Medicine and Pharmacy, Cluj-Napoca, Romania; [2]Department of Rheumatology, Emergency Clinical County Hospital, Cluj-Napoca, Romania; [3]Department of Anesthesia and Intensive Care II, Iuliu Hațieganu University of Medicine and Pharmacy, Cluj-Napoca, Romania; [4]Pharmacovigilance Research Center, Iuliu Hațieganu University of Medicine and Pharmacy, Cluj-Napoca, Romania; [5]Department of Medical Genetics Iuliu Hațieganu University of Medicine and Pharmacy, Cluj-Napoca, Romania; [6]Department of Translational Immunology, Medfuture Institute for Biomedical Research, Iuliu Hațieganu University of Medicine and Pharmacy, Cluj-Napoca, Romania; [7]Faculty of Medicine, Iuliu Hațieganu University of Medicine and Pharmacy, Cluj-Napoca, Romania; [8]Department of Rheumatology, Azienda Ospedaliero Universitaria Pisana, University of Pisa, Italy.

Abstract

Objective

Immunoglobulin G4-related disease (IgG4-RD) is a systemic fibroinflammatory condition that may affect any organ. Prostatic involvement is uncommon and under-recognised. The presentation often mimics benign prostatic hyperplasia or prostate carcinoma, causing diagnostic uncertainty. This systematic review synthesises evidence on IgG4-related prostatitis, focusing on clinical manifestations, diagnostic approaches, treatment, and outcomes.

Methods

Following PRISMA 2020 guidelines, PubMed, Scopus, Web of Science, and Ovid were searched from inception to 12 February 2025. Eligible studies included English-language case reports, case series, and observational studies describing prostatic involvement in IgG4-RD. Data on demographics, clinical and laboratory findings, management, and outcomes were extracted and analysed descriptively.

Results

Fifty studies reporting 66 cases were included. Median age was 64 years (range 20–82). Serum IgG4 concentrations were elevated in most (median 832 mg/dL, range 5–4,500), while prostate-specific antigen (PSA) levels varied widely (0.01–180 ng/mL). Multiorgan involvement occurred in 57.8%, isolated disease in 6.2%. Lower urinary tract symptoms were most frequent (39.6%). Glucocorticoids, mainly prednisone, were the main therapy (69.2%), followed by surgery, chiefly transurethral resection of the prostate. Complete and partial responses occurred in 50.9% and 43.4%. Treatment type correlated with outcome (χ^2=49.70; $p<0.001$). Malignancy (18.5%) was associated with higher mortality ($p=0.028$).

Conclusion

IgG4-related prostatitis is a rare and likely under-recognised manifestation of IgG4-RD. Its overlap with benign and malignant prostatic disorders delays diagnosis. Serum IgG4 and PSA are unreliable markers of disease and monitoring. Glucocorticoids remain first-line therapy, with surgery in obstructive cases. Multicentre studies are needed to define prevalence, natural history, and optimal management.

Key words

IgG4-related disease, prostatitis, fibroinflammatory disorders, autoimmune prostatitis

*Cristina Pamfil, MD, PhD**
*Maia Ioana Mihon, MD**
Victor Surdu, MD
Camelia Bucșa, PhD
Georgiana Cabău, MD, PhD
Laura Damian, MD, PhD
Ioana Felea, MD
Teodor Nicolae Onea, MD
Simona Rednic, MD, PhD
Rosaria Talarico, MD, PhD

**Contributed equally*

Please address correspondence to:
Georgiana Cabău
Department of Medical Genetics, Medfuture Institute for Biomedical Research, UMF Iuliu Hatieganu, Strada Victor Babeș 8, 400012 Cluj-Napoca, Romania.
E-mail: georgiana.cabau@gmail.com

Received on October 16, 2025; accepted in revised form on November 17, 2025.

© Copyright Clinical and Experimental Rheumatology 2026.

Funding: this work was supported by Romania's National Recovery and Resilience Plan grant of the Romanian Ministry of Investments and European Projects (PNRR-III-C9-2023-I8, CF 199/ 31.07.2023).

Competing interests: none declared.

Introduction

Immunoglobulin G4-related disease (IgG4-RD) is a systemic fibroinflammatory condition that may affect virtually any organ system (1-4). It is characterised histologically by mass-forming lesions with storiform fibrosis, a dense lymphoplasmacytic infiltrate rich in IgG4-positive plasma cells, and often elevated serum IgG4 concentrations (2, 4-7). Since its recognition two decades ago, IgG4-RD has evolved from a pancreas-centered entity to a unified multisystem disorder with characteristic clinical, radiological, and immunopathological hallmarks (2, 8-11). Recent work has refined its pathogenesis, highlighting aberrant B-cell activation, plasmablast expansion, and T-follicular helper cell signaling as central drivers of chronic fibroinflammation (2, 4-7, 12).

Prostatic involvement is uncommon and has only recently been recognised as part of the IgG4-RD spectrum (13-16). Consequently, current knowledge is largely derived from isolated case reports and small case series (13-16). The clinical presentation frequently mimics benign prostatic hyperplasia (BPH) or prostate carcinoma, rendering diagnosis particularly challenging (15, 16). Histopathological confirmation remains the diagnostic gold standard, demonstrating the characteristic morphological triad of storiform fibrosis, obliterative phlebitis, and IgG4-rich plasma cell infiltrates (4, 11, 13-16). Nevertheless, awareness of this manifestation among urologists, rheumatologists, and pathologists remains limited, and no standardised diagnostic or management guidelines have been established (8, 9, 15).

Given the rarity of this condition and the fragmented nature of available evidence, a systematic review was undertaken to synthesise current data on the clinical features, diagnostic approaches, and therapeutic strategies of IgG4-related prostatitis. The overarching aim is to facilitate earlier recognition and guide future research directions to improve patient care and outcomes.

Methods

Search strategy and eligibility

This systematic review was conducted in accordance with the Preferred Reporting Items for Systematic Reviews and Meta-Analyses (PRISMA) 2020 guidelines. We considered English-language reports of male patients with prostatitis in the context of IgG4-related disease. Eligible study types included case reports, case series, observational, and clinical studies. Reports involving females, patients without prostatic involvement, or lacking adequate clinical or histopathologic detail were excluded. No further restrictions were applied to the study design to maximise case inclusion.

We systematically searched PubMed, Scopus, Web of Science, and Ovid from database inception until 12 February 2025, using combined MeSH/Emtree and free-text search terms related to 'IgG4-related disease' and 'prostatitis'. Complete search strings are available in the online supplementary material, Supplementary Table S1. Two reviewers independently screened titles and abstracts, retrieved full texts of potentially eligible studies, and resolved disagreements by consensus. Reference lists of included articles were also examined to capture additional relevant studies.

Article selection and data extraction

A standardised extraction form was used to record study characteristics, population details, intervention parameters and outcomes. Extracted variables included author, publication year, study design, patient age, duration of symptoms, urinary and prostate-related symptoms, diagnostic methods, serum IgG4 and PSA values, follow-up duration, presence of BPH, coexistent malignancy, other organ involvement, therapeutic modalities, and response.

Statistical analysis

Continuous variables were inspected for distribution (Shapiro-Wilk, Q-Q plots) and summarised as median (IQR) or mean ± SD as appropriate. Given skewed distributions for several variables (*e.g.* serum IgG4, PSA, disease duration), group comparisons used non-parametric tests (Kruskal-Wallis with Dunn's *post-hoc* test where applicable) were used. Associations between continuous variables used Spearman's ρ; binary-continuous associations used

point-biserial correlation (Pearson's r with binary coding). Categorical variables were expressed as frequencies and percentages and were compared using χ^2 tests. Two-sided α=0.05 defined statistical significance. Missing data were handled by available-case analysis; the denominator (n) was reported for each analysis. All statistical analyses were performed in R version 4.4.1.

Results

Study selection

The initial search yielded 702 records. After the removal of duplicates, 383 unique titles and abstracts were screened, of which 220 full-text articles were assessed for eligibility. The study selection process is detailed in the PRISMA 2020 flow diagram (Fig. 1).

A total of 66 individual cases of IgG4-related prostatitis were identified across 49 publications (Suppl. Table S2) (17-62). Most were single-case reports, with only two small series reporting ≥3 cases (13, 50, 53).

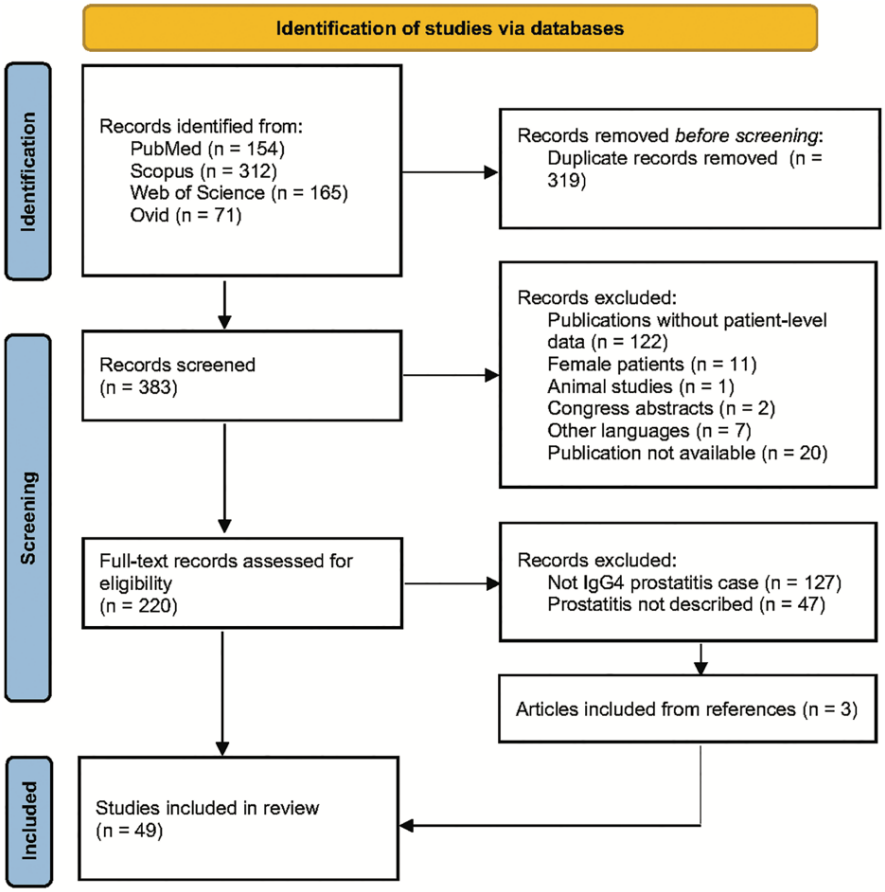

Fig. 1. PRISMA flow diagram.

Disease characteristics

The median age at presentation was 64 years (range 20–82), with a mean of 61±14.3 years, indicating that IgG4-related prostatitis predominantly affects older men, although younger individuals have also been reported. The duration of disease varied widely, with a median of 18 months (range 1–96; mean ± SD = 23±22.3 months), reflecting both acute and chronic courses.

The number of non-prostatic organs involved ranged from 0 to 7, with a median of 2 (interquartile range [IQR] 1–3.25). Most patients had involvement of two to four organs (28/65; 43.1%), while multiorgan disease (≥2 organs) was observed in 37 of 64 evaluable cases (57.8%). Isolated prostatic disease was uncommon, occurring in only 4 of 65 patients (6.2%). The demographics, clinical features and outcomes across isolated and multiorgan cases are available in Supplementary Table S3.

Serum IgG4 concentrations were elevated in most patients, with a median value of 832 mg/dL (range 5–4,500; mean ± SD=982.8±814.5 mg/dL), although several cases had values within the normal range.

Prostate-specific antigen levels demonstrated marked variability (median 1.5 ng/mL, range 0.01–180; mean ± SD=10±32.5 ng/mL), often prompting initial suspicion of malignancy. Follow-up information was available for 32 patients, with a median duration of 6 months (range 0–96; mean ± S =12±17.5 months), and only a minority were followed beyond one year.

Because the distributions of disease duration, serum IgG4 concentration, and PSA levels were skewed, non-parametric analyses were applied. Spearman's rank correlation revealed no significant association between serum IgG4 concentration and disease duration (ρ= -0.18, p=0.30), PSA level (ρ= -0.05, p=0.81), or extent of multiorgan involvement (ρ=0.08, p=0.54). When patients were stratified by the number of organs affected (0, 1, 2–4, and 5–7), IgG4 concentrations differed significantly among groups (Kruskal-Wallis test, p=0.01). Patients with extensive multiorgan involvement (5–7 organs) exhibited the highest IgG4 concentrations (median 1,690 mg/dL [IQR 784]), followed by those with intermediate involvement (2–4 organs; median 836 mg/dL [IQR 891]) and single-organ disease (median 980.5 mg/dL [IQR 822]), suggesting a non-linear relationship between IgG4 level and disease extent.

Prostate-related symptoms

Among the 65 patients included, 33 (50.8%) reported at least one prostate-related symptom, whereas 20 (30.8%) were asymptomatic; information was unavailable for 12 patients (18.5%). Detailed symptom data were available for 53 individuals. The most frequent presentation was lower urinary tract symptoms (LUTS), occurring in 21 patients (39.6%). Other reported complaints included urinary hesitancy or dysuria (each 11.3%), urinary retention (9.4%), urinary frequency (9.4%), abdominal pain (11.3%), and nocturia (5.7%).

Benign prostatic hyperplasia and malignancy

Benign prostatic hyperplasia (BPH)

was reported in 13 of 65 patients (20.0%), while 41 patients (63.1%) had no evidence of BPH; data were missing for 11 patients (16.9%). Malignancy was identified in 12 patients (18.5%). Prostate adenocarcinoma (PAD) was the most frequent diagnosis (3/12; 25%). Other reported malignancies included lymphoma (*e.g.* diffuse large B-cell lymphoma), metastatic PAD, bladder carcinoma, rectal neuroendocrine tumour, gastric carcinoma, and Castleman disease, each representing a single case (8.3%).

Treatment and outcome

Treatment information was available for 61 patients. Glucocorticoid therapy, predominantly prednisone, was the most frequently used approach (45/61; 69.2%). Additional immunosuppressive agents were reported in selected cases, most often in combination with corticosteroids, including methotrexate (4/61; 6.6%), rituximab (3/61; 4.9%), azathioprine (2/61; 3.3%), cyclophosphamide (2/61; 3.3%), and mycophenolate mofetil (1/61; 1.6%). Surgical management was also undertaken in several patients, comprising transurethral resection of the prostate (TURP, n=10), suprapubic prostatectomy (n=1), and radical prostatectomy (n=1). Rare interventions included dupilumab in one patient and R-CHOP chemotherapy in a patient with concomitant lymphoma.

Clinical outcomes were available for 53 of 65 patients (81.5%). Among those with evaluable data, complete response (CR) occurred in 27 cases (50.9%), partial response (PR) in 23 (43.4%), and death in 3 (5.7%). The distribution of outcomes by treatment modality is summarised in Table I, showing that clinical response varied significantly according to therapy received ($p<0.001$). Complete response was most frequently observed in patients treated with glucocorticoids or by surgical intervention, whereas those receiving chemotherapy alone or lack of immunosuppressive treatment demonstrated limited improvement or poor outcomes.

We next evaluated whether the presence of malignancy influenced clinical outcomes. Point-biserial correlation analysis demonstrated a moderate positive association between malignancy and death ($r=0.27$, $p=0.028$) and a moderate negative association between malignancy and complete response ($r=-0.24$, $p=0.054$). A chi-square test further confirmed a significant relationship between malignancy status and outcome distribution ($\chi^2 = 9.83$, $p=0.020$), with patients with cancer less likely to achieve complete response and more likely to experience death than those without malignancy.

To explore whether disease extent influenced outcomes, patients were stratified according to the number of non-prostatic organs involved (0, 1, 2–4, and 5–7). The distribution of outcomes differed significantly across these categories ($\chi^2 = 13.16$, $df = 6$, $p=0.041$). Deaths occurred only among patients with isolated prostatic disease (n=1) and those with extensive multiorgan involvement (5–7 organs, n=2), whereas no deaths were reported in patients with limited systemic disease (1–4 organs). Complete and partial responses were observed across all categories. This pattern suggests a biphasic risk distribution, with poorer outcomes at both extremes – likely reflecting unrecognised systemic disease in isolated cases and greater inflammatory or fibrotic burden in those with widespread organ involvement.

Table I. Distribution of outcomes across treatment categories.

Treatment category	Complete response (CR)	Partial response (PR)	Death	Missing outcome
Immunosuppressive only	13	19	1	5
Invasive only	10	0	0	0
Immunosuppressive + chemotherapy	3	2	0	1
Immunosuppressive + invasive	1	0	0	0
Chemotherapy only	0	1	0	0
Chemotherapy + invasive	0	1	0	0
No treatment	0	0	2	6

CR: complete response; PR: partial response.

Discussion

IgG4-related disease (IgG4-RD) is a systemic fibroinflammatory disorder characterised by tumefactive lesions, a dense lymphoplasmacytic infiltrate rich in IgG4-positive plasma cells, and storiform fibrosis (2, 4, 11, 12). Although first recognised more than a decade ago, prostatic involvement remains one of its least explored and most under-recognised manifestations (8, 10, 11, 63). Emerging work in IgG4-RD implicates aberrant B-cell activation with expansion of circulating plasmablasts, T-follicular helper cell signalling, and profibrotic stromal activation as central drivers of disease (2, 5-7, 11, 12). Prostatic involvement may reflect chemokine-mediated homing of plasmablasts to glandular stromal niches, with subsequent immune-fibroblast crosstalk promoting storiform fibrosis and mass-forming lesions. The frequent coexistence of other exocrine-gland phenotypes (*e.g.* pancreas, salivary glands) in affected patients supports the concept of shared tissue tropism and microenvironmental cues that favour IgG4-rich lymphoplasmacytic infiltration in the prostate. While specific autoantigens remain to be defined, these mechanisms provide a biologically plausible framework for the prostate-predominant presentations observed in this review (2, 5-7, 11, 12).

The rarity of IgG4-related prostatitis, its frequent overlap with benign prostatic hyperplasia (BPH) and prostate cancer, and the lack of disease-specific biomarkers contribute to diagnostic delays and underdiagnosis (13-16). This systematic review addresses an unexplored aspect of the IgG4-RD spectrum by consolidating all published evidence on IgG4-related prostatitis, offering a unified description of its systemic associations, clinical features, and treatment outcomes.

This systematic review of 66 cases from 49 studies represents the most comprehensive synthesis to date. The disease predominantly affects older men (median age 64 years) – the same

demographic at risk for BPH and prostate cancer – making clinical distinction particularly challenging (64-66). The median delay of 18 months from symptom onset to diagnosis reflects both the indolent course and low clinical awareness of this entity (11, 12).

Prostate-specific antigen (PSA) levels were highly variable (0.01–180 ng/mL) and did not correlate with serum IgG4 levels or disease duration, confirming that PSA is an unreliable disease marker. In clinical practice, elevated PSA often prompts investigations for BPH or malignancy; however, in IgG4-related prostatitis, such elevations may reflect inflammatory or fibrotic activity rather than neoplasia (13-16). The frequent occurrence of lower urinary tract symptoms (LUTS) – the predominant presenting feature – further complicates differentiation, as these symptoms are non-specific and overlap extensively with those of other prostatic conditions (13-16, 65).

Our review reaffirms that IgG4-related prostatitis is most commonly a manifestation of systemic IgG4-RD, rather than a prostate-limited disease (3, 4, 8, 10, 63). More than half of reported patients (57.8%) had multiorgan involvement, while only 6.2% had disease confined solely to the prostate. This distribution is consistent with prior reports suggesting that isolated prostatic IgG4 involvement is exceptional; for instance, Yoshimura *et al*. first described such involvement in the setting of autoimmune pancreatitis (14). Clinicians suspecting IgG4-related prostatitis should routinely assess for associated pancreatic, renal, retroperitoneal, salivary, and biliary disease, in line with typical IgG4-RD phenotypes such as autoimmune pancreatitis or retroperitoneal fibrosis (12-14).

We observed a wide range of serum IgG4 concentrations (5–4,500 mg/dL), illustrating the heterogeneity of systemic involvement. Cases with extensive organ involvement (5–7 organs) had notably higher median IgG4 concentrations (1,690 mg/dL), consistent with the notion that elevated IgG4 levels often parallel disease burden (2, 11, 12, 63). However, the relationship was not linear: patients with intermediate multiorgan disease sometimes had lower values than those with fewer organs involved. This mirrors findings in other IgG4-RD phenotypes, in which serum IgG4 correlates imperfectly with disease severity and is limited as a monitoring biomarker (8, 11, 12, 63). Therefore, while elevated serum IgG4 remains a supportive diagnostic tool, its utility for stratifying severity or tracking response is constrained in the prostatic context.

Therapeutic outcomes varied significantly across treatment modalities ($p<0.001$). Corticosteroids – predominantly prednisone – were the mainstay of therapy (used in 69.2% of cases) and generally produced favourable responses, reaffirming their status as first-line treatment in IgG4-RD (8, 11, 67). These results are consistent with broader experience in IgG4-related pancreatitis, sialadenitis, and retroperitoneal fibrosis, where glucocorticoids rapidly induce clinical and radiological improvement in most patients (8, 63, 67). Relapse, however, remains common in systemic disease after tapering or discontinuation, underscoring the need for individualised maintenance strategies (8, 67).

By contrast, outcomes among patients treated with combined immunosuppressive or chemotherapeutic regimens were heterogeneous. Evidence from other organ-specific IgG4-RD manifestations indicates that steroid-sparing immunosuppressants (*e.g.* azathioprine, methotrexate, mycophenolate mofetil) or B-cell-depleting therapy with rituximab can be considered in recurrent, refractory, or multiorgan disease (8, 67). Whether such strategies are beneficial in IgG4-related prostatitis remains to be determined through prospective, multicentre studies.

A notable observation in this review was the excellent local outcomes reported after surgical intervention, primarily transurethral resection of the prostate (TURP). All 10 patients treated with surgery alone achieved complete resolution of urinary symptoms and histologically confirmed clearance of the prostatic lesion during follow-up. In such cases, surgery may provide both diagnostic confirmation and effective local disease control by removing the fibroinflammatory tissue mass responsible for obstruction. However, given that IgG4-RD is a systemic immune-mediated condition, surgical resection cannot prevent disease activity or recurrence in other organs. Therefore, even after prostate removal, ongoing clinical and serological surveillance remains warranted to monitor for systemic relapse.

The clinical profile we observed – males, older age, steroid responsiveness, and variable biomarker performance – aligns with broader IgG4-RD experience while also underscoring organ-specific heterogeneity (60). For example, IgG4-related hypophysitis (pituitary) often presents with endocrine deficits and mass-effect on MRI, whereas IgG4-related thyroid disease can resemble Hashimoto thyroiditis or Riedel-type fibroinflammation; both entities share steroid responsiveness but rely on different organ-specific investigations (68-71). By contrast, prostatic disease predominantly manifests with lower urinary tract obstruction and fluctuating PSA, a marker that correlates poorly with disease activity. These contrasts emphasise the need for phenotype-tailored diagnostic pathways within a unified IgG4-RD framework (8, 11, 63).

Malignancy was identified in 18.5% of patients, and its presence correlated with poorer outcomes. Previous reports have similarly documented an increased risk of synchronous or metachronous malignancies in IgG4-RD, although the causal relationship remains uncertain (72-74). Deaths occurred only in patients with either isolated prostatic disease or extensive multiorgan involvement, suggesting a biphasic risk pattern – likely reflecting delayed recognition in localised disease and higher systemic burden in disseminated forms.

Imaging plays a supportive yet essential role in the diagnostic evaluation of IgG4-related prostatitis (23, 27, 36, 41, 47, 75). Multiparametric MRI and CT are the most commonly used modalities and may reveal diffuse gland enlargement or focal lesions mimicking carcinoma (27, 46). FDG-PET/CT can identify hypermetabolic prostatic lesions and, crucially, detect synchronous involvement of other organs – particu-

larly the pancreas, kidneys, or retroperitoneum – helping establish systemic disease (23, 24, 47, 51, 75). However, radiologic features are not pathognomonic and frequently overlap with BPH, chronic prostatitis, or malignancy (35, 76). In practical terms, in patients with obstructive urinary symptoms and variable PSA, multiparametric prostate MRI helps define focal vs diffuse involvement and exclude frank carcinoma; when IgG4-RD is suspected, FDG-PET/CT is useful to detect multiorgan disease and to direct biopsy to the most accessible, diagnostically informative site. Because radiologic appearances are not pathognomonic, histopathology remains definitive, and imaging should be interpreted in concert with serology and tissue findings (47, 75-77). Standardised imaging protocols and longitudinal imaging follow-up remain unmet needs in this field.

Several limitations of this review must be acknowledged. First, publication bias is inherent: case reports and small series are more likely to describe atypical or severe presentations. Second, the retrospective nature of the included studies and variable quality of reporting led to incomplete datasets for several parameters, reducing the strength of correlative analyses. Third, diagnostic inconsistency – stemming from evolving definitions, heterogeneous histopathologic criteria, and lack of standardised imaging – may limit comparability. Fourth, treatment heterogeneity (variations in steroid dose, use of adjunct immunosuppressants, and timing of surgical intervention) complicates evaluation of therapeutic efficacy. Finally, the short median follow-up (6 months) precludes conclusions regarding relapse risk or long-term outcomes.

Conclusion

IgG4-related prostatitis is a rare, underrecognised manifestation of systemic IgG4-related disease that predominantly affects older men – an age group already at risk for benign prostatic hyperplasia and prostate cancer. Its chronic, indolent course and overlapping clinical and laboratory features complicate diagnosis, necessitating a high index of suspicion and thorough systemic evaluation. Serum IgG4 levels and imaging findings are supportive but not diagnostic, making histopathology essential. Glucocorticoid therapy remains the cornerstone of management, with surgical intervention reserved for selected cases presenting with obstruction. While treatment outcomes are generally favourable, vigilance for relapse and malignancy is warranted. These findings highlight the need for standardised diagnostic criteria, longitudinal follow-up, and collaborative multicentre research to refine management and improve recognition of this uncommon but clinically significant condition.

Acknowledgments

This work was supported by Romania's National Recovery and Resilience Plan grant of the Romanian Ministry of Investments and European Projects (PNRR-III-C9-2023-I8, CF 199/31.07.2023).

References

1. KAMISAWA T, ZEN Y, PILLAI S, STONE JH: IgG4-related disease. *Lancet* 2015; 385: 1460-71. https://doi.org/10.1016/s0140-6736(14)60720-0
2. PERUGINO CA, STONE JH: IgG4-related disease: an update on pathophysiology and implications for clinical care. *Nat Rev Rheumatol* 2020; 16: 702-14. https://doi.org/10.1038/s41584-020-0500-7
3. STONE JH, ZEN Y, DESHPANDE V: IgG4-related disease. *N Engl J Med* 2012; 366: 539–51. https://doi.org/10.1056/nejmra1104650
4. DESHPANDE V, ZEN Y, CHAN JK *et al*.: Consensus statement on the pathology of IgG4-related disease. *Mod Pathol* 2012; 25: 1181-92. https://doi.org/10.10/modpathol.2012.72
5. DELLA-TORRE E, LANZILLOTTA M, DOGLIONI C: Immunology of IgG4-related disease. *Clin Exp Immunol* 2015; 181: 191-206. https://doi.org/10.1111/cei.12641
6. LIU J, YIN W, WESTERBERG LS *et al*.: Immune dysregulation in IgG4-related disease. *Front Immunol* 2021; 12. https://doi.org/10.3389/fimmu.2021.738540
7. LIU C, ZHANG P, ZHANG W: Immunological mechanism of IgG4-related disease. *J Transl* Autoimmun 2020; 3: 100047. https://doi.org/10.1016/j.jtauto.2020.100047
8. STONE JH: IgG4-related disease: Nomenclature, clinical features, and treatment. *Semin Diagn Pathol* 2012; 29: 177-90. https://doi.org/10.1053/j.semdp.2012.08.002
9. UMEHARA H, OKAZAKI K, KAWA S *et al*.: The 2020 revised comprehensive diagnostic (RCD) criteria for IgG4-RD. *Mod Rheumatol* 2021; 31: 529-33. https://doi.org/10.1080/14397595.2020.1859710
10. KHOSROSHAHI A, STONE JH: A clinical overview of IgG4-related systemic disease. *Curr Opin Rheumatol* 2011; 23: 57-66. https://doi.org/10.1097/bor.0b013e3283418057
11. PEYRONEL F, DELLA-TORRE E, MARITATI F *et al*.: IgG4-related disease and other fibroinflammatory conditions. *Nat Rev Rheumatol* 2025; 21: 275-90. https://doi.org/10.1038/s41584-025-01240-x
12. LANZILLOTTA M, CULVER E, SHARMA A *et al*.: Fibrotic phenotype of IgG4-related disease. *Lancet Rheumatol* 2024; 6: e469-80. https://doi.org/10.1016/s2665-9913(23)00299-0
13. UEHARA T, HAMANO H, KAWAKAMI M *et al*.: Autoimmune pancreatitis-associated prostatitis: distinct clinicopathological entity. *Pathol Int* 2008; 58: 118-25. https://doi.org/10.1111/j.1440-1827.2007.02199.x
14. YOSHIMURA Y, TAKEDA SI, IEKI Y, TAKAZAKURA E, KOIZUMI H, TAKAGAWA K: IgG4-associated prostatitis complicating autoimmune pancreatitis. *Intern Med* 2006; 45: 897-901. https://doi.org/10.2169/internalmedicine.45.1752
15. SUZUKI K, AKIYAMA M, SAITO K, SHIMANUKI K, KANEKO Y: Isolated IgG4-related prostatitis masquerading as prostate cancer: a diagnostic pitfall in patients with elevated prostate-specific antigen and prostatic mass. *Rheumatol Int* 2025; 45: 204. https://doi.org/10.1007/s00296-025-05960-x
16. JAZDAREHEE A, AHRARI A, BOWIE D *et al*.: IgG4-related prostatitis manifesting as urinary obstruction in a 28-year-old male. *BMC Urol* 2022; 22. https://doi.org/10.1186/s12894-022-00980-2
17. KOTHA S, TRITTO G, WONG T, BERRY P: IgG4-related disease: long-term natural history and management of a relapsing multisystem disease entity. *BMJ Case Rep* 2017. https://doi.org/10.1136/bcr-2017-219897
18. VERMA S, KHURSHID L, VOLETI PR, MALAVIYA AN: Immunoglobulin G4-related disease, constitutional symptoms, human leukocyte antigen B27 positivity, and sacroiliitis. *Indian J Rheumatol* 2020; 15.
19. SAEKI T, NISHI S, IMAI N *et al*.: Clinicopathological characteristics of patients with IgG4-related tubulointerstitial nephritis. *Kidney Int* 2010; 78: 1016-23. https://doi.org/10.1038/ki.2010.271
20. NISHIMORI I, KOHSAKI T, ONISHI S *et al*.: IgG4-related autoimmune prostatitis: two cases with or without autoimmune pancreatitis. *Intern Med* 2007; 46: 1983-89. https://doi.org/10.2169/internalmedicine.46.0452
21. CHEN H, LIN W, WANG Q *et al*.: IgG4-related disease in a Chinese cohort: a prospective study. *Scand J Rheumatol* 2014; 43: 70-74. https://doi.org/10.3109/03009742.2013.822094
22. SCHÄFER VS, AGAIMY A, WACHTER D *et al*.: Multi-organ involvement in refractory IgG4-related disease. *Aktuelle Rheumatologie* 2015; 40: 304-8. https://doi.org/10.1055/s-0034-1383585
23. TANIGUCHI Y, OGATA K, INOUE K, TERADA Y: Clinical implication of FDG-PET/CT in monitoring disease activity in IgG4-related disease. *Rheumatology* (Oxford) 2013; 52: 1508. https://doi.org/10.1093/rheumatology/ket182

24. HUANG W, QIU Y, WANG A, KANG L: Pancreatic cancer detected with 18F-FDG PET/CT in a case of IgG4-related disease. *Rev Esp Enferm Dig* 2023; 115: 742-44. https://doi.org/10.17235/reed.2023.9870/2023
25. SIMPSON RS, LAU SKC, LEE JK: Dupilumab as a novel steroid-sparing treatment for IgG4-related disease. *Ann Rheum Dis* 2020; 79: 549-50. https://doi.org/10.1136/annrheumdis-2019-216368
26. FLANAGAN EP, CHOWDHARY VR, MCCARTHY JT, SMYRK TC, CHARI ST, KUMAR N: IgG4-related (neurologic) disease: diagnostic challenges, clinical clues and expanding spectrum. *Int J Rheum Dis* 2015; 18: 807-9. https://doi.org/10.1111/1756-185x.12465
27. MEDLICOTT SAC, ORYSCHAK A, TRPKOV K: IgG4 prostatitis associated with prostatic adenocarcinoma: a case report and literature review. *Hum Pathol Case Rep* 2018; 14: 8-11. https://doi.org/10.1016/j.ehpc.2018.05.005
28. HIRATA Y, FUKAE J, NISHIDA A *et al*.: Long-standing IgG4-related ophthalmic disease dramatically improved after steroid therapy. *Intern Med* 2018; 57: 2879-83. https://doi.org/10.2169/internalmedicine.0300-17
29. STRAINIENE S, SARLAUSKAS L, SAVLAN I, LIAKINA V, STUNDIENE I, VALANTINAS J: Multi-organ IgG4-related disease continues to mislead clinicians: a case report and literature review. *World J Clin Cases* 2020; 8: 3267-79. https://doi.org/10.12998/wjcc.v8.i15.3267
30. JOSHI PV, NIKALJE AM, KULKARNI M, BORDE ND: AuntMinnie fluorodeoxyglucose positron emission tomography-computed tomography leads to diagnosis of immunoglobulin G4-related disease. *Indian J Nucl Med* 2022; 37: 376-78. https://doi.org/10.4103/ijnm.ijnm_80_22
31. MIYASHITA T, YOSHIOKA K, NAKAMURA T *et al*.: A case of lymphomatoid granulomatosis-like lung lesions with abundant infiltrating IgG4-positive plasma cells whose serum IgG4 levels became high following the start of corticosteroid therapy. *Intern Med* 2010; 49: 2007-11. https://doi.org/10.2169/internalmedicine.49.3630
32. SAKAMAKI A, KAMIMURA K, SHIOJI K *et al*.: Immunoglobulin G4-related disease with several inflammatory foci. *Intern Med* 2013; 52: 457-62. https://doi.org/10.2169/internalmedicine.52.9239
33. HORITA S, FUJII H, MIZUSHIMA I *et al*.: A case of IgG4-related tubulointerstitial nephritis and membranous glomerulonephritis during the clinical course of gastric cancer: Imaging features of IgG4-related kidney disease. *Mod Rheumatol* 2019; 29: 542-46. https://doi.org/10.1080/14397595.2016.1245238
34. JEERANGSAPASUK W, CHAROENPITAKCHAI M, SORNWIBOONSAK P, CHATKRAILERT A: A challenging case of IgG4-related kidney disease accompanied with positive serologic tests of lupus erythematosus. *Nephrology* (Carlton) 2025; 30: e14429. https://doi.org/10.1111/nep.14429
35. LEE ZR, LAI YK, M L, KHOR LY, TAY KJ, LAW YM: Focal IgG4-related periprostatic "PI-RADS 5" pseudotumor mimicking prostatic adenocarcinoma. *Radiol Case Rep* 2023; 18: 2158-64. https://doi.org/10.1016/j.radcr.2023.02.055
36. NGUYEN VX, DE PETRIS G, NGUYEN BD: Usefulness of PET/CT imaging in systemic IgG4-related sclerosing disease. A report of three cases. *JOP* 2011; 12: 297-305. https://doi.org/10.6092/1590-8577/3302
37. CONANT JL, BULLIS SSM, WILBURN C: Perifollicular concentric granulomas: a clue to IgG4-related lymphadenopathy. *J Hematop* 2024; 17: 227-30. https://doi.org/10.1007/s12308-024-00615-5
38. JAIN V, PANDEY PK, BIHARI C: Steroid-responsive IgG4-related disease with isolated prostatic involvement: an unusual presentation with elevated serum PSA. *Indian J Urol* 2016; 32: 166-68. https://doi.org/10.4103/0970-1591.174784
39. DY RV, ATLAS SA: So many organs, 1 diagnosis: IgG4-related disease. *Am J Med* 2014; 127: 195-97. https://doi.org/10.1016/j.amjmed.2013.12.008
40. MIGITA K, MIYASHITA T, MIZUNO A *et al*.: IgG4-related epididymo-orchitis associated with bladder cancer: possible involvement of BAFF/BAFF-R interaction in IgG4-related urogenital disease. *Mod Rheumatol* 2014; 24: 188-94. https://doi.org/10.3109/14397595.2013.852841
41. TAKAHASHI H, TSUBOI H, OGISHIMA H *et al*.: [18F]fluorodeoxyglucose positron emission tomography/computed tomography can reveal subclinical prostatitis in a patient with IgG4-related disease. *Rheumatology* (Oxford) 2015; 54: 1113. https://doi.org/10.1093/rheumatology/kev099
42. YUEH HZ, TUNG KK, TUNG CF: IgG4-related pseudotumors mimicking metastases in liver and lungs. *Case Rep Gastroenterol* 2021; 15: 163-70. https://doi.org/10.1159/000512410
43. HART PA, SMYRK TC, CHARI ST: IgG4-related prostatitis: a rare cause of steroid-responsive obstructive urinary symptoms. *Int J Urol* 2013; 20: 132-34. https://doi.org/10.1111/j.1442-2042.2012.03194.x
44. KODA R, TSUCHIDA M, IINO N *et al*.: IgG4-related periarteritis successfully diagnosed by an alternative prostate biopsy. *Intern Med* 2019; 58: 2401-6. https://doi.org/10.2169/internalmedicine.2723-19
45. FUJII M, SATO Y, OHARA N *et al*.: Systemic IgG4-related disease with extensive peripheral nerve involvement that progressed from localized IgG4-related lymphadenopathy: an autopsy case. *Diagn Pathol* 2014; 9: 41. https://doi.org/10.1186/1746-1596-9-41
46. DONG P, WANG L, LI L: Bilateral orbital involvement of IgG4-related disease detected on 18F-Fluoro-2-deoxy-D-glucose positron emission tomography/computed tomography: a clinical case report. *Medicine* 2019; 98: e18138. https://doi.org/10.1097/md.0000000000018138
47. VANKADARI K, MITTAL BR, KUMAR R, SINGH H, BHATTACHARYA A, KOCHHAR R: Isolated involvement of prostate gland by immunoglobulin G4-related disease diagnosed with the help of FDG PET/CT. *Clin Nucl Med* 2019; 44: e537-39. https:/doi.org/10.1097/rlu.0000000000002689
48. EZAKI T, AKATSUKA S, SANJO T, MASUDA T: Symptomatic IgG4-related prostatitis simultaneously diagnosed with aggressive prostate cancer. *Case Rep Urol* 2020;2020:6045328. https://doi.org/10.1155/2020/6045328
49. KAGAWA M, TAKESHITA H, MORIYAMA S, ADACHI A, CHIBA K, NORO A: IgG4-related prostatitis impairs objective urinary function as with benign prostate hyperplasia: a case report successfully treated with transurethral resection. *Low Urin Tract Symptoms* 2014; 6: 187-89. https://doi.org/10.1111/luts.12060
50. BUIJS J, MAILLETTE DE BUY WENNIGER L, VAN LEENDERS G *et al*.: Immunoglobulin G4-related prostatitis: a case-control study focusing on clinical and pathologic characteristics. *Urology* 2014; 83: 521-26. https://doi.org/10.1016/j.urology.2013.10.052
51. PAN Q, LUO Y, ZHANG W: Recurrent immunoglobulin G4-related disease shown on 18F-FDG and 68Ga-FAPI PET/CT. *Clin Nucl Med* 2020; 45: 312-13. https://doi.org/10.1097/rlu.0000000000002919
52. LI D, KAN Y, FU F *et al*.: IgG4-related prostatitis progressed from localized IgG4-related lymphadenopathy. *Int J Clin Exp Pathol* 2015; 8: 11747-52.
53. MATSUBAYASHI H, FURUKAWA H, MAEDA A *et al*.: Usefulness of positron emission tomography in the evaluation of distribution and activity of systemic lesions associated with autoimmune pancreatitis. *Pancreatology* 2009; 9: 694-99. https://doi.org/10.1159/000199439
54. BOURLON MT, SÁNCHEZ-ÁVILA M, CHABLÉ-MONTERO F, ARCEO-OLAIZ R: IgG4-related autoimmune prostatitis: is it an unusual or underdiagnosed manifestation of IgG4-related disease? *Case Rep Urol* 2013; 2013: 295472. https://doi.org/10.1155/2013/295472
55. MITSUYAMA T, NISHIO A, TAKAOKA M *et al*.: A case of IgG4-related disease associated with diffuse large B cell lymphoma. *Clin J Gastroenterol* 2013; 6: 63-68. https://doi.org/10.1007/s12328-012-0345-y
56. FOLEY RW, REDMAN SL, GRAHAM RN *et al*.: Pleural, pancreatic and prostatic involvement in IgG4-related disease mimicking pancreatic head malignancy. *BJR Case Rep* 2020; 6: 20190110. https://doi.org/10.1259/bjrcr.20190110
57. UEKI H, NISHINA Y, SUMII K *et al*.: [A case of IgG4-related disease diagnosed by prostate biopsy]. *Hinyokika Kiyo* 2019; 65: 381-84. https://doi.org/10.14989/actauroljap_65_9_381
58. CHO Y-J, JUNG W-Y, LEE S-Y, SONG J-S, PARK H-J: Perirenal capsule and scrotal involvement in immunoglobulin G4-related kidney disease: case-based review. *Rheumatol Int* 2018; 38: 1941-48. https://doi.org/10.1007/s00296-018-4089-y
59. AOKI S, MORINAGA S, KAWAI N *et al*.: Immunoglobulin G4-related disease diagnosed by prostate biopsy: a case report. *J Med Case Rep* 2022; 16: 345. https://doi.org/10.1186/s13256-022-03611-4
60. YU Y, WANG Q-Q, JIAN L, YANG D-C: Infrequent organ involvement in immunoglobulin G4-related prostate disease: a case report. *World J Clin Cases* 2023; 11: 7485-91. https://doi.org/10.12998/wjcc.v11.i30.7485
61. LI X-K, LI N, ZHANG X-H, PAN L-L: A case report of multisite IgG4-related disease diag-

nosed by ultrasound-guided biopsies of the kidney and prostate. *Asian J Surg* 2023; 46: 4008-10. https://doi.org/10.1016/j.asjsur.2023.04.023
62. INUI K, NAKAGAWA Y, WATANABE H *et al*.: Retroperitoneal fibrosis associated with IgG4-related disease diagnosed by prostate biopsy developed with acute post-renal renal failure: a case report. *Urol Case Rep* 2017; 16: 9. https://doi.org/10.1016/j.eucr.2017.09.017
63. WALLACE ZS, ZHANG Y, PERUGINO CA, NADEN R, CHOI HK, STONE JH: Clinical phenotypes of IgG4-related disease: an analysis of two international cross-sectional cohorts. *Ann Rheum Dis* 2019; 78: 406-12. https://doi.org/10.1136/annrheumdis-2018-214603
64. ZAHED H, FENG X, SHEIKH M *et al*.: Age at diagnosis for lung, colon, breast and prostate cancers: An international comparative study. *Int J Cancer* 2024; 154: 28-40. https://doi.org/10.1002/ijc.34671
65. CHEN X, YANG S, HE Z *et al*.: Comprehensive analysis of the global, regional, and national burden of benign prostatic hyperplasia from 1990 to 2021. *Sci Rep* 2025; 15: 1-14. https://doi.org/10.1038/s41598-025-90229-3;subjmeta
66. LIM KB: Epidemiology of clinical benign prostatic hyperplasia. *Asian J Urol* 2017; 4: 148-51. https://doi.org/10.1016/j.ajur.2017.06.004
67. GONZÁLEZ-GARCÍA A, STARITA-FAJARDO G, LUCENA LÓPEZ D *et al*.: New developments in the treatment of IgG4-related disease: a comprehensive clinical approach. *J Clin Med* 2025; 14: 6774. https://doi.org/10.3390/jcm14196774
68. LIU Y, WANG L, ZHANG W *et al*.: Hypophyseal involvement in immunoglobulin G4-related disease: a retrospective study from a single tertiary center. *Int J Endocrinol* 2018; 2018. https://doi.org/10.1155/2018/7637435
69. BHARGAVA R, HUSSEIN Z, DORWARD NL *et al*.: IgG4-related hypophysitis: a retrospective cohort study. *Acta Neurochir* (Wien) 2022; 164: 2095-103. https://doi.org/10.1007/S00701-022-05231-9
70. NAVARRO-SÁNCHEZ V, MARÍN-CASTAÑEDA LA, GALLEGOS CA, QUIROZ O, AHUMADA-AYALA M: IgG4-related fibrous thyroiditis (Riedel's Thyroiditis): a case report. *Am J Case Rep* 2020; 21: 1-5. https://doi.org/10.12659/ajcr.928046
71. TAKESHIMA K, LI Y, KAKUDO K *et al*.: Proposal of diagnostic criteria for IgG4-related thyroid disease. *Endocr J* 2021; 68: 1-6. https://doi.org/10.1507/endocrj.ej20-0557
72. TANG H, YANG H, ZHANG P *et al*.: Malignancy and IgG4-related disease: the incidence, related factors and prognosis from a prospective cohort study in China. *Sci Rep* 2020; 10: 1-7. https://doi.org/10.1038/s41598-020-61585-z;techmeta
73. ASANO J, WATANABE T, OGUCHI T *et al*.: Association between immunoglobulin G4-related disease and malignancy within 12 years after diagnosis: an analysis after longterm followup. *J Rheumatol* 2015; 42: 2135-42. https://doi.org/10.3899/jrheum.150436
74. WALLACE ZS, WALLACE CJ, LU N, CHOI HK, STONE JH: Association of IgG4-related disease with history of malignancy. *Arthritis Rheum* 2016; 68: 2283-89. https://doi.org/10.1002/art.39773
75. DILLON J, DART A, SUTHERLAND T: Imaging features of immunoglobulin G4-related disease. *J Med Imaging Radiat Oncol* 2016; 60: 707-13. https://doi.org/10.1111/1754-9485.12511
76. HUYNH KN, KONG MJ, NGUYEN BD: Anatomic and functional imaging of immunoglobulin G4-related disease and its mimics. *RadioGraphics* 2023; 43. https://doi.org/10.1148/rg.220097
77. TANIGUCHI Y, OGATA K, INOUE K, TERADA Y: Clinical implication of FDG-PET/CT in monitoring disease activity in IgG4-related disease. *Rheumatology* (Oxford) 2013; 52: 1508. https://doi.org/10.1093/rheumatology/ket182