Comment on: IgG4-related prostatitis: expanding the spectrum of IgG4-related disease. A systematic review

Sirs,

We read with great interest the paper by Pamfil *et al*. published in your journal (1). The authors conducted a systematic literature review to elucidate the concept of prostatitis in immunoglobulin G4-related disease (IgG4-RD), a rare and underrecognised manifestation of this disease. They reported that most reported cases are accompanied by other systemic features of IgG4-RD, and that prostatic malignancy coexisted in 18.5% of the reported cases. Serum IgG4 and prostate-specific antigen (PSA) levels, as well as imaging findings, were not definitive for distinguishing malignancy, thereby necessitating precise histopathological evaluation. Recently, we encountered an instructive case with the co-existence of IgG4-RD in retroperitoneum and pancreas, along with malignancy in the prostate, all of which are recognised target organs of IgG4-RD. This case underscores the importance of performing biopsies of affected organs, even when the diagnosis of IgG4-RD has already been pathologically confirmed in a single organ.

A 72-year-old male presented to the urology department with a two-month history of back pain. He had no prior medical history, including malignancy, while had a history of smoking and cedar pollen allergy. Laboratory tests revealed elevated creatinine (1.82 mg/dL; normal 0.60–1.10) and C-reactive protein levels (2.50 mg/dL; normal ≤0.14), with normal amylase levels. Computed tomography (CT) revealed right hydronephrosis, pancreas swelling, and a retroperitoneal mass surrounding the left kidney (Fig. 1A-B). Based on these CT findings, IgG4-RD was suspected, and serum IgG (2049 mg/dL; normal 861–1747) and IgG4 (667 mg/dL; normal 11–121) levels were markedly elevated. After ureteral stent placement, he was referred to our hospital for further evaluation and treatment.

On admission, physical examination revealed no swelling of the lacrimal and submandibular glands, abdominal tenderness, or skin findings. Histopathological findings obtained from the left peritoneal mass revealed dense infiltration of IgG4-positive plasma cells (Fig. 1C-E), and endoscopic ultrasound revealed a hypoechoic pattern with hyperechoic foci and mild vascularity, suggesting autoimmune pancreatitis (Fig. 1F-G). He was diagnosed with IgG4-RD according to the 2020 revised comprehensive diagnostic criteria for IgG4-RD (2). During malignancy screening, contrast-enhanced CT revealed subtle enhancement of the prostate (Fig. 1H) accompanied by elevated PSA level (40.2 ng/mL; normal 0–4), and prostate biopsy revealed proliferation of

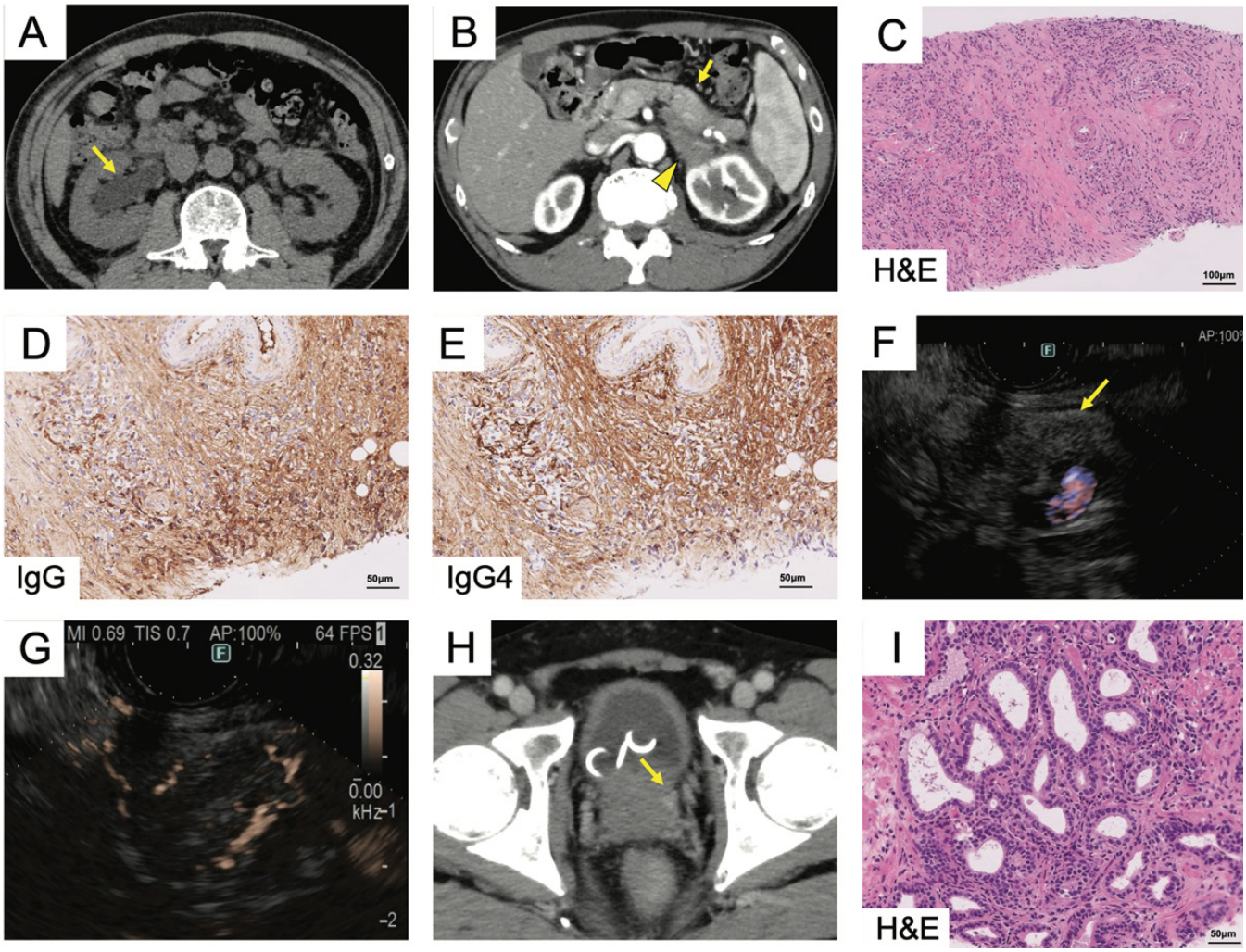

Fig. 1. Clinical and pathological findings of the present case.
Computed tomography (CT) revealed right hydronephrosis (**A**), pancreatic swelling (arrow), and a retroperitoneal mass surrounding the left kidney (arrowhead) (**B**). Biopsy of the peritoneal mass showed dense infiltration of plasma cells (H&E staining) (**C**). Immunostaining showed IgG (**D**) and IgG4-positive plasma cells (**E**). Endoscopic ultrasonography revealed a hypoechoic lesion with hyperechoic foci (arrow) (**F**) and mild vascularity (**G**), findings suggestive of autoimmune pancreatitis. CT revealed subtle enhancement of the prostate (arrow) (H), and prostate biopsy showed proliferation of atypical cells consistent with prostate cancer (**I**).

atypical cells consistent with acinar adenocarcinoma (Fig. 1I). Treatment with prednisolone (40 mg/day; 0.6 mg/kg) for IgG4-RD was initiated after treatment of prostate cancer by radical prostatectomy. Written informed consent for publication of this report was obtained from the patient.

There are several noteworthy aspects of this case. First, IgG4-RD was initially suspected due to retroperitoneal involvement, and biopsy of this site revealed typical pathological features of IgG4-RD. Therefore, if comprehensive malignancy workup was not done, concomitant prostatic involvement might have been overlooked. Second, as the authors and we reported, the prostate can be affected by IgG4-RD and may exhibit imaging findings that mimic malignancy with elevation of PSA level (1, 3); therefore, prostate cancer could be misdiagnosed as IgG4-related prostatitis in patients with a pre-established diagnosis of IgG4-RD when biopsy is not performed; therefore, accurate diagnosis of prostatic involvement by biopsy is indispensable.

Recently, a paraneoplastic phenotype in IgG4-RD has been reported (4, 5), and accumulating evidence indicates an increased risk of malignancy co-occurrence (6); our case re-emphasises the importance of thorough malignancy screening with careful evaluation of each affected organ even when the diagnosis of IgG4-RD has been established in a single organ.

K. Suzuki, *MD*
M. Akiyama, *MD, PhD*
H. Horie, *MD*
K. Shimanuki, *MD*
K. Saito, *MD*
Y. Kaneko, *MD, PhD*

Division of Rheumatology, Department of Internal Medicine, Keio University School of Medicine, Tokyo, Japan.

Please address correspondence to:
Mitsuhiro Akiyama
Division of Rheumatology,
Department of Internal Medicine,
Keio University School of Medicine,
35 Shinanomachi, Shinjuku-ku,
Tokyo 160-8582, Japan.
E-mail: mitsuaki@keio.jp

Competing interests: none declared.

© Copyright Clinical and Experimental Rheumatology 2026.

References

1. PAMFIL C, MIHON MI, SURDU V *et al.*: IgG4-related prostatitis: expanding the spectrum of IgG4-related disease. A systematic review. *Clin Exp Rheumatol* 2026; 44(7): 1341-48. https://doi.org/10.55563/clinexprheumatol/i8eh4g
2. UMEHARA H, OKAZAKI K, KAWA S *et al.*: The 2020 revised comprehensive diagnostic (RCD) criteria for IgG4-RD. *Mod Rheumatol* 2021; 31: 529-33. https://doi.org/10.1080/14397595.2020.1859710
3. SUZUKI K, AKIYAMA M, SAITO K, SHIMANUKI K, KANEKO Y: Isolated IgG4-related prostatitis masquerading as prostate cancer: a diagnostic pitfall in patients with elevated prostate-specific antigen and prostatic mass. *Rheumatol Int* 2025; 5: 204. https://doi.org/10.1007/s00296-025-05960-x
4. TAKANASHI S, AKIYAMA M, FURUHASHI K *et al.*: Distinct impact of malignancy and allergy on the clinical and immunological features of IgG4-related disease. *Clin Exp Rheumatol* 2023; 41: 1754-61. https://doi.org/10.55563/clinexprheumatol/7g2na0
5. AKIYAMA M, ALSHEHRI W, ISHIGAKI S, SAITO K, KANEKO Y: The immunological pathogenesis of IgG4-related disease categorized by clinical characteristics. *Immunol Med* 2024; 1-13. https://doi.org/10.1080/25785826.2024.2407224
6. KELLER-SARMIENTO L, VIAPIANA N, LANZILLOTTA M *et al.*: Increased prevalence of malignancies in patients with IgG4-related disease: implications for clinical care. *Rheumatology* (Oxford) 2025; 64: 1326-32. https://doi.org/10.1093/rheumatology/keae243