

Systemic sclerosis developing in association with the use of interferon alpha therapy for chronic viral hepatitis

R. Solans, J.A. Bosch,
I. Esteban¹, M. Vilardell

Autoimmune Diseases Division and
¹Hepatology Division, Internal Medicine
Department, Vall d'Hebrón University
General Hospital, Barcelona, Spain.

R. Solans, MD; J.A. Bosch, MD;
I. Esteban, MD; M. Vilardell, MA.

Please address correspondence to: Roser
Solans Laqué, MD, Servei de Medicina
Interna-Malalties Autoimmunes,
3^a planta parells, Hospital General
Universitari Vall d'Hebrón,
P^o Vall d'Hebron 119-129, Barcelona
08035, Spain.

E-mail: rsolans@hg.vhebron.es

Received on November 6, 2003; accepted
in revised form on May 12, 2004.

© Copyright CLINICAL AND EXPERIMENTAL
RHEUMATOLOGY 2004.

Key words: Interferon-alpha therapy, chronic active hepatitis C, auto-antibodies; autoimmune disorders, Raynaud's phenomenon, systemic sclerosis.

ABSTRACT

In 1992 interferon alpha (IFN α) was approved by the FDA for the treatment of chronic viral hepatitis B and C. Since then IFN α has been implicated in the development of several autoantibodies as well as in the development or exacerbation of various autoimmune disorders. Herein, we describe a 47-year-old female who developed a limited form of systemic sclerosis (SSc) with lung involvement 6 months after the institution of IFN α therapy for chronic active hepatitis C. There was no family or personal history of autoimmune diseases. We speculate that the immunomodulatory effects of IFN α triggered the clinical manifestations of SSc in this patient. To our knowledge, this is the second case of SSc developing after therapy with IFN α and the first in a patient treated for chronic viral hepatitis C.

Introduction

Interferon-alpha (IFN α) is the treatment of choice in chronic hepatitis C in combination with ribavirin (1). Therapy with IFN α has been shown to induce normalization of the liver function test and sustained remission of viral replication in 35% to 85% of patients, depending on the viral genotype (1). However, this drug may have multiple effects on the immune system. Thus, IFN α may trigger the appearance of organ-specific and non-organ specific autoantibodies, sometimes coupled with the *de novo* development or the exacerbation of some connective tissue diseases such as rheumatoid arthritis, SLE or polymyositis (1-4). Nevertheless, clinically overt autoimmune diseases are rare in association with IFN α therapy (1-4).

Herein we describe a patient who developed a rapid onset of systemic sclerosis (SSc) with lung involvement while receiving treatment with IFN α for chronic active hepatitis C. Discontinuation of the drug clearly improved the symptoms. The close temporal relationship between the onset of IFN α therapy and the development of SSc, as well as the improvement of the disease after cessation of IFN α therapy suggest a causative role for the drug.

Case report

In June 1995, a 47-year-old woman with a past history of blood transfusion, was diagnosed as having chronic active C virus-related hepatitis. She was found to be ANA positive 1:160 with speckled and nucleolar patterns. In February 1996 IFN α therapy (Intron A, Shering-Plough), 3 x 10⁶ U 3 times weekly, was initiated with progressive improvement of the liver function tests and reduction of the HCV viremia.

Six months later, the patient was referred to our out-patient clinic due to bilateral Raynaud's phenomenon (RP) of one month's onset. Physical examination disclosed no abnormalities. Laboratory findings were normal except for positive rheumatoid factor (1:128) and positive ANA (1: 320) with speckled and nucleolar patterns (Table I). Chest X-rays showed no abnormalities. Nail-fold capillaroscopy (NC) was also normal.

Over the next three months the patient experienced a worsening in the severity and frequency of RP, morning stiffness and progressive dyspnea, and was admitted to hospital. Physical examination revealed cutaneous telangiectasia over the hands and neck, finger edema with flexion contractures of the inter-falangeal joints (Fig.1), and bibasilar pulmonary crackles.

Routine laboratory analyses, including liver function tests, were normal. ANA were positive 1:1280 with speckled and nucleolar patterns and PM-Scl specificity (Table I). AMA and antiphospholipid antibodies were negative. Cryoglobulins and HCV-RNA were not detectable in the serum. NC showed tortuous capillaries with a bushy appearance, giant capillaries, and dropout of capillaries.

Pulmonary function tests (PFT) demonstrated a moderate restrictive pattern with a severe decrease in the diffusing capacity for carbon monoxide (Table I). Chest X-ray showed bi-basilar interstitial changes compatible with fibrosis. A high-resolution computed tomography (HRCT) of the lung disclosed diffuse pulmonary fibrosis with patchy areas of ground-glass opacification (Fig. 2). A transbronchial lung biopsy revealed fibrosing alveolitis. Broncho-

Table I. Main clinical and laboratory findings before, during and after IFN alpha therapy.

Variable	February 1996*	September 1996	November 1996 [†]	November 1997	November 2003
ANA	1:160	1:320	1:1280	1:320	1:320
ACA	-	negative	negative	negative	negative
Scl-70	-	negative	negative	negative	negative
Pm-Scl	-	-	positive	positive	positive
RF	-	1:128	1:128	1:128	1:128
Cryoglobulins	not detectable	not detectable	not detectable	not detectable	not detectable
HCV-RNA(copies/ml)	10 ³⁻⁴	not detectable	not detectable	not detectable	not detectable
Raynaud's phenomenon	no	yes	yes (severe)	occasional	yes
Nailfold capillaroscopy	-	no abnormalities	Tortuous and giant capillaries	Tortuous capillaries	Tortuous capillaries
FVC (% predicted)	-	-	55.7%	78.2%	80.4%
DLCO (% predicted)	-	-	39%	71%	77%
HRCT-lung scan	-	-	Extensive pulmonary fibrosis patchy areas of ground-glass	no abnormalities	no abnormalities
Physical examination	no abnormalities	no abnormalities	Cutaneous telangiectasias, finger edema with IF flexion contractures bi-basilar pulmonary crackles	Cutaneous telangiectasias	Sclerodactilia calcinosis
Skin thickness score	0	0	2	0	10

*Date of IFN alpha therapy onset; [†]date of IFN alpha therapy cessation.

ANA: anti-nuclear antibodies; ACA: anti-centromere antibodies; Scl-70: anti-topoisomerase antibodies; Pm-Scl: anti-polymyositis-scleroderma antibodies; RF: rheumatoid factor; HCV-RNA: HCV RNA level, millions of copies/ml; FVC: forced vital capacity; DLCO: diffusing capacity for carbon monoxide; HRCT-lung scan: high-resolution computed tomography of the lung. Skin thickness score: determined according to the modified Rodnan skin thickness score (range 0-51).

alveolar lavage fluid contained 43% alveolar macrophages, 50.8% lymphocytes, 4% granulocytes and 2% eosinophils. No pulmonary hypertension was detected by echocardiography. IFN therapy was interrupted 9 months after the treatment onset, and prednisone 1 mg/kg/day was begun with progressive tapering to withdrawal over the next 6 months. Raynaud's phenomenon, morning stiffness and dyspnea receded rapidly. Six months after the interruption of IFN therapy, finger edema had completely disappeared and only isolated crackles persisted in the lung bases (Table I). One year after stopping IFN therapy, an HRCT lung scan showed no abnormalities (Fig. 2) and the PFT had clearly improved (Table I). However, over the next 6 years the patient went on to develop a limited form of systemic sclerosis (skin thickness score = 10 points), with Raynaud's phenomenon, sclerodactily and calcinosis (Fig.1). No myositis symptoms have been observed during the follow-up. Respiratory symptoms have completely receded. HCV-RNA remains undetectable.

Discussion

We describe here the first case of SSc development in a patient treated with IFN for chronic viral hepatitis. Prior to the therapy onset, the patient did not have any suggestive symptom of an un-

derlying connective tissue disease, although ANA were positive 1:160 with speckled and nucleolar patterns. There was no family history, occupational or other drug history that might have placed her at risk for the development of SSc.

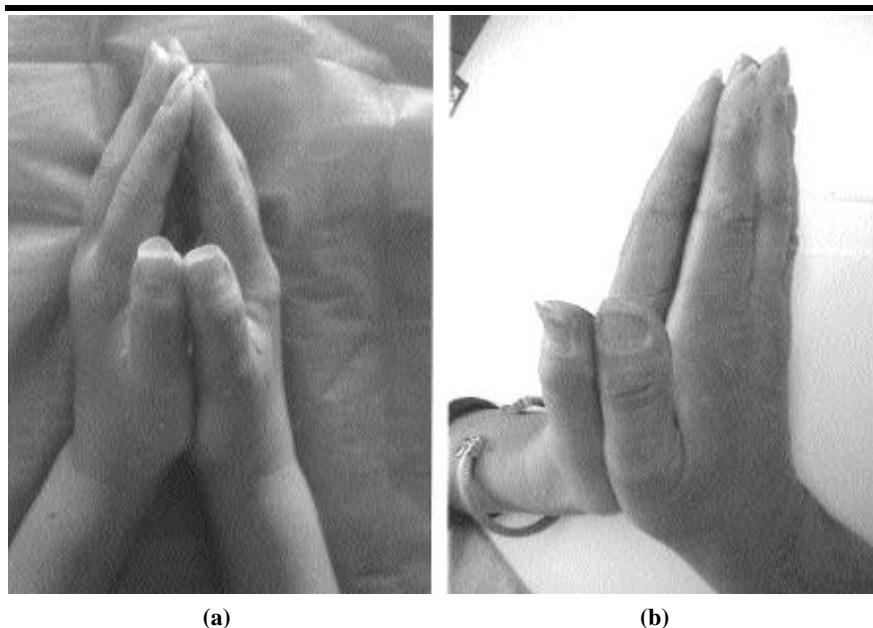


Fig. 1. Patient's hands showing finger edema and flexion contractures of interphalangeal joints (a) which appeared during IFN therapy, and clearly improved after drug withdrawal (b).

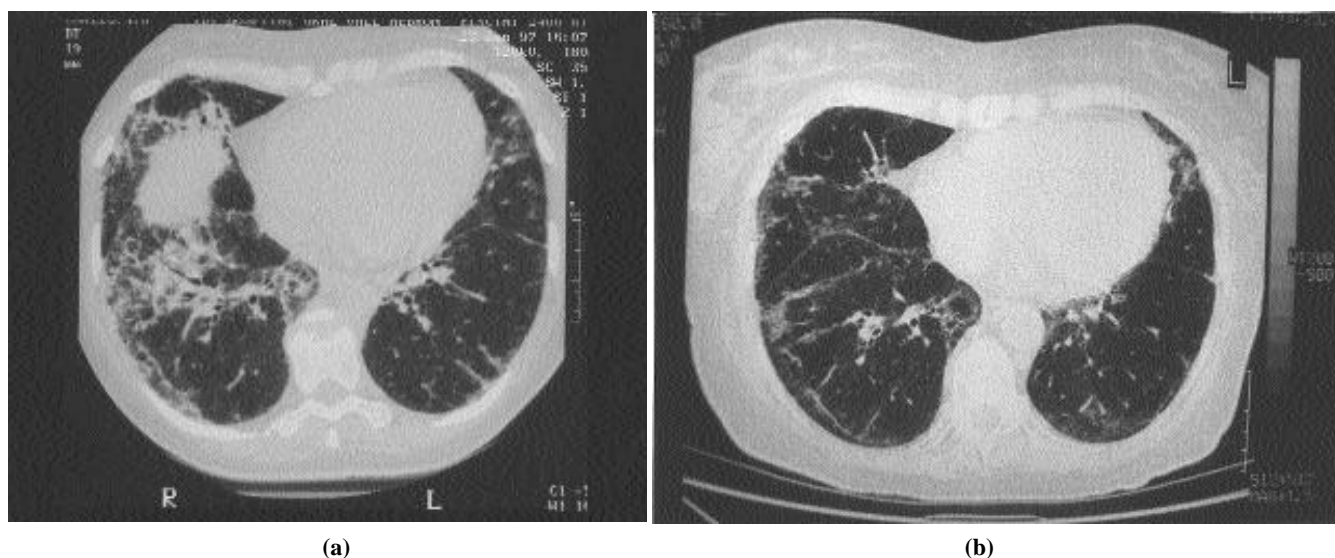


Fig. 2. A high-resolution chest CTscan showing extensive bi-basal pulmonary fibrosis with patchy areas of ground glass attenuation (a) which appeared during IFN therapy and clearly improved after drug withdrawal (b).

The first question in the present case is whether or not the development of SSc was an HCV-related autoimmune disease or was related to IFN therapy.

A high prevalence of serological markers of autoimmunity has been reported in patients with chronic HCV infection (5). Indeed, 60% to 70% of them show positive rheumatoid factor and 10% to 30% low titers of ANA (5, 6). In addition, up to 10% to 20% develop autoimmune disorders, the most frequent being autoimmune hepatitis and thyroiditis, mixed cryoglobulinemia, Sjögren syndrome, rheumatoid arthritis and systemic lupus erythematosus (SLE) (6). However, Raynaud's phenomenon has only been described in HVC patients with associated mixed cryoglobulinemia (6). There are no data showing that scleroderma-related antibodies may be induced by HCV infection, and only one patient with HCV chronic infection who developed SSc has been observed (7).

In contrast, Raynaud's phenomenon has been widely described after therapy with IFN in patients with positive ANA and no cryoglobulins, as in our case, and usually the symptoms receded when therapy was discontinued (8, 9). In addition, the *de novo* development or exacerbation of pre-existing autoimmune systemic diseases such as SLE, polymyositis, Sjögren syndrome and vasculitis, has been well documen-

ted after treatment with IFN (3-5, 10). Moreover, SSc development has recently been described in a patient treated with IFN for chronic myelogenous leukemia (11). As in our case, the reported patient developed a limited form of SSc with diffuse pulmonary interstitial fibrosis that improved after cessation of IFN therapy and treatment with steroids and cyclophosphamide. Capillaroscopy findings were similar to those described here. The patient had a major histocompatibility complex class II antigen that has been associated with SSc development (HLA-DR11). The authors suggested that this fact might have facilitated the triggering of autoimmunity by IFN.

In our case, the temporal relationship between the development of SSc and the institution of IFN therapy, the prompt improvement in the disease after cessation of the drug, and the absence of associated mixed cryoglobulinemia and detectable HCV-RNA at the time SSc occurred, made more likely an association of SSc with IFN therapy than an association with HCV infection. In our opinion, IFN therapy acted as a provoking agent and promoted the development of an underlying quiet autoimmune disease. In line with this, the *de novo* development of SSc has also been reported in association with other drugs such as bleomycin, docetaxel and other chemotherapeutic

drugs (12,13). In all of these cases, the disease usually improved or reversed with discontinuation of the precipitating drug and the administration of steroids. The development of SSc in association with IFN therapy could seem contradictory because IFN has been shown to inhibit collagen synthesis and has been used to treat patients with SSc. However, Black *et al.* (14) pointed out that IFN therapy might be deleterious in SSc patients, exacerbating life-threatening symptoms and precipitating lung deterioration through the up-regulation of intercellular type I adhesion molecules (ICAM-1), a fibroblast adhesion molecule that is overexpressed on SSc fibroblasts and is believed to be important in mediating lymphocyte-fibroblast interactions.

Unfortunately, the mechanism by which IFN may induce or exacerbate autoimmune-mediated complications is not known, as well as the reason why only some patients develop autoimmune disorders following this therapy (2-4). It has been suggested that IFN may promote the production of pathogenic antibodies, the up-regulation of HLA class I and II antigens and of ICAM-1, and the activation of macrophages (2-4). Similarly, it has been suggested that the presence of pre-existing antibodies or the appearance of antibodies during the treatment may be a risk factor for the development of an overt autoim-

mune disorder (3,10,15). In our case, the patient had antinuclear antibodies 1:160 with speckled and nucleolar patterns in 1995, before starting IFN therapy. When she developed symptoms suggestive of SSc, those antibodies were tested for specificities and corresponded to the nucleolar and nucleoplasmic antigen PM-Scl, a characteristic serologic feature of SSc that usually identifies a subset of patients with Raynaud's phenomenon, lung restriction, calcinosis and sicca syndrome. Thus, our patient probably had a subclinical autoimmune process that was unmasked by IFN therapy.

In conclusion, we describe the second case of systemic sclerosis development in a patient receiving IFN therapy. Although there may be a number of confounding issues, the close temporal relationship and the unusual clinical progression imply a drug effect. We recommend careful monitoring for signs and symptoms of autoimmunity in patients treated with IFN, especially if pre-existing autoantibodies or autoimmune diseases are present. Further stu-

dies are needed to ascertain the exact role of IFN therapy in the emergence or exacerbation of autoimmune diseases.

References

- LAUER GM, WALKER BD: Medical progress: Hepatitis C virus infection. *N Engl J Med* 2001; 345: 41-52.
- OKANOUE T, SAKAMOTO S, ITOH Y *et al.*: Side effects of high-dose interferon therapy for chronic hepatitis C. *J Hepatology* 1996; 25: 283-91.
- CONLON KC, URBAWJ, SMITH J, STEIS RG, LENGU DL, CLARK JW: Exacerbation of symptoms of autoimmune disease in patients receiving alpha-interferon therapy. *Cancer* 1990; 65: 2237-42.
- IOANNOU Y, ISENBERG DA: Current evidence for the induction of autoimmune rheumatic manifestations by cytokine therapy. *Arthritis Rheum* 2000; 43: 1431-42.
- CLIFFORD BD, DONAHUE D, SMITH L *et al.*: High prevalence of serological markers of autoimmunity in patients with chronic hepatitis C. *Hepatology* 1995; 21: 613-9.
- CACOUB P, POYNARD TH, GHILLANI P *et al.*: Extrahepatic manifestations of chronic hepatitis. *Arthritis Rheum* 1999; 42: 2204-12.
- ABU-SHAKRA M, SUKENIK S, BUSKILA D: Systemic sclerosis: another rheumatic disease associated with hepatitis C virus infection. *Clin Rheumatol* 2000; 19: 378-80.
- BACHMEYER C, FARGE D, GLUCKMAN E, MICLEA JM, ARACTINGI S: Raynaud's phenomenon and digital necrosis induced by interferon-alpha. *Br J Dermatol* 1996; 135: 481-3.
- CREUTZIG A, FREUND M: Severe Raynaud's syndrome associated with interferon therapy. *Angiology* 1996; 47: 185-7.
- REINHOLD-KELLER E, LAMPRECHT P, FELLNER AC, GROSS WL: Polyarthritits following interferon alpha treatment in a patient with localized Wegener's granulomatosis. *Clin Exp Rheumatol* 2001; 19: 227-8.
- BERETTA L, CARONNI M, VANOLI M, SCORZA R: Systemic sclerosis development after interferon-alfa therapy for myeloproliferative disorders. *B J Dermatol* 2002; 147: 385-410.
- HASSETG, HARNETT P, MANOLIOS N: Scleroderma in association with the use of docetaxel (taxotere) for breast cancer. *Clin Exp Rheumatol* 2001; 19: 197-200.
- EMIR S, KUTLUK T, TOPALOGLU, BAKKALOGLU A, BÜYÜKPAMUKÇU: Scleroderma in a child after chemotherapy for cancer. *Clin Exp Rheum* 2001; 19: 221-3.
- BLACK CM, SILMAN AJ, HERRICK AI *et al.*: Interferon- does not improve outcome at one year in patients with diffuse cutaneous scleroderma. *Arthritis Rheum* 1999; 42: 299-305.
- BELL TM, BANSAL AS, SHORTHOUSE C, SANDFORD N, POWELL EE: Low-titer autoantibodies predict autoimmune disease during interferon-alpha treatment of chronic hepatitis C. *J Gastroenterol Hepatol* 1999; 14: 419-22.