

## Successful treatment of relapsing polychondritis with infliximab

C. Richez, C. Dumoulin,  
X. Coutouly<sup>1</sup>, T. Schaefferbeke

Service de Rhumatologie, Groupe Hospitalier Pellegrin, CHU de Bordeaux, Bordeaux; <sup>1</sup>Département de Radiologie, Hôpital Trousseau, CHU de Tours, Tours, France.

Christophe Richez, MD; Chantal Dumoulin, MD; Xavier Coutouly, MD; Thierry Schaefferbeke, MD, PhD.

Please address correspondence and reprint requests to: Christophe Richez, Service de Rhumatologie, Hôpital Pellegrin, 6 Place Amélie Raba Léon, 33076 Bordeaux Cedex, France.

E-mail: christophe.richez@club-internet.fr

Received on February 4, 2004; accepted in revised form on June 9, 2004.

© Copyright CLINICAL AND EXPERIMENTAL RHEUMATOLOGY 2004.

**Key words:** Relapsing polychondritis, deafness, Cogan's syndrome, infliximab.

### ABSTRACT

*Relapsing polychondritis (RP) is a rare and potentially fatal autoimmune disease in which an inappropriate immune response destroys the cartilage of the ears, larynx and nose. Many therapeutic approaches have been reported. We describe the results obtained with infliximab in a patient with RP unresponsive to conventional therapy. This therapy could be a new weapon to treat refractory RP.*

### Introduction

Relapsing polychondritis (RP) is a rare and potentially fatal autoimmune disease in which an inappropriate immune response destroys the cartilage of the ears, larynx and nose (1). Conventional treatment, based on non-specific immunosuppressive and symptomatic agents, is unable to control acute flares in all patients. Anti-TNF alpha has been demonstrated to be effective in refractory rheumatoid arthritis and Crohn's disease, and its use is being extended to other inflammatory disorders (2). While the etiology of RP remains unknown, there is some evidence that the cartilage is the central target of the disease. RP chondritis is related to an infiltration of the cartilaginous structures by mononuclear cells (3). Autoantibodies characteristic of RP are directed against type II, type IX and type XI collagen (1), which are normal constituents of cartilage. Production of Th1 cytokines by T-cell clones reactive to type II collagen has been identified in one patient but this production was dependent on the DRB1 restriction element used (4). Interestingly, TNF- $\alpha$  has also been implicated in inner ear inflammation in an animal model (5). Thus, it seems that RP corresponds to a humoral and cellular auto-immune reaction to the epitopes of cartilage collagen, probably occurring in genetically conditioned patients, the inflammatory process involving Th1 cytokines including TNF- $\alpha$ . This gave us the rationale to treat a patient suffering from refractory RP with an anti-TNF- $\alpha$  agent.

### Case report

A 41-year-old white man was admitted

to our hospital in October 2001 for acute joint pain in a context of vasculitis of unknown etiology. He had been affected by deafness of the right ear since February 2001, which was at this time considered idiopathic, and had been treated unsuccessfully with hemodilution and hyperbaric oxygen therapy. In May 2001, he presented first with palmoplantar pain, oral aphthosis, and a skin rash of the trunk and upper limbs consisting of erythematous and papulo-necrotic lesions. The skin biopsy suggested a leucocytoclastic vasculitis. A few weeks later, the patient complained of dyspnea and thoracic pain. Laboratory findings revealed an increased erythrocyte sedimentation rate (ESR 54 mm/hour), C-reactive protein level (CRP 110 mg/l) and white blood cell count (WBC 11,200/ml), but showed neither antinuclear antibodies (ANA), anti-double-stranded DNA antibodies (anti-dsDNA), extractable nuclear antigen (ENA), nor antineutrophil cytoplasmic antibodies (ANCA). An echocardiography and a thoracic computerized tomography (CT) scan revealed myocarditis and a posterior pleural effusion. It was then concluded to be an undifferentiated systemic vasculitis syndrome, and the patient was given prednisone 1 mg/kg/d for one month, then 30 mg/d.

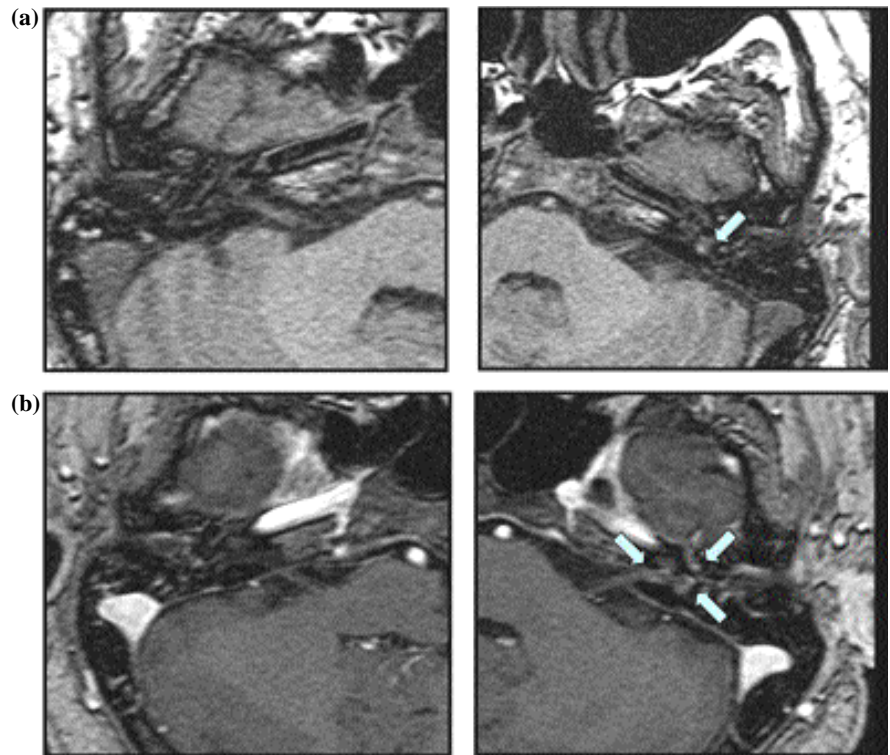
In October 2001, he complained of dyspnea, asthenia, night sweats, rachialgia and knee arthralgia, and the skin vasculitis persisted despite the corticosteroid therapy. Laboratory results revealed only elevated ESR (60 mm/hour) and CRP (140 mg/l) levels. Various serological tests were negative, as were systematic blood, urine and gastric liquid cultures performed to detect viral, pyogenic and tuberculous infections. Chest radiography and magnetic resonance imaging (MRI) of the whole spine, performed in the hypothesis of spinal infection, were normal. Thoraco-abdominal CT scan showed a slight pleurorrhea, but no adenopathy that could have suggested a lymphoma. Echocardiography showed no endocarditis, myocarditis or pericarditis. As the diagnosis was not determined, no immunosuppressive treatment was initiated. The prednisone was slightly

increased (1 mg/kg/d), then gradually tapered after an improvement.

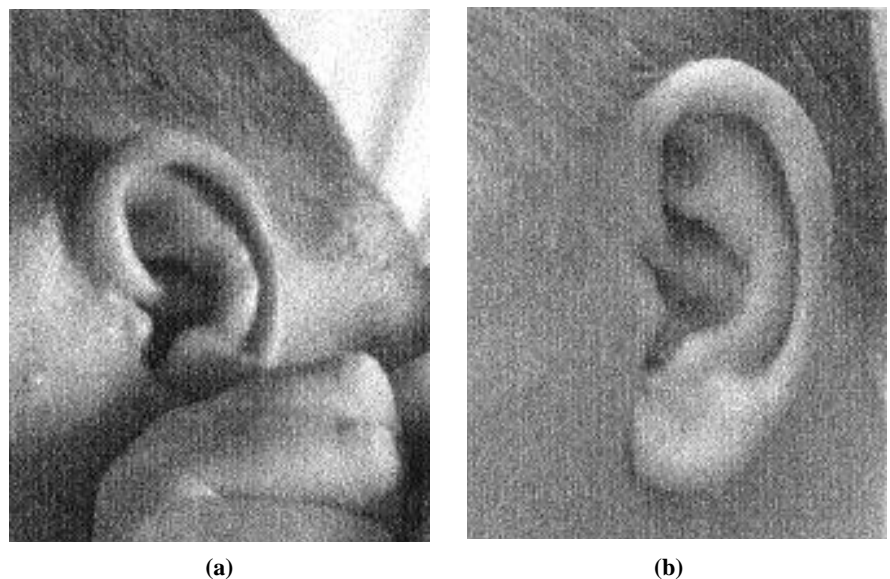
In May 2002, methotrexate therapy (up to 15 mg/week) was added to the prednisone (30 mg/d) for a new flare-up of dyspnea, rash and a first episode of episcleritis. At this time, anti-collagen type 2 antibodies, performed because of a saddle nose deformity, were negative.

In July 2002, the episcleritis relapsed in association with progressive deafness. ESR and CRP were still elevated (46 mm/h and 54.6 mg/l respectively). Inner ear magnetic resonance imaging visualized cochlear inflammation (Fig. 1) and an audiogram showed sensorineural hearing loss. In view of these findings, Cogan's syndrome was considered. Methotrexate therapy was withdrawn and replaced by infusions of cyclophosphamide 1 g/month and methylprednisolone 200 mg/day for 5 days, then prednisone 60 mg/day. Two weeks later, the patient developed auricular chondritis and vestibular dysfunction. In view of the auricular chondritis, the nasal chondritis, the ocular inflammation and the audiovestibular damage, we diagnosed an acute phase of RP on the basis of the criteria of Michet *et al.* (6) and McAdam *et al.* (7). Biological investigations showed the appearance of anti-collagen type 2 antibodies. Wegener and polyarteritis nodosa were also discussed, but the patient presented neither renal, pulmonary, peripheral neurologic damage, nor ANCA. Finally, an isolated Cogan's syndrome could not account for the cartilage involvement.

Since a) cyclophosphamide and corticosteroid therapy did not prevent the most recent flare-up of the disease, b) the laryngotracheal and bronchial cartilages might have been involved, and c) TNF-alpha is known to be implicated in the pathophysiology of RP, an infusion of infliximab (5 mg/kg of body weight) was administered. All clinical symptoms [chondritis (Fig. 2), episcleritis, skin rash and dyspnea] dramatically remitted in four days, while the inflammatory parameters normalized (ESR 11 mm/hour and CRP 9 mg/l). Only the vestibular dysfunction and ear deafness persisted. Infliximab infusions were repeated at week 2, week 6,



**Fig. 1.** (a) Unenhanced axial gradient-echo T1-weighted MR image of the left membranous labyrinth showing high signal, interpreted as spontaneous micro-hemorrhage in cochlea and vestibule; (b) enhanced axial gradient-echo T1-weighted MR image showing three foci of enhancement located in the cochlea, vestibule and internal auditory meatus of the left ear.



**Fig. 2.** Clinical aspect of the ear before (A) and four days after (B) the first infusion of infliximab.

then every 8 weeks. Ten days before the fifth infusion, the episcleritis recurred, so the interval between the following infusions was reduced to 6 weeks. There was no subsequent recurrence of episcleritis, so the corticosteroid dosage was substantially lowered (10 mg/day). No new flare-up of RP was ob-

served during one-year of follow up. Laboratory evaluations were performed each month and revealed no elevation of inflammatory parameters. Chest radiography remained normal. As the patient did not develop any symptoms such as night sweats, asthenia or dyspnea, no subsequent CT scan was per-

formed. One year after beginning infliximab therapy, a new MRI of the inner ear showed that the cochlear inflammation had disappeared. To treat the patient's deafness, a cochlear device was inserted and rehabilitation was started.

### Discussion

Thus, in this patient, infliximab clearly improved the clinical manifestations, the biological inflammatory syndrome and MRI findings, and led to a substantial reduction of the corticosteroid therapy. Furthermore, the dramatic efficacy of infliximab allowed cochlear implantation, which is known to be effective in immune-mediated inner ear disorders (8). In the last few months, four case reports have emphasized the potential interest of anti-TNF-alpha treatment in RP (9, 10). As it is impossible to perform clinical trials in an uncom-

mon disorder such as RP, single case reports giving concordant results are of interest for physicians. All cases reported to date suggest that anti-TNF-alpha agents are efficient in the treatment of RP.

### References

1. LETKO E, ZAFIRAKIS P, BALTATZIS S, VOUDOURI A, LIVIR-RALLATOS C, FOSTER CS: Relapsing polychondritis: A clinical review. *Semin Arthritis Rheum* 2002; 31: 384-95.
2. STOKES DG, KREMER JM: Potential of tumor necrosis factor neutralization strategies in rheumatologic disorders other than rheumatoid arthritis. *Semin Arthritis Rheum* 2003; 33: 1-18.
3. VALANZUELA R, COOPERRIDER PA, GOGATE P, DEODHAR SD, BERGFELD WF: Relapsing polychondritis: Immunomicroscopic findings in cartilage of ear biopsy specimens. *Hum Pathol* 1980; 11: 19-22.
4. BUCKNER JH, VAN LANDEGHEN M, KWOK WW, TSARKNARIDIS L: Identification of type II collagen peptide 261-273 specific T cell clones in a patient with relapsing polychondritis. *Arthritis Rheum* 2002; 46: 238-44.
5. SATOH H, FIRESTEIN GS, BILLINGS PB, HARRIS JP, KEITHLEY EM: Tumor necrosis factor- $\alpha$ , an initiator, and etanercept, an inhibitor of cochlear inflammation: *Laryngoscope* 2002; 112: 1627-34.
6. MICHEC CJ, MCKENNA CH, LUTHRA HS, O'FALLON WM: Relapsing polychondritis: Survival and predictive role of early disease manifestations. *Ann Intern Med* 1986; 104: 74-8.
7. MCADAM LP, O'HANLAN MA, BLUESTONE R, PEARSON CM: Relapsing polychondritis: prospective study of 23 patients and a review of the literature. *Medicine* 1976; 55: 193-215.
8. QUARANTA N, BARTOLI R, GIAGNOTTI F, DI CUONZO F, QUARANTA A: Cochlear implants in systemic autoimmune vasculitis syndromes. *Acta Otolaryngol* 2002; 548 (Suppl.): 44-8.
9. SAADOUN D, JOB DESLANDRE C, ALLANORE Y, CHARLIER C, PHAM X-V, KAHAN A: Sustained response to infliximab in 2 patients with refractory relapsing polychondritis. *J Rheumatol* 2003; 30: 1394-5.
10. MPOFU S, ESTRACH C, CURTIS J, MOOTS RJ: Treatment of respiratory complications in recalcitrant relapsing polychondritis with infliximab. *Rheumatology (Oxford)* 2003; 42: 1117-8.