

Erratum corrigé

Cardiac involvement in newly diagnosed patients with idiopathic inflammatory myopathies is associated with skeletal muscle involvement

B. Hanna, C.L. Polte, E. Sakiniene, J. von Brömsen, E. Bollano, I.E. Lundberg, R. Pullerits, T. Jin

Published in: *Clin Exp Rheumatol* 2026; 44(2): 320-329.

The authors have brought to our attention that the image labelled **Fig. 2** was erroneously inserted. The correct version of Figure 2 is the following:

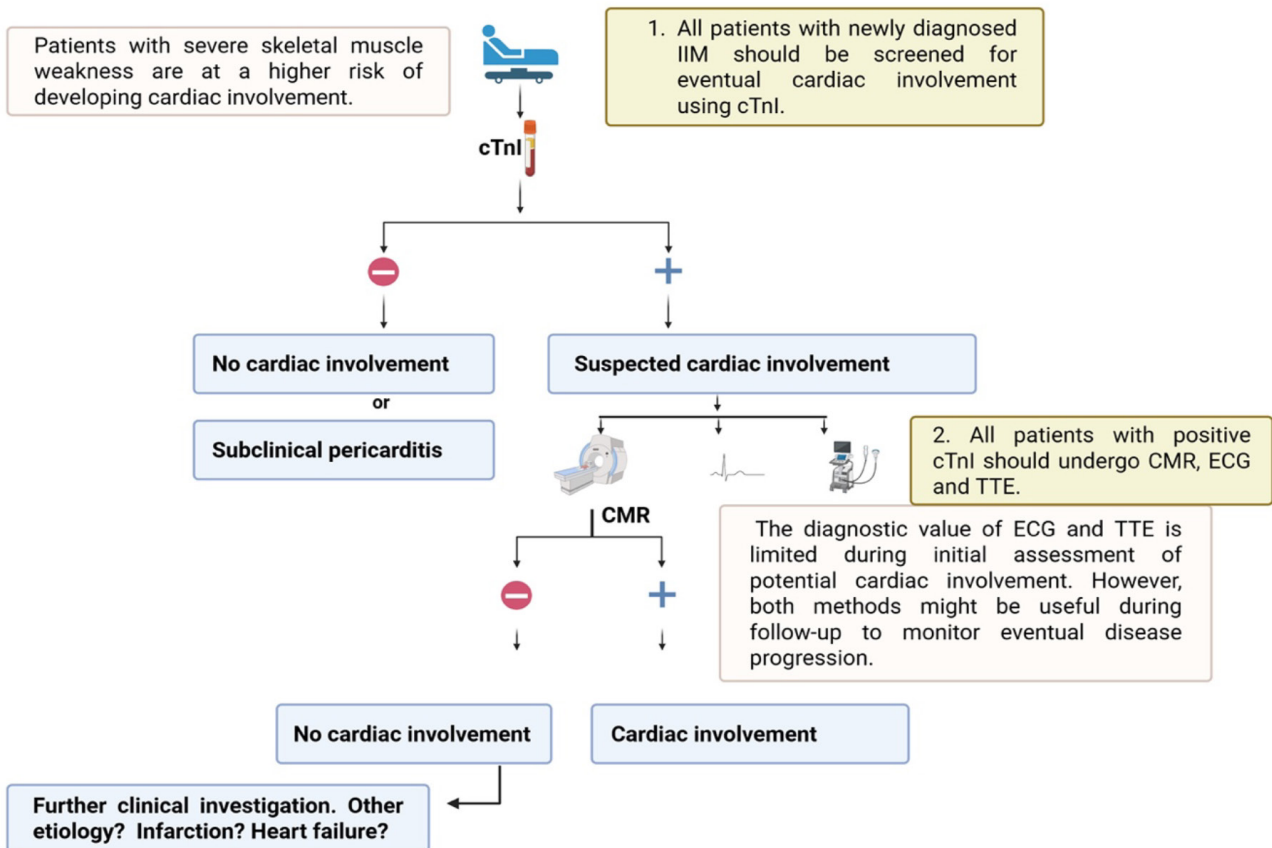


Fig. 2. Proposed diagnostic algorithm for early detection of cardiac involvement at the onset of idiopathic inflammatory myopathies. CMR: cardiac magnetic resonance; ECG: electrocardiography; IIM: idiopathic inflammatory myositis; TTE: transthoracic echocardiography.