

Case report

A pipefitter's aching muscles: Clinical vignette

E. Yacyshyn¹, D.J. Emery², E.L. Matteson³

¹Rheumatology Associates, Edmonton, Alberta; Department of Radiology and Diagnostic Imaging, University of Alberta, Edmonton, Alberta, Canada; Mayo Clinic College of Medicine, Rochester, Minnesota, USA.

Elaine A. Yacyshyn, M.D.; Derek J. Emery, M.D.; Eric L. Matteson, M.D., M.P.H.

Please address correspondence to:
Eric L. Matteson, MD, MPH, Division
of Rheumatology, Mayo Clinic, 200 1st St.
SW, Rochester, MN 55905, USA.
E-mail: matteson.eric@mayo.edu

Received on May 24, 2004; accepted in
revised form on September 17, 2004.

Clin Exp Rheumatol 2004; 22 (Suppl. 36):
S65-S69.

© Copyright CLINICAL AND EXPERIMENTAL
RHEUMATOLOGY 2004.

Key words: Vasculitis, Wegener's
granulomatosis, myopathy.

Case presentation

A 52-year-old man was admitted to hospital with a one-month history of marked significant musculoskeletal pain, weakness, dysaesthias, and gross hematuria.

One month prior to admission, he developed a sore throat and ear pain. Treatment for putative bacterial infection was initiated with trimethoprim and then azithromycin. He then went on an overseas trip with continued symptoms of ear pain and rhinitis. Antibiotic therapy was changed to amoxicillin clavulanate and acetylcysteine, even as a severe burning sensation of his feet and hand numbness developed. He was unable to walk due to the pain. Ear and nasal symptoms resolved, and he noticed blood in his urine on two or three occasions which had resolved by the time of presentation.

The patient was married and worked as a pipefitter. He had a history of alopecia areata and suffered a cerebral thrombus

as a child. He was a non-smoker, and he enjoyed making and drinking home-made wine. His only medications prior to admission were the discontinued antibiotics and a nasal decongestant, used only intermittently over the years. He had no known allergies, and family history was unremarkable. He denied risk factors for infection with the human immunodeficiency or hepatitis viruses, or intravenous drug use.

On admission, the patient was afebrile. Pulse was 90 and regular. Respirations were 16/minute, and blood pressure was 110/50 mm Hg. He appeared unwell and had a faint facial flush. Examination of the head and neck was normal with no abnormalities of ear or mouth and no evidence of cervical adenopathy. The heart, lungs, and abdomen were normal. Periungual splinter hemorrhages were present on several fingers and toes. There was a vasculitic appearing rash with palpable purpura over the elbows, palms, and feet (Fig.

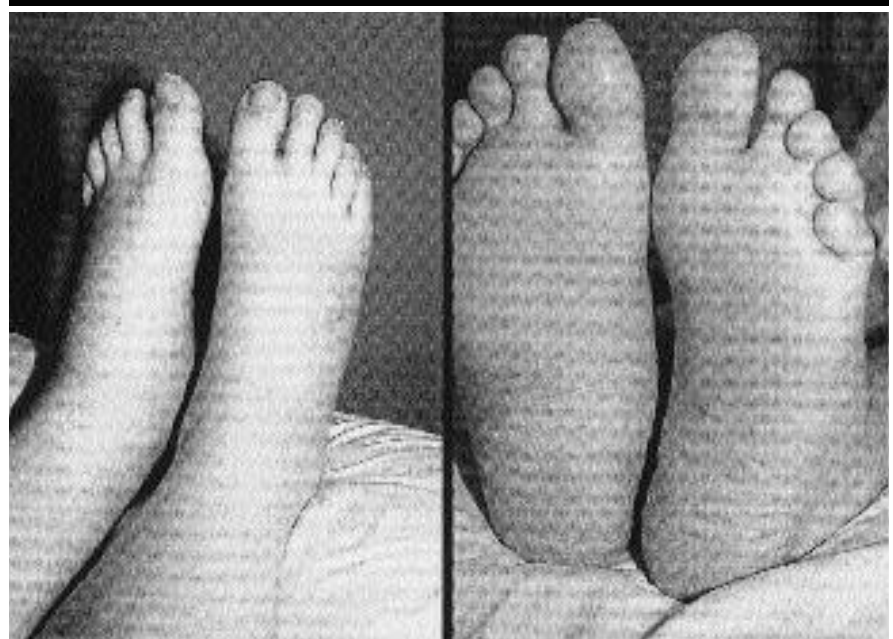


Fig. 1. Photograph of the patient's feet at admission with palpable purpura.

1). Gottron's papules and heliotrope rash were not present. Digital pressure applied to his extremities caused severe pain.

Neurologic evaluation showed evidence of marked weakness affecting the proximal more than distal muscles, with evidence of a polyneuropathy, documented on electromyography.

Laboratory tests revealed a markedly elevated serum creatinine kinase of 2,717 U/L (normal: 52-336 U/L) and on urinalysis, myoglobinuria (4609 µg/ml; normal < 0.025 µg/ml). Hemoglobin was 13.3 g/dL with 4% eosinophils, white-cell count was 16,100 per cubic millimeter, and the platelet count was 174,000 per cubic millimeter. The erythrocyte sedimentation rate (ESR) was elevated to 67 mm/H and C-reactive protein (C-RP) elevated to 240 mg/L. Values for urea nitrogen, creatinine, bilirubin, calcium, phosphorus, total protein, albumin, electrolytes and alkaline phosphatase were normal. Other negative or normal tests included an antinuclear antibody, complement C3 and C4, extractable nuclear antigen, glomerular basement membrane, rapid plasma reagin, serology for hepatitis B and C, blood cultures and admission electrocardiogram. Because renal function and urinalysis were normal, the nephrology consultant recommended against renal biopsy.

Biopsy of a skin lesion from the arm revealed changes of leukocytoclastic vasculitis.

Dr. Matteson: *At this point, the clinical picture was that of a likely vasculitis of indeterminate cause. An idiopathic inflammatory myopathy was considered in the differential diagnosis because of muscle pain and weakness. However, this patient had signs and symptoms more suggestive of a vasculitis of medium and small arteries, including otalgia, "sinusitis", palpable purpura, splinter hemorrhages, and a polyneuropathy. The muscle pain appears to have been significant, suggestive of myonecrosis, while in classic dermatomyositis, muscle pain can be, but usually is not, a dominant clinical feature of disease. Infectious etiologies including viral disease are unlikely with lack of*

fever or clear infectious agent exposure. Microscopic polyarteritis could also be considered. The renal function was apparently normal. The cause of the episode of macroscopic hematuria remained unexplained but should have been further investigated. Macroscopic hematuria is uncommon in vasculitis affecting the kidneys, but could be due to vasculitis of the bladder wall or rarely prostate involvement from Wegener's granulomatosis, or unrelated causes such as prostatitis or nephrolithiasis. The patient apparently did not have flank pain suggestive of kidney stone disease or renal vein thrombosis.

In the following days, further diagnostic tests were undertaken, including a serial creatine kinase, which returned to normal. Antineutrophil cytoplasmic antibody (ANCA) was obtained, revealing cytoplasmic staining. Antigen specific assays revealed antibodies to PR-3. A muscle biopsy revealed evidence of massive infarction (Fig. 2). At this point, the patient developed hemoptysis and respiratory distress and progression of the cutaneous lesions. Chest radiograph revealed bilateral pleural effusions and pulmonary edema. Sensorineural hearing loss also developed.

Clinical diagnosis

Wegener's granulomatosis

Dr. Matteson: *The diagnostic test highly suggestive of the diagnosis was the positive ANCA with antibody to PR-3. The sensitivity of ANCA recognizing the cytoplasm is about 90% in active Wegener's granulomatosis, and the specificity of these cytoplasm staining autoantibodies is about 90% (1). Although these ANCA are not 100% specific for the diagnosis of Wegener's granulomatosis, in the context of the typical clinical features of subacute sinusitis, otalgia, hemoptysis, palpable purpura, new onset sensorineural hearing loss, and polyneuropathy, the diagnosis of Wegener's granulomatosis is most likely (2,3). The initial impression of an idiopathic inflammatory myopathy (IMM) seemed supported by the symptoms of muscle pain and weakness, whereby muscle pain occurs only in a minority of such patients.*

On histopathologic evaluation, the muscle biopsy from the left quadriceps revealed resorbing massive infarction rather than endomysial or perimysial, perivascular inflammation more characteristic of IMM; the diagnosis of a vasculitis could not be resolved by the

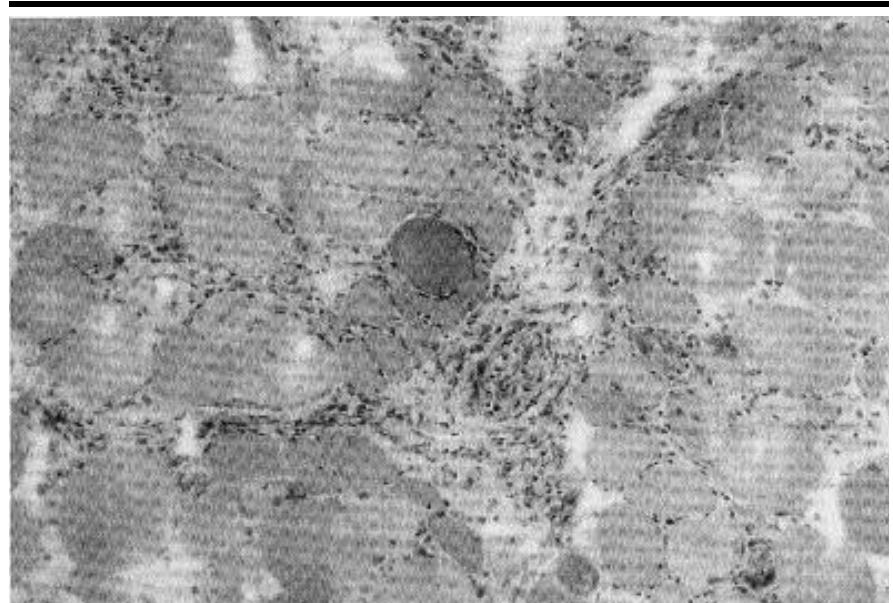


Fig. 2. Histopathology from a quadriceps biopsy revealing massive myonecrosis. There are aggregates of macrophages dispersed throughout the endomysium and actively phagocytosing the necrotic muscle fibers. Active arteritis or vasculitis is not seen, although there are some chronic inflammatory cells within a small perimysial artery. (Hematoxylin and eosin, medium power).

muscle biopsy. Arthralgias, arthritis, and myalgias are common manifestations of Wegener's granulomatosis, occurring in well over 50% of patients, however muscle necrosis from vasculitis is rarely reported (2-4). ANCA, especially c-ANCA, is rarely associated with idiopathic inflammatory myopathy, and so would add to the evidence against IIM as the diagnosis in this patient (5).

Treatment with intravenous "pulse" Solu-Medrol (1 gram/day for 3 consecutive days) was administered along with cyclophosphamide (1500 mg for one dose, weight-based at 0.7gm/m²) followed by oral prednisone (60 mg per day). Two weeks after this initial cyclophosphamide infusion he developed a persistent neutropenia, with a total WBC of 2,000 per cubic millimeter with an absolute neutrophil count of 0.3. He was afebrile; however due to concerns over the duration of the neutropenia, he was given granulocyte colony stimulating factor (G-CSF). This increased his WBC dramatically to 15,600 per cubic millimeter. Five days after the G-CSF administration, he developed a cyanotic left foot. An ultrasound of the left leg was normal, with borderline normal Doppler arterial studies. Spiking fevers to 40°C prompted treatment with tobramycin and ceftazidime because of concern about possible sepsis which was not sustained. Over the following week, the foot became more mottled. He was re-treated with intravenous Solu-Medrol, 1 gm/d for three further days.

Further imaging was completed to evaluate the ischemic leg. A magnetic resonance angiogram of the lower limbs revealed the large vessels to be patent from the distal aorta to the feet (Fig. 3). Shortly thereafter developing lower extremity ischemia, the patient suffered chest pain. A non-STelevation myocardial infarction with new left bundle branch block was diagnosed. He was admitted to the coronary care unit, and received anticoagulation. A subsequent coronary angiogram did not show evidence of a focal lesion, and an echocardiogram revealed normal cardiac function. The hemoglobin dropped to 8.2 g/dL, requiring transfusion of packed red

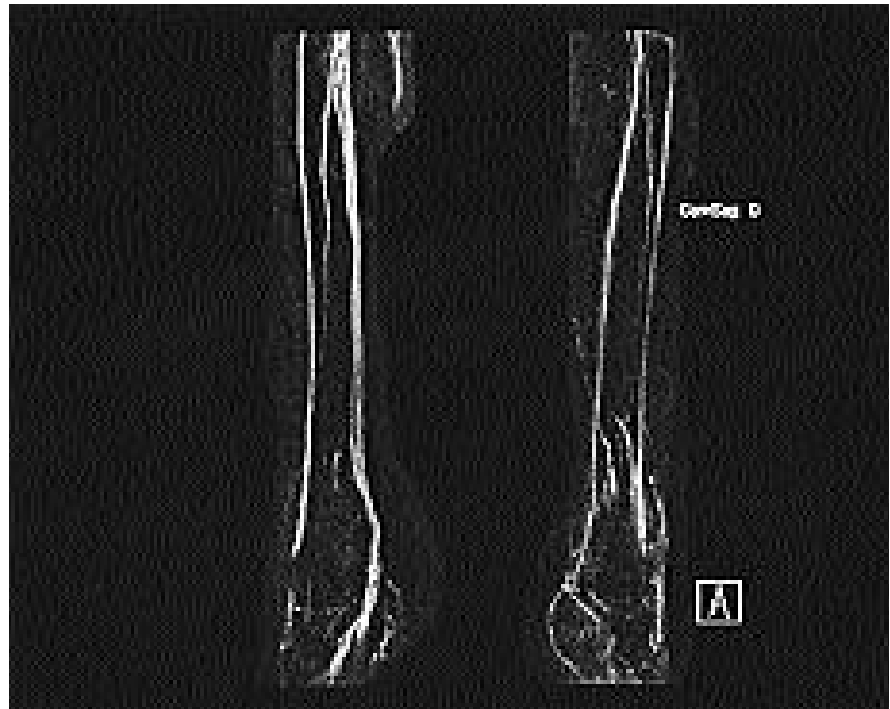

Fig. 3. Magnetic resonance angiogram demonstrating patent vessels in the distal lower limbs. The MRI/MRA of the proximal vessels was normal (not shown).

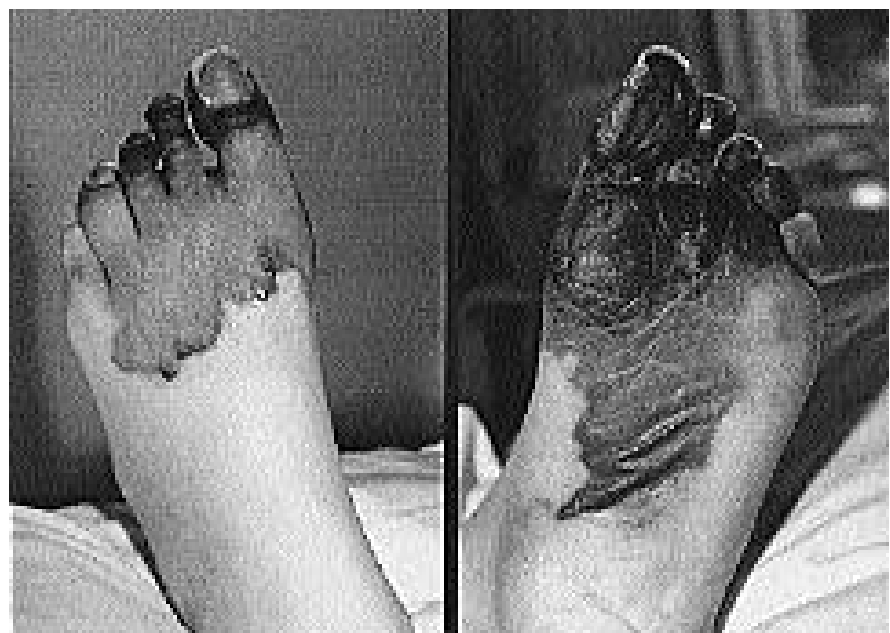

Fig. 4. Gangrene of the left foot due to vasculitic ischemia.

blood cells. Painful ischemia of the left foot evolved into dry gangrene (Fig. 4). A chemical sympathectomy was unsuccessful in providing additional pain control.

Discussion

Dr. Matteson. The disease course was one of severe systemic vasculitis (Weg-

ener's granulomatosis). As is frequently the case, diagnosis was delayed as initial therapy for putative upper respiratory tract infection was undertaken. The respiratory failure was thought due to alveolar hemorrhage rather than heart failure. The myocardial infarction was likely due to coronary artery vasculitis. Computerized tomography and possi-

bly bronchoscopy would have been helpful in the assessment of the respiratory failure. As in this case, respiratory involvement from alveolar hemorrhage usually responds well to high-dose corticosteroids and supportive measures. The myonecrosis and extremity gangrene reflected severe small and distal medium vessel disease, the latter in spite of the normal angiogram. The gangrene occurred after the GM-CSF administration, which was given for neutropenia. The indication for administration of this agent in a neutropenic patient without active infection is a matter of clinical judgment but has generally not been demonstrated to be of benefit in the uninfected patient (6). The causal relationship of the extremity ischemia to the GM-CSF is uncertain, but local necrotizing vasculitis has been described at injection site of GM-CSF, which was not the case in this patient (7).

Although conductive hearing loss is perhaps more common in Wegener's granulomatosis, the sensorineural hearing loss in this patient may well have been a manifestation of the underlying disease. A computerized tomography study of the head and sinuses would have served to clarify the extent of cranial and orofacial maxillary involvement.

Subsequent disease course

Because of persistent extremity weakness, a follow-up EMG was performed which showed evidence of a severe motor and sensory axonal polyneuropathy, with deterioration since the prior study.

Two months after initial admission, a left below knee amputation was performed. Intravenous (IV) "pulse" cyclophosphamide was continued every three weeks with careful attention to blood counts at a reduced dose of 800-900 mg/dose. He was discharged from the active treatment hospital to a rehabilitation facility. Renal function was normal, respiratory status satisfactory, and the skin lesions had resolved. The ESR and C-RP were normal. Discharge medications included: pulse cyclophosphamide, prednisone, etidronate, gabapentin, morphine, insulin, ceftazidime, ramipril, aspirin, 325 mg per day, iron,

trimethoprim sulfamethoxazole, and omeprazole.

Cyclophosphamide therapy was discontinued after 6 months, and methotrexate, 20 mg per week, initiated. One month thereafter, he had a recurrence of skin lesions, and developed severe abdominal pain determined to be due to cholelithiasis requiring hospitalization. This pain resolved spontaneously after a few days. At this point, the ESR was elevated to 25 mm/Hr. The prednisone dose was increased from 20 mg/day to 30 mg/day. Methotrexate was discontinued and daily oral cyclophosphamide initiated at 100 mg po/day. The vasculitic skin rash worsened, and pulse cyclophosphamide every 3 weeks was restarted, with increase in prednisone to 40 mg/day.

He has had side-effects with on-going steroid use, including steroid-induced diabetes mellitus, insufficiency right fibular fracture, Cushingoid features, and osteoporosis. The prednisone dose was slowly reduced to 15mg/day, when recurrence of hemoptysis occurred, requiring increase in the oral prednisone dose.

A transurethral prostatectomy (TURP) has since been performed for obstructive urinary symptoms. His post-operative course was complicated by a right leg deep venous thrombosis (DVT), requiring anti-coagulation, and re-hospitalization for hematuria without evidence of hemorrhagic cystitis, as well as marked anemia. Renal function remained normal, and the hematuria resolved. Follow-up urine cytology examinations and cystoscopy have been negative/normal. He remains on IV pulse cyclophosphamide and oral prednisone, aware of the risks of ongoing cyclophosphamide use including serious infections, malignancies, and hemorrhagic cystitis.

Dr. Matteson: Aggressive treatment including i.v. cyclophosphamide is warranted in patients with severe vasculitis and parenchymal involvement as this patient had (8-10). The Five Factor Score (FFS), used in prognostic assessment of vasculitides such as Wegener's granulomatosis, could be rated 0, as although the patient had a coro-

nary infarction and might be regarded therefore as having a cardiomyopathy, there was no evidence of heart failure on the examinations performed.

The FFS is based on 5 clinical items, with the presence of each given one point; 2 or more factors are given a score of 2: renal insufficiency (serum creatinine >1.58 mg/dl; proteinuria > 1 m/day; central nervous system involvement; cardiomyopathy; severe gastrointestinal involvement. An FFS of 1 portends increased risk of pre-renal mortality (RR 1.35); a FFS of 2 carries a RR of 2.40 (11).

Although in this patient due to side effects of anticoagulation following the TURP, hematuria in the setting of cyclophosphamide therapy is worrisome for hemorrhagic cystitis as well as subsequent development of bladder cancer, a complication of cyclophosphamide treatment in 5% of patients at 10 years and 16% at 15 years (12). DVT is emerging as a disease related complication of Wegener's granulomatosis as well.

This patient had severe vasculitic involvement, warranting aggressive treatment. He suffered severe and disabling complications of pulmonary disease and limb infarction necessitating amputation of the leg, which do not appear on the Five Factor Score but which nevertheless are associated with profound morbidity. He also developed a deep venous thrombosis post-operatively, which may be a perioperative complication, although recently it has been reported that patients with Wegener's granulomatosis may be at increased risk for this complication due to the underlying disease itself (13).

It remains unresolved whether i.v. or oral cyclophosphamide is superior for disease management or maintenance of remission. Randomized studies of intravenous pulse cyclophosphamide therapy versus daily oral cyclophosphamide for active Wegener's suggest that the two approaches have similar efficacy with respect to patient survival, remission rate, time to remission, relapse rate, and outcome of renal function. I.v. administration appears to be associated with lower rates of leukopenia, severe infections, and gonadal

toxicity (9).

With protracted treatment, and after the disease has been brought under control, the withdrawal of cyclophosphamide and the substitution of other agents with generally less toxicity such as azathioprine does not increase the rate of relapse (9,14). In this patient, with poor long-term disease control and multiple steroid treatment related complications, consideration could be given to other treatment modalities. These include initial plasmapheresis and at this point, perhaps use of the anti-B cell therapeutic rituximab, which may be emerging as an effective therapy for severe Wegener's granulomatosis (15). Anti-TNF therapies are under evaluation for management of severe, active Wegener's granulomatosis, but are of uncertain benefit, as is mycophenolate mofetil, although the latter may be helpful as a cyclophosphamide and steroid sparing therapy once the disease is brought under control (16, 17).

Clinical diagnosis

Wegener's granulomatosis.

References

1. KALLENBERG CG, MULDER AH, TERVAERT JW: Antineutrophil cytoplasmic antibodies: a still-growing class of autoantibodies in

inflammatory disorders [see comment]. *Am J Med* 1992; 93: 675-82.

2. LANGFORD CA: Wegener granulomatosis. *Am J Med Sci* 2001; 321: 76-82.

3. HOFFMAN GS, KERR GS, LEAVITT RY *et al.*: Wegener granulomatosis: an analysis of 158 patients. *Ann Intern Med* 1992; 116: 4884-98.

4. NORITAKE DT, WEINER SR, BASSETT LW, PAULUS HE, WEISBART R: Rheumatic manifestations of Wegener's granulomatosis. *J Rheumatol* 1987; 14: 949-51.

5. MERKEL PA, POLISSON RP, CHANG Y, SKATES SJ, NILES JL: Prevalence of antineutrophil cytoplasmic antibodies in a large inception cohort of patients with connective tissue disease. *Ann Intern Med* 1997; 126: 866-73.

6. HARTMANN LC, TSCHETTER LK, HABERMANN TM *et al.*: Granulocyte colony-stimulating factor in severe chemotherapy-induced afebrile neutropenia. *N Engl J Med* 1997; 336: 1776-80.

7. FARMER KL, KURZROCK R, GUTTERMAN JU, DUVIC M: Necrotizing vasculitis at granulocyte-macrophage-colony-stimulating factor injection sites. *Arch Dermatol* 1990; 126: 1243-4.

8. GUILLEVIN L, CORDIER JF, LHOTE F *et al.*: A prospective, multicenter, randomized trial comparing steroids and pulse cyclophosphamide versus steroids and oral cyclophosphamide in the treatment of generalized Wegener's granulomatosis. *Arthritis Rheum* 1997; 40: 2187-98.

9. HAUBITZ M, SCHELLONG S, GOBEL U *et al.*: Intravenous pulse administration of cyclophosphamide versus daily oral treatment in patients with antineutrophil cytoplasmic antibody-associated vasculitis and renal involvement: a prospective, randomized study.

Arthritis Rheum 1998; 41: 1835-44.

10. KOLDINGSNES W, GRAN JT, OMDAL R, HUSBY G: Wegener's granulomatosis: long-term follow-up of patients treated with pulse cyclophosphamide. *Br J Rheumatol* 1998; 37: 659-64.

11. GUILLEVIN L, LHOTE F, GAYRAUD M *et al.*: Prognostic factors in polyarteritis nodosa and Churg-Strauss syndrome. A prospective study in 342 patients. *Medicine* (Baltimore) 1996; 75: 17-28.

12. TALAR-WILLIAMS C, HIJAZI YM, WALTHER MM *et al.*: Cyclophosphamide-induced cystitis and bladder cancer in patients with Wegener granulomatosis. *Ann Intern Med* 1996; 124: 477-84.

13. MERKEL PA, LO GH, HOLBROOK JT *et al.*: High incidence of venous thrombotic events among patients with Wegener's granulomatosis. *Arthritis Rheum* 2003; 48: S660.

14. JAYNE D, RASMUSSEN N, ANDRASSY K *et al.* and the EUROPEAN VASCULITIS STUDY GROUP: A randomized trial of maintenance therapy for vasculitis associated with antineutrophil cytoplasmic autoantibodies. *N Engl J Med* 2003; 349: 36-44.

15. LAMPRECHT P, VOSWINKEL J, LILIENTHAL T *et al.*: Effectiveness of TNF-alpha blockade with infliximab in refractory Wegener's granulomatosis. *Rheumatol* 2002; 41: 1303-7.

16. LANGFORD CA, TALAR-WILLIAMS C, SNELLER MC: Mycophenolate mofetil for remission maintenance in the treatment of Wegener's granulomatosis. *Arthritis Rheum* 2004; 51: 278-83.

17. SPECKS U, FERVENZA FC, McDONALD TJ, HOGAN MC: Response of Wegener's granulomatosis to anti-CD20 chimeric monoclonal antibody therapy. *Arthritis Rheum* 2001; 44: 2836-40.