

Development of new osteonecrosis in systemic lupus erythematosus patients in association with long-term corticosteroid therapy after disease recurrence

J. Nakamura^{1,2}, S. Ohtori², M. Sakamoto³, A. Chuma⁴, I. Abe⁵, K. Shimizu⁶

¹Division of Orthopaedic Surgery, Chiba Children's Hospital, Chiba City, Chiba, Japan; ²Department of Orthopaedic Surgery, Graduate School of Medicine, Chiba University, Chiba, Japan; ³Department of Orthopaedic Surgery, Chiba Kaihin Municipal Hospital, Chiba, Japan; ⁴Department of Orthopaedic Surgery, Joto Social Insurance Hospital, Tokyo, Japan; ⁵Department of Orthopaedic Surgery, National Hospital Organization Chiba Medical Center, Chiba, Japan; ⁶Department of Orthopaedic Surgery, Chiba Rosai Hospital, Ichihara City, Chiba, Japan.

Abstract

Objective

Systemic lupus erythematosus (SLE) patients are at high risk of developing osteonecrosis, as they require corticosteroid therapy for life. The purpose of this study was to use periodic MRI analysis to clarify (1) the incidence of new osteonecrosis associated with long-term corticosteroid therapy in SLE patients, and (2) the risk factors for delayed osteonecrosis in SLE patients.

Methods

We prospectively studied 291 joints (134 hips and 157 knees) in 106 SLE patients without osteonecrosis after initial corticosteroid therapy, with a mean follow-up period of 13.6 years and a follow-up rate of 71%. All patients had undergone periodic MRI examination of the hip and knee joints for >10 years.

Results

New osteonecrosis developed in 6 joints (3%) and only occurred after SLE recurrence in association with increased corticosteroid doses (to >30 mg/day [$p=0.008$]). New lesions were delayed for a mean 5.9 years after initial corticosteroid administration. The mean time from SLE recurrence to appearance of new lesions was 6.2 months. SLE recurrence occurred in 131 joints (45%), while SLE was well controlled in 160 joints (55%).

Conclusion

We suggest that with respect to long-term effects, total cumulative dose and duration of corticosteroid therapy do not contribute to osteonecrosis. However, SLE recurrence is a risk factor for new osteonecrosis. We recommend MRI screening for osteonecrosis at SLE recurrence.

Key words

Corticosteroid, systemic lupus erythematosus, osteonecrosis, MRI, long-term follow-up.

Junichi Nakamura, MD
Seiji Ohtori, MD
Masaaki Sakamoto, MD
Atsushi Chuma, MD
Isao Abe, MD
Koh Shimizu, MD

Please address correspondence and reprints requests to:

Junichi Nakamura, MD,
Division of Orthopaedic Surgery,
Chiba Children's Hospital,
579-1 Heta-Chou,
Midori-ku, Chiba City,
Chiba, Japan 266-0007.
E-mail: njonedr@yahoo.co.jp

Received on March 18, 2009; accepted in revised form on October 5, 2009.

© Copyright CLINICAL AND EXPERIMENTAL RHEUMATOLOGY 2010.

Introduction

Corticosteroid treatment is known to be associated with osteonecrosis. In 1960, Heimann *et al.* (1) first reported osteonecrosis of the femoral head following high-dose corticosteroid therapy. However, the pathogenesis of corticosteroid-induced osteonecrosis remains unknown (2). In the past, early-stage osteonecrosis was frequently misdiagnosed due to a lack of symptoms and a lack of changes as observed using simple x-ray imaging. Recently, MRI has emerged as the gold standard for initial diagnosis of osteonecrosis (3-8). MRI of bilateral hip and knee joints is considered to be an effective screening method for osteonecrosis, as Sakamoto (9) reported that the frequency of corticosteroid-induced osteonecrosis is highest in the knee, followed by the hip, ankle, and shoulder joints.

Systemic lupus erythematosus (SLE) is one of the most common diseases underlying corticosteroid-induced osteonecrosis. (10-13) Oinuma *et al.* (14) reported that osteonecrosis most commonly occurs in SLE patients approximately 3 months after initiation of high-dose corticosteroid therapy. This is problematic, as corticosteroids are required for long-term maintenance of autoimmune activity in SLE, as well as during initial treatment. Oinuma *et al.* (14) did not observe osteonecrosis in SLE patients 1 year after the initiation of corticosteroid therapy. Zizic *et al.* (15) also reported that neither the total cumulative dose nor the duration of corticosteroid therapy was associated with osteonecrosis. However, to our knowledge, the long-term effects of corticosteroid therapy on osteonecrosis incidence in SLE patients are thus far unknown (16-19).

The purpose of this study was to use periodic MRI analysis to clarify (1) the incidence of new osteonecrosis associated with long-term corticosteroid use, and (2) the risk factors for delayed osteonecrosis in SLE patients.

Patients and methods

We reviewed the medical records of 201 SLE patients who received corticosteroids from 1986 to 1997. The following inclusion criteria were used: (1) fulfillment of the 1982 revised criteria for

the classification of SLE of the American College of Rheumatology (20), (2) MRI screening of hip and knee joints for osteonecrosis after initial corticosteroid therapy, and (3) prospective, periodic MRI examination of joints without osteonecrosis for at least 10 years. Diagnosis of osteonecrosis was based on the low-intensity band on MRI T1-weighted coronal images (band-like pattern) using the 2001 revised criteria for classification of osteonecrosis of the femoral head of the Japanese Ministry of Health, Labor and Welfare (21). We then excluded 14 joints that had not undergone MRI and 381 joints that had osteonecrosis within 1 year of initial corticosteroid therapy. Of the remaining 409 joints without osteonecrosis, 291 joints (134 hips and 157 knees) in 106 patients were followed-up sufficiently, with a mean follow-up period of 13.6 years (range, 10 to 20 years) and a follow-up rate of 71%.

MRI was performed using a 0.5-Tesla superconductive unit (MRT-50; Toshiba, Tokyo, Japan) from 1986 to 1993, and a 1.5-Tesla superconductive unit (Signa; GE Medical Systems, Milwaukee, Wisconsin) from 1986 to 2008. T1-weighted spin-echo images were obtained with repetition times (TR) of 300 to 400 ms and echo times (TE) of 18 to 40 ms, using a 5 to 7.5mm thickness. Short-inversion-time inversion-recovery images were obtained with a TR of 1,500 to 3,000 ms, inversion times of 100 to 150 ms, and a TE of 30 to 42 ms, at a 10-mm thickness. The image matrix was 256 × 256 elements. To obtain comparable slices, hips were positioned at neutral adduction/abduction, 0° of flexion, and 10° to 15° of internal rotation. Multiple slices in the coronal plane were acquired for both the hip and knee joints, with the central slices positioned at the center of the femoral head.

The research protocol complied with the Helsinki Declaration, was approved by the institutional review boards, and was registered with the University Hospital Medical Information Network (UMIN). We did not receive any financial incentives or collaborate with other individuals or organisations. The study authors had no external funding source or conflicts of interest.

Competing interests: none declared.

Incidence of new osteonecrosis

Incidence of delayed, new osteonecrosis was evaluated using periodic MRI during the follow-up period. The time to new lesion appearance was also evaluated.

Corticosteroid use in the SLE recurrence and non-recurrence groups

The incidence of new osteonecrosis was compared between the SLE recurrence and non-recurrence groups using Fisher's exact probability test (SPSS 16.0, Chicago, Illinois). SLE recurrence was defined as requirement for an increased corticosteroid dosage of >30 mg/day. For comparison purposes, doses of different corticosteroids were converted into their equivalent prednisone doses (16). Age at SLE onset, highest corticosteroid dose at initial therapy (mg/day), mean corticosteroid dose (mg/day), final corticosteroid dose (mg/day), total cumulative corticosteroid dose (g), and duration of corticosteroid therapy (years) were also compared using the Mann-Whitney U-test. The mean corticosteroid dose was calculated as (total cumulative corticosteroid dose)/(duration of corticosteroid therapy)/365 × 1000. In the SLE recurrence group, the highest corticosteroid doses at initial therapy and at SLE recurrence were compared using the Wilcoxon signed-ranks test. A *p*-value <0.05 was considered significant.

Delayed osteonecrosis in the SLE recurrence group

In the SLE recurrence group, age at SLE onset, highest corticosteroid dose at initial therapy, number of SLE recurrences, highest corticosteroid dose at SLE recurrence, mean corticosteroid dose, final corticosteroid dose, total cumulative corticosteroid dose, and duration of corticosteroid therapy were compared between joints with and without delayed osteonecrosis using the Mann-Whitney U-test.

The other risk factor for osteonecrosis

The type of corticosteroids, prevalence of alcohol, smoking, and antiphospholipid antibody were evaluated.

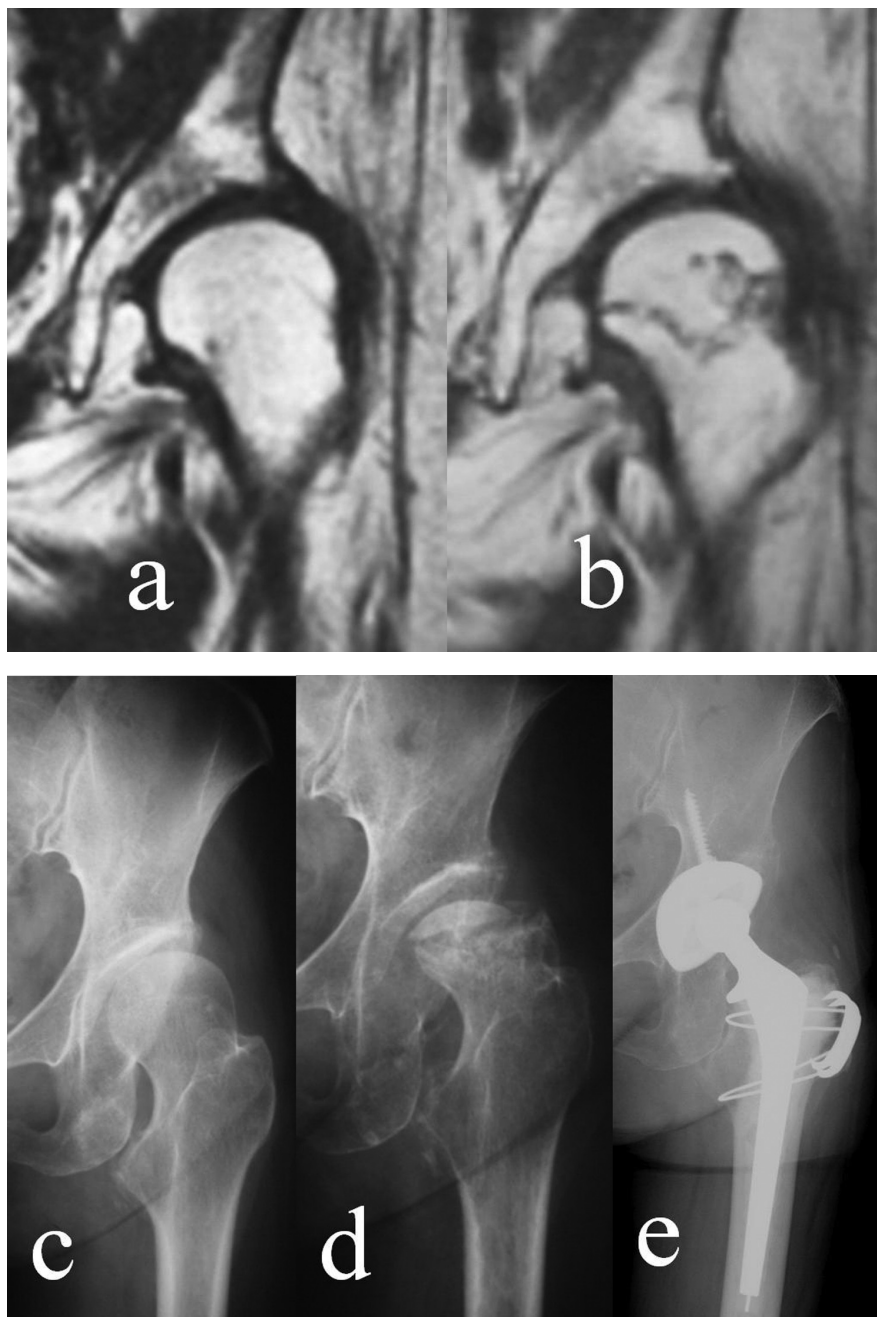


Fig. 1. A 57-year-old female with a history of developmental dysplasia of the hip in the left hip. She had received corticosteroids for SLE for 12 years. Simple x-ray imaging and MRI of the left hip showed no evidence of osteonecrosis of the femoral head (a, c). However, osteonecrosis appeared in the left hip 6 months after corticosteroid dosing was increased to 60 mg/day due to SLE recurrence (b). Osteonecrosis of the left hip was large (type C2) and was collapsed 3 months later (d). She underwent total hip arthroplasty 1 year later (e).

Results*Incidence of new osteonecrosis*

New osteonecrosis developed in 6 of 291 joints (2%), including 2 hips and 4 knees. The new lesions occurred a mean 5.9 years (range, 1.3 to 9.9 years) after initial corticosteroid administration. All 6 osteonecrosis cases occurred immediately after the corticosteroid dose was

increased due to SLE recurrence (Fig. 1). The mean time from SLE recurrence to appearance of new lesions was 6.2 months (range: 3 to 11 months).

Corticosteroid use in the SLE recurrence and non-recurrence groups
SLE recurrence was noted in 131 joints (45%), including 68 hips and 63 knees,

while SLE was well controlled with a corticosteroid dose <30 mg/day in 160 joints (55%), which comprised the SLE non-recurrence group (66 hips and 94 knees). New osteonecrosis occurred only in the SLE recurrence group, while it was not observed in the SLE non-recurrence group ($p=0.008$, Table I). Age at SLE onset was significantly lower in the SLE recurrence group than in the non-recurrence group ($p<0.001$, Table II). The mean corticosteroid dose, final corticosteroid dose, and total cumulative corticosteroid dose were significantly higher in the SLE recurrence group than in the non-recurrence group ($p<0.001$). The highest corticosteroid dose at initial therapy and the duration of corticosteroid therapy did not significantly differ between groups. The highest corticosteroid dose at SLE recurrence was 49 mg/day (range, 30 to 60 mg/day), which was significantly lower than that at initial therapy ($p<0.001$).

Delayed osteonecrosis in the SLE recurrence group

The number of SLE recurrences, highest corticosteroid dose at initial therapy, highest corticosteroid dose at SLE recurrence, mean corticosteroid dose, final corticosteroid dose, and total cumulative corticosteroid dose were not significantly different between the delayed osteonecrosis and non-osteonecrosis groups (Table III). The duration of corticosteroid therapy was significantly shorter in the delayed osteonecrosis group than in the non-osteonecrosis group ($p=0.006$).

The other risk factor for osteonecrosis

The type of corticosteroids depended on the rheumatologist's preference. All 106 patients were treated with prednisolone. While 34 patients were treated with only prednisolone, 72 patients additionally or alternatively received the other kind of corticosteroids during the follow-up period as follows, hydrocortisone sodium succinate in 43 patients, hydrocortisone sodium phosphate in 4 patients, methylprednisolone sodium succinate in 27 patients, methylprednisolone in 2 patients, betamethasone in 12 patients, and dexametha-

Table I. Association between SLE recurrence and new osteonecrosis.

Osteonecrosis (number of joints)	Osteonecrosis (n=6)	No osteonecrosis (n=285)
SLE recurrence (n=131)	6*	125
SLE non-recurrence (n=160)	0	160

* $p=0.008$ (Fisher's exact probability test) versus SLE non-recurrence group.

Table II. Corticosteroid use in the SLE recurrence and non-recurrence groups.

Group (number of joints)	SLE recurrence (n=131)	SLE non-recurrence (n=160)	p-value
Age at SLE onset (years)	24.9 (9.6)	31.9 (13.3)	<0.001
Highest corticosteroid dose at initial therapy (mg/day)	56.0 (14.0)	56.4 (15.0)	NS
Mean corticosteroid dose (mg/day)	14.4 (4.2)	9.6 (3.5)	<0.001
Final corticosteroid dose (mg/day)	11.8 (6.2)	6.9 (3.6)	<0.001
Total cumulative corticosteroid dose (g)	70.1 (24.2)	45.2 (17.2)	<0.001
Duration of corticosteroid therapy (years)	17.5 (6.6)	16.2 (6.3)	NS

Values shown represent the mean (standard deviation); Mann-Whitney U-test; NS: not significant.

Table III. Corticosteroid use of the delayed osteonecrosis in SLE recurrence group.

Group (number of joints)	Delayed osteonecrosis (n=6)	Non-osteonecrosis (n=125)	p-value
Age at SLE onset (years)	27.8 (15.1)	24.8 (9.4)	NS
Highest corticosteroid dose at initial therapy (mg/day)	53.3 (10.3)	56.2 (14.1)	NS
Number of SLE recurrence (times)	2.2 (1.2)	2.2 (1.5)	NS
Highest corticosteroid dose at SLE recurrence (mg/day)	50.0 (11.0)	47.7 (13.2)	NS
Mean corticosteroid dose (mg/day)	16.6 (5.5)	14.3 (4.1)	NS
Final corticosteroid dose (mg/day)	15.0 (4.5)	11.7 (6.2)	NS
Total cumulative corticosteroid dose (g)	60.3 (27.8)	70.5 (24.0)	NS
Duration of corticosteroid therapy (years)	10.9 (1.7)	13.7 (2.8)	0.006

Values shown represent the mean (standard deviation); Mann-Whitney U-test; NS: not significant.

sone in 5 patients. All the patients were taking oral corticosteroids in a single dose early morning. There were no trends between osteonecrosis and type of corticosteroids. Alcohol consumption was observed in 14 patients. All 14 patients sometimes drank a little and no patients were alcoholism. Smoking was also observed in 16 patients; 9 patients smoked less than 10 cigarettes a day, 6 patients smoked 10-20 cigarettes a day, and one patient smoked 30 cigarettes a day. There were also no trends between osteonecrosis and alcohol or smoking. Antiphospholipid antibody was detected in 10 patients (9%). However, there were no trends between osteonecrosis and antiphospholipid antibody.

Discussion

In the present study, no new lesions were identified in SLE patients who received low-dose corticosteroids (equivalent to <30 mg/day of prednisone) for more than 1 decade. Bluemke *et al.* (18) performed gadolinium-enhanced MRI in SLE patients without osteonecrosis who received long-term corticosteroid therapy, and reported that perfusion of the femoral head was maintained. We suggest that with respect to long-term effects, total cumulative corticosteroid dose and duration of corticosteroid therapy do not contribute to osteonecrosis. These findings should provide great relief to both SLE patients and rheumatologists alike.

Delayed osteonecrosis occurred only in patients who experienced an SLE recurrence. This result supports Felson's hypothesis that osteonecrosis occurs in association with high-dose corticosteroid therapy. Patients with collagen diseases, including SLE, are at high risk of developing osteonecrosis, since they require corticosteroid therapy for life. However, few reports about the relationship between SLE recurrence and delayed osteonecrosis have been published. In the present study, SLE recurrence occurred in 45% of patients after initial therapy, necessitating a corticosteroid dosage increase to >30 mg/day of prednisone. We suggest that SLE recurrence is a risk factor for delayed osteonecrosis, and therefore recommend MRI screening for osteonecrosis beginning at SLE recurrence.

The incidence of osteonecrosis at SLE recurrence was substantially lower than that reported at initial corticosteroid therapy by Oinuma *et al.* (14) (3% vs. 44%). We did not observe any association between new osteonecrosis and corticosteroid use in the SLE recurrence group. However, we expect that the difference between the highest corticosteroid dose at initial therapy and that at recurrence is likely to be related to the difference in the incidence of osteonecrosis. Felson *et al.* (16) reported a strong correlation between daily oral corticosteroid dose and osteonecrosis rate based on a meta-analysis. These authors estimated that the dose effect reflected a 4.6% increase in the risk of osteonecrosis for every 10 mg/day rise in corticosteroids during the first 6 months of therapy. Another possibility is individual differences in corticosteroid sensitivity with respect to development of osteonecrosis. Masada *et al.* reported that increased hepatic enzyme activity decreased the risk of corticosteroid-induced osteonecrosis in a rabbit model (22). Thus, we suggest that the patients who narrowly escaped development of osteonecrosis at initial therapy were inherently resistant to the osteonecrosis-inducing effects of corticosteroids, thereby remaining free of osteonecrosis, even at SLE recurrence. MRI has become the gold standard for initial diagnosis of osteonecrosis.

However, prospective MRI studies of osteonecrosis remain rare. To our knowledge, the present study is the first prospective MRI study to evaluate the long-term natural history of SLE patients without osteonecrosis. Yoshida *et al.* (19) prospectively followed SLE patients with MRI, although these investigators did not evaluate patients without osteonecrosis.

This study had several limitations. The first limitation was the conversion of corticosteroid dose into its equivalent prednisone dose. Each corticosteroid, including cortisone, dexamethasone, and betamethasone, may have different effects, even when equivalent doses are used. Moreover, we did not evaluate the influence of methylprednisolone pulse therapy. However, we applied the previously established method for corticosteroid dose conversion reported by Felson *et al.* to minimise any discrepancies (16). The second limitation was that antiphospholipid syndrome was not fully evaluated. Asherson *et al.* (23) documented 2 patients with primary antiphospholipid syndrome who had osteonecrosis in the absence of previous corticosteroid therapy and suggested that antiphospholipid syndrome was associated with osteonecrosis (24). According to Assolin-Dayán's review (25), average prevalence of antiphospholipid antibodies among SLE patients was 44%. We could not testify but speculate the relation between the low prevalence of antiphospholipid antibody and the low incidence of osteonecrosis in this study. The third limitation was that the potential influence of other drugs, such as anti-coagulants, cholesterol-lowering medications, and bisphosphonates, was not assessed. Sheikh *et al.* (26) suggested that an imbalance between tissue-type plasminogen activator and plasminogen activator inhibitor was a risk factor for osteonecrosis. Oinuma *et al.* (27) also reported that plasmin- α 2-plasmin inhibitor complex levels were significantly higher in patients with osteonecrosis than in patients without osteonecrosis. Further study is required to determine any associations between these factors and the development of osteonecrosis.

In conclusion, we suggest that with

respect to long-term effects, total cumulative dose and duration of corticosteroid therapy do not contribute to osteonecrosis. However, SLE recurrence is a risk factor for new osteonecrosis. We recommend MRI screening for osteonecrosis at SLE recurrence.

References

- HEIMANN WG, FREIBERGER RH: Avascular necrosis of the femoral head and humeral heads after high dosage corticosteroid therapy. *N Engl J Med* 1960; 263: 672-5.
- MANKIN HJ: Nontraumatic necrosis of bone (osteonecrosis). *New Engl J Med* 1992; 326: 1473-9.
- MOON KL, GENANT HK, HELMS CA, CHAFETZ NI, CROOKS LE, KAUFMAN L: Musculoskeletal applications of nuclear magnetic resonance. *Radiology* 1983; 147: 161-71.
- HAUZEUR JP, PASTEELS JL, SCHOUTENS A *et al.*: The diagnostic value of magnetic resonance imaging in non-traumatic osteonecrosis of the femoral head. *J Bone Joint Surg [Am]* 1989; 71: 641-9.
- SHIMIZU K, MORIYA H, AKITA T, SAKAMOTO M, SUGURO T: Prediction of collapse with magnetic resonance imaging of avascular necrosis of the femoral head. *J Bone Joint Surg [Am]* 1994; 76: 215-23.
- SAISU T, SAKAMOTO K, YAMADA K *et al.*: High incidence of osteonecrosis of femoral head in patients receiving more than 2 g of intravenous methylprednisolone after renal transplantation. *Transplant Proc* 1996; 28: 1559-60.
- SAKAMOTO M, SHIMIZU K, IIDA S, AKITA T, MORIYA H, NAWATA Y: Osteonecrosis of the femoral head. A prospective study with MRI. *J Bone Joint Surg [Br]* 1997; 79: 213-19.
- IIDA S, HARADA Y, SHIMIZU K *et al.*: Correlation between bone marrow edema and collapse of the femoral head in steroid-induced osteonecrosis. *Am J Roentgenol* 2000; 174: 735-43.
- SAKAMOTO M: A prospective study of steroid-induced osteonecrosis by MRI screening. (in Japanese) *Nippon Seikeigeka Gakkai Zasshi* 1994; 68: 367-78.
- DUBOIS EL, COZEN L: Avascular (aseptic) bone necrosis associated with systemic lupus erythematosus. *JAMA* 1960; 174: 966-71.
- KLIPPEL JH, GERBER LH, POLLAK L, DECKER JL: Avascular necrosis in systemic lupus erythematosus: Silent symmetric osteonecrosis. *Am J Med* 1979; 67: 83-7.
- NAGASAWA K, ISHII Y, MAYUMI T *et al.*: Avascular necrosis of bone in systemic lupus erythematosus: possible role of haemostatic abnormalities. *Ann Rheum Dis* 1989; 48: 672-76.
- GLADMAN DD, UROWITZ MB, CHAUDHRY-AHLUWALIA V, HALLET DC, COOK RJ: Predictive factors for symptomatic osteonecrosis in patients with systemic lupus erythematosus. *J Rheumatol* 2001; 28: 761-5.
- OINUMA K, HARADA Y, NAWATA Y *et al.*: Osteonecrosis in patients with systemic

- lupus erythematosus develops very early after starting high dose corticosteroid treatment. *Ann Rheum Dis* 2001; 60: 1145-8.
15. ZIZIC TM, MARCOUX C, HUNGERFORD DS, DANSEREAU JV, STEVENS MB: Corticosteroid therapy associated with ischemic necrosis of bone in systemic lupus erythematosus. *Am J Med* 1985; 79: 596-604.
 16. FELSON DT, ANDERSON JJ: A cross-study evaluation of association between steroid dose and bolus steroids and avascular necrosis of bone. *Lancet* 1987; 1: 902-6.
 17. NAGASAWA K, TSUKAMOTO H, TADA Y *et al.*: Imaging study on the mode of development and changes in avascular necrosis of the femoral head in systemic lupus erythematosus: long-term observations. *Br J Rheumatol* 1994; 33: 343-7.
 18. BLUEMKE DA, PETRI M, ZERHOUNI EA: Femoral head perfusion and composition: MR imaging and spectroscopic evaluation of patients with systemic lupus erythematosus and at risk for avascular necrosis. *Radiology* 1995; 197: 433-8.
 19. YOSHIDA T, KANAYAMA Y, OKAMURA M, NEGORO N, INOUE T, YOSHIKAWA J: Long-term observation of avascular necrosis of the femoral head in systemic lupus erythematosus: an MRI study. *Clin Exp Rheumatol* 2002; 20: 525-30.
 20. TAN EM, COHEN AS, FRIES JF *et al.*: The 1982 revised criteria for the classification of systemic lupus erythematosus. *Arthritis Rheum* 1982; 25: 1271-7.
 21. SUGANO N, ATSUMI T, OHZONO K, KUBO T, HOTOKEBUCHI T, TAKAOKA K: The 2001 revised criteria for diagnosis, classification, and staging of idiopathic osteonecrosis of the femoral head. *J Orthop Sci* 2002; 7: 601-5.
 22. MASADA T, IWAKIRI K, ODA Y *et al.*: Increased hepatic cytochrome P4503A activity decreases the risk of developing steroid-induced osteonecrosis in a rabbit model. *J Orthop Res* 2008; 26: 91-5.
 23. ASHERSON RA, LIOTE F, PAGE B *et al.*: Avascular necrosis of bone and antiphospholipid antibodies in systemic lupus erythematosus. *J Rheumatol* 1993; 20: 284-8.
 24. ASHERSON RA, CEERVERA R: Microvascular and microangiopathic antiphospholipid associated syndromes ("MAMPS"): semantic or antisemantic? *Autoimmun Rev*. 2008; 7: 164-7.
 25. ASSOLIN-DAYAN Y, CHANG C, GREENSPAN A, SHOENFELD Y, GERSHWIN E: Pathogenesis and natural history of osteonecrosis. *Sem Arth Rheum* 2002; 32: 94-124.
 26. SHEIKH JS, RETZINGER GS, HESS EV: Association of osteonecrosis in systemic lupus erythematosus with abnormalities of fibrinolysis. *Lupus* 1998; 7: 42-8.
 27. OINUMA K, HARADA Y, NAWATA Y *et al.*: Sustained hemostatic abnormality in patients with steroid-induced osteonecrosis in the early period after high-dose corticosteroid therapy. *J Orthop Sci* 2000; 5: 374-9.