

Livedo reticularis is a marker for predicting multi-system thrombosis in antiphospholipid syndrome

E. Toubi¹, I. Krause^{2,3}, A. Fraser³, S. Lev³, L. Stojanovich⁴, J. Rovensky⁵, M. Blank², Y. Shoenfeld²

¹Division of Allergy and Clinical Immunology, Bnai Zion Medical Center, Haifa; ²Department of Internal Medicine B and Center of Autoimmune Diseases, Sheba Medical Center, Tel Hashomer; ³Department of Medicine E, Rabin Medical Center, and Sackler Faculty of Medicine, Tel-Aviv University, Israel; ⁴Department of Rheumatology and Hospital Center, Bezanijskakosa, Belgrade, Serbia; ⁵Research Institute of Rheumatic Diseases, Piestany, Slovakia.

Abstract

Objective

Livedo reticularis (LR) is a skin vasculopathy that has been frequently described in patients with anti-phospholipid syndrome (APS) and reported to be present in association with valvular heart pathology and strokes (i.e. Sneddon's syndrome).

Methods

In a cohort of APS patients we investigated the possible association of LR with various clinical aspects of APS such as pregnancy morbidity, central nervous system (CNS) and cardiac manifestations.

Results

Livedo reticularis was found in 50/308 (16%) of APS patients, and there was a significant association with cerebrovascular accidents (CVA), migraines and epilepsy ($p = 0.01$, 0.002 , and 0.02 respectively). A similar association was also detected between LR, and the presence of cardiac valve thickening and vegetations ($p = 0.001$). No association with venous thrombosis, recurrent fetal loss, IUGR or toxemia was found.

Conclusion

Livedo reticularis is a frequent cutaneous manifestation in patients with APS. Its high association with cardiac and CNS thrombosis may suggest that LR-APS patients compose a subset at higher risk for thrombosis, and thus may require a closer follow-up and a more aggressive anticoagulation.

Key words

Livedo reticularis, anti-phospholipid syndrome, thrombosis.

Elias Toubi, MD; Ilan Krause, MD; Abigail Fraser, MD; L. Stojanovich, MD, Prof.; J. Rovinsky, MD, Prof.; Shaul Lev, MD; Miri Blank; Yehuda Shoenfeld, MD, FRCP(Hon.), Incumbent of the Laura-Schwarz-Kipp Chair for Autoimmunity.

*The first two authors contributed equally in preparing and writing this paper.

Please address correspondence to: Yehuda Shoenfeld, MD, FRCP, Head, Department of Medicine 'B', Sheba Medical Center, Tel-Hashomer 52621, Israel.

E-mail: Shoenfel@post.tau.ac.il

Received on December 9, 2004; accepted in revised form on March 4, 2005.

© Copyright CLINICAL AND EXPERIMENTAL RHEUMATOLOGY 2005.

Introduction

Livedo reticularis (LR) refers to the purple reticular mottling of the skin mostly involving the upper and lower limbs, resulting from a narrowing of the small and medium arteries at the dermis-subcutis border (1). LR appears in areas of anastomoses between two cones where reduced blood flow is associated with the dilatation of venules and capillaries, and the development of blood inflow/outflow obstruction and hyperviscosity. The histopathology of LR shows endothelitis and obliterating endarteritis with no evidence of true vasculitis (2, 3).

Apart from being the commonest skin manifestation in patients with anti-phospholipid syndrome (APS), LR is reported in association with autoimmune diseases such as systemic lupus erythematosus (SLE), systemic sclerosis, celiac disease, and in systemic vasculitis such as polyarteritis nodosa, and cryoglobulinemia (4-7). It was also reported in healthy young women mainly after exposure to cold, but when associated with APS, LR is usually disseminated and more persistent than it is in healthy subjects (2).

The higher incidence of stroke in patients with LR in the absence of other vascular risk factors was described in a context of a syndrome defined as Sneddon's (8). The association between LR and stroke, and the detection of anti-phospholipid antibodies (aPL) in some of these patients pointed to the possible association between LR and thrombosis in APS. In this regard it was shown that endothelial cell antibodies were detected in 35% of patients with Sneddon's syndrome, but were absent in patients with stroke but with no LR (9, 10).

Skin involvement may be the first manifestation of APS in 40% of patients, of whom one-third will develop multisystem thrombotic events during the course of the disease, pointing to the importance of detecting aPL in all subjects with LR (11). In the current study we demonstrate the prevalence of LR in a large cohort of APS patients and the association of LR with many clinical aspects of APS. The significant association between LR, CNS thrombosis

and cardiac manifestations of APS suggests that the presence of LR should be considered as a marker for predicting the development of thrombosis in APS.

Patients and methods

We conducted a multi-center, multinational study involving 3 centers in Israel, 2 in Serbia, and 1 in the Slovak Republic, with 308 APS patients (primary APS was diagnosed in 173 and APS associated with SLE in 135 patients). All patients met the 1997 revised Sapporo criteria for APS. The cohort included 260 women, and 48 men, mean age 40.2 ± 11.4 years, range 19-75 years, with a mean follow-up of 7.7 ± 5.5 years. All patients were retrospectively investigated for the presence of both venous and arterial thrombosis with a special emphasis on the association between LR and systemic thrombosis (recurrent fetal loss was documented in 27% of patients, venous thrombosis was diagnosed in 58% and arterial thrombosis in 50%). All patients were studied for the presence of moderate-high titers of anti-cardiolipin antibodies (aCL), anti-2glycoprotein1 antibodies (a2GPI) and lupus anticoagulant (LA).

Diagnosis of APS manifestations

Pregnancy morbidity. There were 3 unexplained consecutive spontaneous abortions before the 10th week of gestation, with maternal anatomic, or hormonal abnormalities, and paternal and maternal chromosomal causes excluded. There were one or more unexplained deaths of a morphologically normal fetus at or beyond the 10th week of gestation, with normal fetal morphology documented by ultrasound or by direct examination of the fetus. There were one or more premature births of a morphologically normal neonate at or before the 34th week of gestation because of severe pre-eclampsia or eclampsia, or severe placental insufficiency (12).
Vascular thrombosis. Episodes of venous or arterial thrombosis were diagnosed based on clinical symptoms and further confirmed by imaging, Doppler studies or angiography when needed.

Cardiac manifestations. All patients underwent 2-dimensional and Doppler

color flow echocardiographic examination for determination of heart valve abnormalities. Valvular thickening was defined as focal areas of increased echogenicity and thickening of heart valve's leaflets. For the mitral valve, a thickness of above 5 mm was considered abnormal. As for the other valves, thickness was determined according to specific standards of the medical center. Valvular dysfunction was defined as the presence of stenosis or regurgitation of at least moderate severity. Non-infectious vegetations were defined as echocardiographically identified masses protruding from valvular leaflets, in the presence of sterile blood cultures and in the absence of fever. These pathologies were considered a part of the APS only after excluding cardiac diseases, hypertension, and diabetes.

Central nervous system manifestations. Central nervous system (CNS) manifestations were defined as follows. Cerebral vascular attacks (CVA, ischemic strokes) had neurological signs lasting more than 24 h. with evidence of infarction in an anatomically consistent territory on computed tomography (CT) or magnetic resonance imaging (MRI). Cerebral transient ischemic attacks (TIAs) had neurological signs or symptoms lasting less than 24 hours and fulfilling the criteria of the classification of cerebrovascular diseases of the National Institute of Neurologic Disorder and Stroke (13). Epilepsy was diagnosed by clinical history and electro-encephalo-graphic recording. Seizures were defined according to the classification of the international league against epilepsy (14). Both idiopathic migraines and chorea were defined by a neurologist. Migraines were characterized as recurrent severe unilateral or bilateral headaches, lasting 4-72 hours, with or without aura, after excluding other relevant etiologies for these disorders such as tension headache, hypertension, or sub-acute endocarditis. Patients were not on anti-coagulation at the time of diagnosis. We chose to exclude mild-to-moderate migraines, including in the study only severe ones.

Association between LR and APS manifestations

The association between LR and the above APS manifestations was analyzed in all the patients.

Detection assays of anti-phospholipid antibodies

Both aCL and a 2-GPI were detected by ELISA. Ninety-six wells of ELISA plates (Nunc, Kamstrup, Roskilde, Denmark) were coated with cardiolipin (Sigma Chemicals Co., St. Louis, Missouri, USA) 50 µg/ml in ethanol or 2-GPI 10 µg/ml in PBS. Following blocking with 3% BSA, sera at different dilutions were added, and incubated for 2 hrs at room temperature. Bound antibodies were detected using goat anti-human IgG or IgM conjugated to alkaline phosphatase (Sigma) and appropriate substrate. Extensive washing with PBS followed each step. The color reaction was read in Titertrek ELISA reader (SLT-Labstruments, Austria) at O.D. of 405nm.

Lupus anticoagulant

LA activity was determined by screening and confirmatory procedures. Screening tests comprised activated partial thromboplastin time (APTT) and kaolin clotting time (KCT). As a confirmatory test, we used the routine hexagonal phospholipid correction assay.

Statistical analyses

Categorical variables were compared using a Chi-square test or Fisher's exact test as appropriate. Multivariate analyzes was performed by constructing logistic regression models. Statistical significance was performed as a p-value of less than 0.05.

Results

Focusing on the prevalence of LR among our APS studied patients, we asked whether the finding of LR is in association with any of the clinical aspects of APS such as pregnancy morbidity, vascular thrombosis, and cardiac or CNS manifestations.

In all patients LR was recorded at the time of APS diagnosis and was documented in 50/308 (16%) of the APS patients. When the prevalence of LR in aCL positive patients was examined,

the odds ratio for LR was 3.2 (95% Confidence Interval between 1.5 and 7.1), while controlling for the presence of a 2GPI antibodies and LA. However, the odds ratio for the prevalence of LR in LA positive patients was not found significant. The distribution of aPL positivity at the time of APS diagnosis was as follows: aCL was found in 192/308 (62%), a 2GPI in 217/308 (70%) (both aCL and a 2GPI were of IgG isotype in 174 patients, of IgM isotype in 53 and 81 patients had both isotypes) and LA in 239/308 (77%). A similar distribution of aPLs was documented when LR patients were looked separately.

The association of LR with any of the clinical aspects of APS

Pregnancy morbidity. We could not detect a significant association between the finding of LR and recurrent fetal loss, IUGR or pregnancy toxemia. Recurrent fetal loss was documented in 84/305 (27%) of APS patients, but only 15 had this complication in association with LR.

Among 12 patients who developed IUGR, LR was found in only one. Whereas toxemia was diagnosed in 31/305 (%) of patients, only 4 of them demonstrated LR as well (Fig. 1).

Association of LR with vascular thrombosis. Venous thrombosis was diagnosed in 179/308 (58%) of patients. However, LR was evident in only 30 of these (p = 0.8). When arterial thrombosis was the subject of this association, it was confirmed in 153/308 (50%) of patients (CVA/TIA in 35% of patients, myocardial infarction in 7% and other arterial thrombotic events such as retinal, skin or renal in 8% of patients). Of these, 34 demonstrated recurrent thrombosis in association with LR (p = 0.005). CVAs/TIAs was considered in this study as vascular thrombosis and was found in 107/305 (35%) of studied patients. In 25 patients this was in association with the presence of LR (p = 0.01) (Fig. 2). Retinal, skin and renal thrombosis as a whole group were not found in association with the presence of LR.

Association of LR with cardiac manifestations. Myocardial infarction was

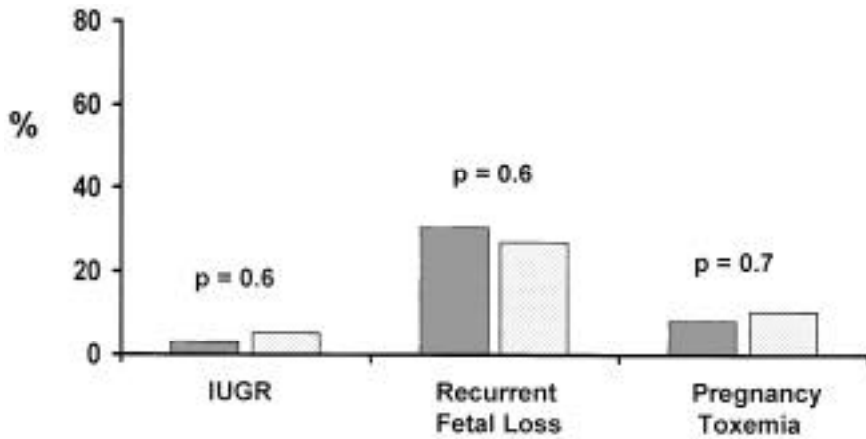


Fig. 1. No significant difference in the incidence of IUGR, recurrent fetal loss and toxemia among APS patients with or without livedo reticularis (LR).

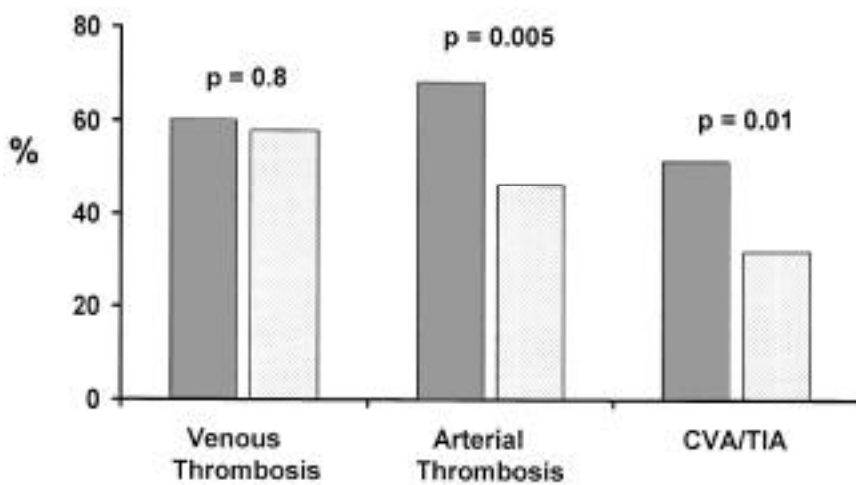


Fig. 2. The incidence of venous thrombosis among APS patients with or without LR was found to be similar, whereas the incidence of arterial thrombosis and CVA/TIA was significantly higher among APS patients with LR than in those without LR.

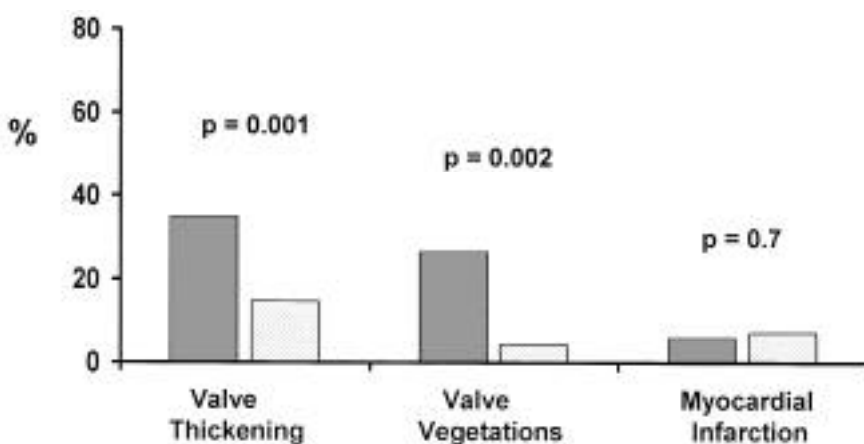


Fig. 3. The incidence of valve thickening and valve vegetations is higher among APS patients with LR than those without. However, myocardial infarction was found to be similar in both groups.

diagnosed in 22/305 (7%) of patients, but only 3 of these LR was in association with this complication ($p = 0.7$).

Valvular vegetations as diagnosed by ECHO were detected in 24/307 (8%) patients and in 13 of them LR was

noticed also ($p = 0.001$). Valve thickening was demonstrated in 55/305 (18%) of patients, of these LR was present in 17 patients ($p = 0.001$) (Fig. 3).

Association of LR with CNS involvement

53 (17%) APS patients suffered from moderate to severe attacks of migraine. LR was present in 14 of them ($p = 0.002$). Epilepsy was documented in 31/305 (10%) of patients, 11 of whom had also LR ($p = 0.02$). Though in a small sample of patients, 5 suffered from chorea that was related to APS. In 3 of these LR was present as well ($p = 0.007$) (Fig.4).

All of the above associations between LR and the occurrence of thrombotic events were similar when primary APS and APS associated with SLE were investigated separately.

Discussion

The significant association of LR with heart valve pathology, strokes, and migraines, (as found in our current study), strengthens previous reports that LR should become an early predictor of recurrent thrombosis in APS patients (15).

The prevalence of aPL in the general population was reported to be between 2-4% for both aCL and LA (16), whereas the prevalence of these antibodies in patients with SLE was estimated to be present in 30-50% of patients (17). When individuals with either positive LA or aCL were followed prospectively, the total incidence for the development of a thrombotic event was 2.5%/patient-year. However, a rate of 5.4%/patient-year was documented in those with a previous thrombosis compared to a rate of 0.95% patient-year in asymptomatic subjects.

This points to the fact that the presence of aPL by itself is not sufficient for an event, and that either a clinical or a laboratory factors should be introduced in order to predict future thrombosis in APS patients (18). High titers of aCL and a history of previous thrombosis were found to be important risk factors for predicting a high recurrence rate of thrombosis in APS patients. This rate was reported to be as high as 20% pa-

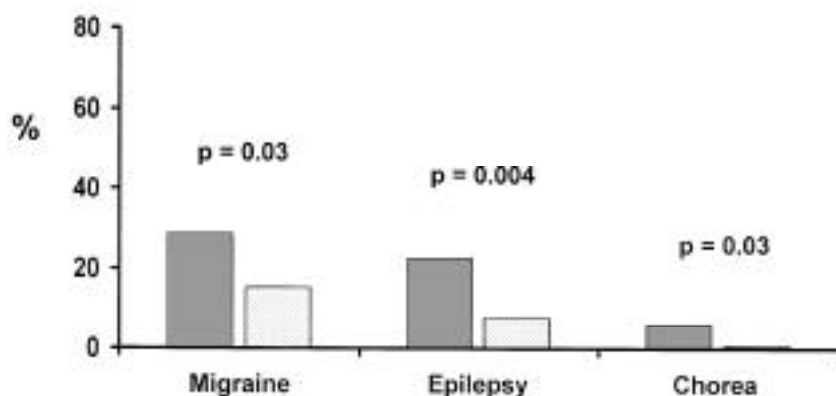


Fig. 4. The incidence of migraines, epilepsy and chorea was significantly higher among APS patients with LR than those without.

tient-year of follow-up in APS patients with a history of previous thrombosis. In this regard a meta-analysis study examined the risk of recurrent thrombosis in aPL-positive patients. The odds ratio for LA was 11.1 and 3.21 for aCL if higher titers were found (19, 20). Compatible with that is the increased prevalence of LR in our APS patients, with an odds ratio of 2.8 for aCL and 1.3 for LA.

In this regard our finding in this cohort of APS patients of a high association between LR and both cardiac and CNS abnormalities, could improve our abilities in predicting the development of systemic thrombosis in such patients. The possibility that risk factors for the development of CNS or cardiac involvement are additive, supports our finding and suggests that LR in APS patients is an additional predicting factor along with higher titers of aCL, age, hypertension and others.

The occurrence of myocardial infarction (MI) in young people was found to be associated with the presence of aPL, thus considered in some to be a presenting symptom of APS (21, 22). Previous studies already pointed to the frequent valvular heart disease in APS patients. In many, valvular disease is asymptomatic being detected by a routine two dimensional and/or Doppler echocardiography. However, valvular replacement was required in 24% of APS patients and many reported also on cases with severe valvular dysfunction resulting in cardiac failure (15, 23). This is why it is important to establish both clinical and laboratory mark-

ers that could predict the possible development of these cardiac abnormalities. In this regard it was shown that in patients with valvular heart disease, a significantly higher prevalence of arterial thrombosis, strokes, and LR was observed (15). Our current findings of the high association between the presence of LR and the development of valvular disease goes in one hand with the above finding and encourages the strategy that in APS patients the presence of LR should become a reason for advising such patients to undergo frequent echocardiographic examination for early detection of heart valve pathology.

The relationship of LR with CNS pathology was also investigated previously. It was found that primary migraines (in no relation with APS), was found to occur in significant association with stroke, coronary artery disease and deep venous thrombosis when LR was present (24). Assessing the frequency of epilepsy in primary APS, Shoenfeld Y *et al.* (25) found that the risk to develop epilepsy was linked to vascular disease as manifested by higher incidence of CNS involvement, valvulopathy and LR. Our current study further confirms the significant association between LR and CNS involvement including migraines, epilepsy and chorea. These findings encourage us to propose here also that APS patients with LR should be followed closely and questioned frequently if migraines evolved or increased recently. In this case brain CT or MRI could be advised for an early CNS pathology detection.

One can assume that the pathogenic mechanisms that underlie the development of LR and CNS or cardiac involvement are common. One mechanism is the deposition of aCL in the sub-endothelial layer of capillaries resulting in superficial thrombosis and mononuclear-cell infiltration. Another mechanism is the induction of aPL mediated inflammation by the deposition of aPL in endothelial cells and their cross-reactivity with other auto-antibodies such as anti-oxidized LDL and endothelial antibodies. Autoantibodies including aCL, anti-endothelial cell and anti-dsDNA antibodies have each been demonstrated to react with endothelial cells (ECs) *in vitro*, providing a stimulatory signal and up-regulate adhesion molecules or tissue factors (26). In this respect it was demonstrated that IgG from patients with APS is able to enhance EC adhesion molecule expression and monocyte adherence. This capacity of aPL to activate ECs may be involved in the development of diffuse thrombotic microvasculopathy (27). The persistence of LR as a possible clue for an ongoing chronic endothelial cell damage that could influence aCL production and that aCL titer could be a consequence of a continuous endothelial cell damage. The possible increased apoptosis of endothelial cells in patients with LR could be a source for continuous and persistent production of aCL leading to a further systemic thrombosis.

The presence of LR in APS patients as a predicting factor for CNS and cardiac abnormalities and a higher incidence of thrombosis in these patients, indicates that clinicians should be aware of this association since early diagnosis can lead to early intervention.

The main issue will remain how to approach APS patients in whom LR is persistent. Do we follow them differently? Moreover, should we aim to maintain such patients on higher INR (3-3.5 units) which might better prevent them from developing recurrent thrombosis (28)? The other important issue to consider is patients with significant titers of aPL, LR, but presenting only severe migraines and no clinical or imaging manifestations suggestive

of the syndrome. In this respect it was stated by G.V. Hughes, that a brave physician would argue that some migraine patients even when lack CT or MRI evidence for APS may benefit from anti-coagulation. This statement could be also true in APS whose recent symptoms are LR and/or migraines only.

Future studies should investigate the issue of treating this subset of patients with the persistence of LR differently than those without LR.

References

1. ENG AM: Cutaneous expression of antiphospholipid syndrome. *Semin Thromb Hemost* 1994; 20: 71-8.
2. GIBSON GE, DANIEL SU WP, PITTELKOW MR: Antiphospholipid syndrome and the skin. *J Am Acad Dermatol* 1997; 36: 970-82.
3. ALEGRE VA, WINKELMANN RK: Histopathologic and immunofluorescence study of skin lesions associated with circulating lupus anticoagulant. *J Am Acad Dermatol* 1988; 19: 117-24.
4. NALDI L, LOCATI F, MARCHESI L *et al.*: Cutaneous manifestations associated with antiphospholipid antibodies in patients with suspected primary APS: a case control study. *Ann Rheum Dis* 1993; 52: 219-22.
5. SHAMIR R, SHOENFELD Y, BLANK M: The prevalence of coeliac disease antibodies in patients with the antiphospholipid syndrome. *Lupus* 2003; 12: 394-99.
6. KATAYAMA I, NISHIOKA K, OTOYAMA K: Clinical analysis of anti-cardiolipin-beta2 glycoprotein 1 antibody positive patients in antiphospholipid syndrome. *J Dermatol Sci* 1995; 9:215-20.
7. ASHERSON RA, CERVERA R: Unusual manifestations of the antiphospholipid syndrome. *Clin Rev Allergy Immunol* 2003; 25: 61-78.
8. TOURBACH A, PIETTE JC, IBA-ZIZEN MT, LYON-CEAN O, GODEAU P, FRANCE'S C: The natural course of cerebral lesions in Sneddon's syndrome. *Arch Neurol* 1997; 54: 53-60.
9. FRANCES C, PIETTE JC: The mystery of Sneddon's syndrome: relationship with antiphospholipid syndrome and systemic lupus erythematosus. *J Autoimmun* 2000; 15: 139-43.
10. FRANCE'S C, LE TONQUEZE M, SLOHZIN KV *et al.*: Prevalence of antiendothelial antibodies in patients with Sneddon's syndrome. *J Am Acad Dermatol* 1995; 33: 64-8.
11. BATTAGLIOTTI CA: Skin manifestations of the antiphospholipid syndrome. KHAMASHTA MA, (Ed.), Springer-Verlag London Ltd., 2000: 59-69.
12. WILSON WA, GHARAVI AE, KOIKE T *et al.*: International consensus statement on preliminary classification criteria for definite antiphospholipid syndrome. Report of an international workshop. *Arthritis Rheum* 1999; 42: 1309-11.
13. WHISNANT JP: Special report from the National Institute of Neurologic Disorder and Stroke. Classification of cerebrovascular diseases. *Stroke* 1990; 21: 637-76.
14. THE COMMISSION ON CLASSIFICATION AND TERMINOLOGY OF THE INTERNATIONAL LEAGUE AGAINST EPILEPSY: Proposal for revised clinical and electroencephalographic classification of epileptic seizures. *Epilepsia* 1981; 22: 489-501.
15. MUNOZ-RODRIGUEZ FJ, REVERTER CALATAYUD JC, FONT FRANCO J, ESPINOSA GARRIGA G, TASSIES PENELLA D, INGELMO MORIN M: Valvular heart disease in patients with anti-phospholipids syndrome. *Rev Clin Esp* 2002; 202: 529-33.
16. SCHVED JF, DUPUY-FONS C, BIRON C, QUERE I, JANBON C: A prospective epidemiological study on the occurrence of antiphospholipid antibody: the Montpellier Antiphospholipid Study. *Haemostasis* 1994; 24: 175-82.
17. HORBACH DA, VAN OORTE E, DONDEERS RC *et al.*: Lupus anticoagulant is the strongest risk factor for both venous and arterial thrombosis in patients with SLE – comparison between different assays for the detection of antiphospholipid antibodies. *Thromb Haemost* 1996; 76: 916-24.
18. FINAZZI G, BRANCACCIO V, MOIA M *et al.*: Natural history and risk factors for thrombosis in 360 patients with antiphospholipid antibodies. A four-year prospective study from the Italian Registry. *Am J Med* 1996; 100: 530-36.
19. YAMADA H, KATO EH, MORIKAWA M: Anticardiolipin beta2-glycoprotein 1 antibody: is a high titer related to unfavorable pregnancy outcome. *Semin Thromb Hemost* 2003; 29: 639-43.
20. WAHL DG, GUILLEMIN F, DE MAISTRE E, PERRET-GUILLEAUME C, LECOMPTE T, THIBAUT G: Metanalysis of the risk of venous thrombosis in individuals with antiphospholipid Antibodies without underlying autoimmune disease or previous thrombosis. *Lupus* 1998; 7: 15-22.
21. ZUCKERMAN E, TOUBI E, SHIRAN A *et al.*: Anticardiolipin antibodies and acute myocardial infarction in non-systemic lupus erythematosus patients: a controlled prospective study. *Am J Med* 1996; 101: 381-6.
22. VERES K, LAKOS G, KERENYI A: Antiphospholipid antibodies in acute coronary syndrome. *Lupus* 2004; 13: 423-7.
23. HOJNICK M, GEORGE J, ZIPOREN L, SHOENFELD Y: Heart valve involvement in the antiphospholipid syndrome. *Circulation* 1996; 93: 1574-87.
24. TEITJEN GE, GOTTWALD L, AL-QASMI MM, GUNDA P, KHUDER SA: Migraine is associated with livedo reticularis: a prospective study. *Headache* 2002; 42: 263-7.
25. SHOENFELD Y, LEV S, BLATT I *et al.*: Features associated with epilepsy in antiphospholipid syndrome. *J Rheumatol* 2004; 31: 1344-8.
26. LE TONQUIZE M, SALOZHINK K, DUEYMES M: Role of 2-GPI in the antiphospholipid antibody binding to endothelial cells. *Lupus* 1995; 4: 179-86.
27. RIBOLDI P, GEROSA M, RASCHI E, TESTINI C, MERONI PL: Endothelium as a target for antiphospholipid antibodies. *Immunobiology* 2003; 207: 29-36.
28. KHAMASHTA M, CUADRADO M, MUJIC F, TAUB N, HUNT B, HUGHES GRV: The management of thrombosis in the antiphospholipid-antibody syndrome. *N Eng J Med* 1995; 332: 993-7.