

# Anti-phosphatidylserine-prothrombin complex antibodies in patients with localized scleroderma

M. Hasegawa<sup>1</sup>, M. Fujimoto<sup>1</sup>, I. Hayakawa<sup>1</sup>, T. Matsushita<sup>1</sup>, C. Nishijima<sup>1</sup>,  
M. Yamazaki<sup>2</sup>, K. Takehara<sup>1</sup>, S. Sato<sup>3</sup>

<sup>1</sup>Department of Dermatology and <sup>2</sup>Department of Internal Medicine (III), Kanazawa University Graduate School of Medical Science, Kanazawa; <sup>3</sup>Department of Dermatology, Nagasaki University Graduate School of Biomedical Sciences, Nagasaki, Japan.

---

## Abstract Objective

Although some antiphospholipid antibodies (Abs) are found in patients with localized scleroderma (LSc), Ab against phosphatidylserine-prothrombin complex (PS/PT) has not been examined. We investigated anti-PS/PT Ab levels in patients with LSc.

---

## Methods

IgG anti-PS/PT Ab levels in serum samples taken from patients with LSc (n = 42) were measured using ELISA.

---

## Results

IgG anti-PS/PT Ab was detected in 17% of the LSc patients, while it was not detected in any normal controls (n = 32) or psoriasis vulgaris (n = 25), and this frequency was similar to that of systemic sclerosis (17%, n = 41). Among 3 LSc subgroups, generalized morphea, the severest form of LSc, had a frequency (27%) comparable with that of systemic lupus erythematosus (32%, n = 25). Among 7 LSc patients with anti-PS/PT Ab, 2 developed symptomatic thromboembolism (A 70-year-old man developed deep vein thrombosis and pulmonary infarction, although he was negative for other antiphospholipid Abs. A 6-year-old boy positive for lupus anticoagulant had cerebral infarction). By contrast, symptomatic thromboembolism was not detected in 35 LSc patients without anti-PS/PT Ab.

---

## Conclusion

Patients with LSc, especially generalized morphea, exhibit anti-PS/PT Ab at a frequency comparable with collagen diseases such as systemic sclerosis and systemic lupus erythematosus. Examination of this Ab may be useful to recognize the risk of thromboembolism in patients with LSc.

---

## Key words

Antiphospholipid antibody, localized scleroderma, thromboembolism.

Minoru Hasegawa, MD, PhD; Manabu Fujimoto, MD, PhD; Ikuko Hayakawa MD, PhD; Takashi Matsushita, MD; Chihiro Nishijima, MD, PhD; Masahide Yamazaki, MD, PhD; Kazuhiko Takehara, MD, PhD; Shinichi Sato, MD, PhD.

Please address correspondence and reprint requests to: M. Hasegawa, MD, PhD, Department of Dermatology, Kanazawa University Graduate School of Medical Science, 13-1 Takaramachi, Kanazawa, Ishikawa, 920-8641, Japan.  
E-mail: minoruha@derma.m.kanazawa-u.ac.jp

Received on February 25, 2005; accepted in revised form on September 1, 2005.

© Copyright CLINICAL AND EXPERIMENTAL RHEUMATOLOGY 2006.

## Introduction

Localized scleroderma (LSc) is a rare autoimmune disease limited to the skin and subcutaneous tissue beneath the cutaneous lesions. It differs from systemic sclerosis in that it lacks Raynaud's phenomenon, acrosclerosis, and internal organ involvement. Morphologically, LSc is classified into three variants: morphea, linear scleroderma, and generalized morphea (1). Morphea is characterized by one or a few discrete oval plaques with a firm ivory-colored center and a surrounding violaceous border. Linear scleroderma appears as a linear, bandlike distribution, and often involves the underlying muscle, and generalized morphea is a severe form of LSc characterized by widespread skin involvement with frequent muscle involvement. LSc, especially generalized morphea, is accompanied by various immunologic abnormalities, such as anti-nuclear antibody (Ab), anti-single-stranded (ss) DNA Ab, rheumatoid factor, and lupus erythematosus cell phenomenon (2-4). Furthermore, the major antigens recognized by anti-nuclear Ab are nuclear histones (especially H1, H2A, and H2B) (5, 6). Anti-phospholipid syndrome is diagnosed when vascular thrombosis or pregnancy morbidity is found in a patient with lupus anticoagulant and/or  $\beta_2$  glycoprotein I-dependent anti-cardiolipin (anti- $\beta_2$  GPI/CL) Ab (7, 8). Prothrombin is a possible another antigenic target of anti-phospholipid syndrome (9). Atsumi and Koike *et al.* suggested that anti-phosphatidylserine-prothrombin complex (anti-PS/PT) Ab rather than anti-prothrombin Ab alone is associated with symptoms of anti-phospholipid syndrome and lupus anticoagulant activity (10, 11). Recently, we showed that anti-cardiolipin Ab (46%) and lupus anticoagulant (24%) but not anti- $\beta_2$  GPI/CL Ab are present in LSc patients (12). In this study, we investigated whether anti-PS/PT Ab is present in patients with LSc, and whether this Ab is correlated with the clinical or serological features of this disease.

## Materials and methods

### Serum samples

Serum samples from 42 Japanese patients (31 women and 11 men, 4-70

years old, mean age of 27 years) with LSc were studied. No patients with LSc had other inflammatory, infectious or autoimmune diseases. Serum samples from 32 age- and gender-matched healthy volunteers (24 women and 8 men, 5-76 years old, mean age of 25 years) were examined. Twenty-five age- and gender-matched psoriasis vulgaris patients were assessed as a disease control of chronic skin inflammatory diseases. Age- and gender-matched patients with systemic sclerosis ( $n = 41$ ) or systemic lupus erythematosus ( $n = 25$ ) were examined as disease controls for systemic autoimmune diseases. The LSc patients were classified, as previously described (13), into the following three subgroups: (i) 15 patients with generalized morphea, (ii) 16 with linear scleroderma, (iii) 11 with morphea. None of the LSc patients were undergoing treatment with steroid or immunosuppressive therapy when the serum samples were obtained. The number of sclerotic lesions more than 3 cm in diameter was counted for each patient with LSc when the serum samples were obtained. The whole body was divided into seven areas: (i) head and neck, (ii) anterior trunk, (iii) posterior trunk, (iv) right upper extremity, (v) left upper extremity, (vi) right lower extremity, and (vii) left lower extremity. We defined the patients as having generalized morphea when they fulfilled the following two criteria: (i) four or more lesions were of more than 3 cm in diameter irrespective of whether they were linear or morphea, and (ii) involvement of two or more areas of the body. Patients who did not meet these criteria were diagnosed as having morphea or linear scleroderma according to their morphologic features. The experimental protocol was approved by the Kanazawa University Graduate School of Medical Science and Kanazawa University Hospital, and informed consent was obtained from all patients.

### Detection of antiphospholipid Ab

IgG anti-PS/PT Abs were measured with a specific enzyme-linked immunosorbent assay (ELISA, Medical & Biological Laboratories, Nagoya, Ja-

pan), according to the manufacturer's protocol. Briefly, the serum samples diluted to 1:101 were added to 96-well plates coated with PS/PT and incubated for 1 hour at 20°C. After washing, bound Abs were detected with peroxidase-conjugated anti-human IgG Ab. Colour was developed with 3, 3', 5, 5'-tetramethylbenzidine and H<sub>2</sub>O<sub>2</sub> and the plates were read at 450 nm. The detection limit was 5 U/ml and anti- $\beta_2$  GPI/CL Ab was measured using an ELISA kit (Yamasa, Tokyo, Japan). Lupus anticoagulant was determined according to the guidelines recommended by the Subcommittee on Lupus Anticoagulant/Phospholipid Dependent Abs (14).

#### Detection of Anti-nuclear Ab

Anti-nuclear Ab was detected by indirect immunofluorescence using HEp-2 cells as a substrate (5).

ELISA for anti-histone Ab was performed as previously described (5, 15). Briefly, microtiter plates (Corning, NY) were coated with 5 mg/ml total histones (Sigma, St. Louis, MO, USA) in phosphate-buffered saline. The plates were then post-coated with phosphate-buffered saline containing 3% bovine serum albumin. Serum samples diluted to 1:100 in phosphate-buffered saline-bovine serum albumin were added to each well. Bound Abs were then detected with alkaline phosphatase-conjugated goat anti-human IgG Ab (Cappel, Durham, NC, USA), and developed with 10 mg/ml *p*-nitrophenyl phosphate (Gibco BRL, Gaithersburg, MD, USA) in 10 mM diethanolamine and 0.5 mM MgCl<sub>2</sub> (pH 9.5) as a substrate. The plates were read at 405 nm, and absorbance values greater than the mean plus 3 SD for normal controls were considered positive.

To evaluate anti-ssDNA Ab, wells were pretreated for 1 hr with 0.1% protamine sulfate (grade X; Sigma). After rinsing, 1 mg/ml calf thymus ssDNA (Sigma) was added. ELISA was then performed as described above.

IgM rheumatoid factor was measured using a latex agglutination slide test (Eiken, Tokyo, Japan).

#### Statistical analysis

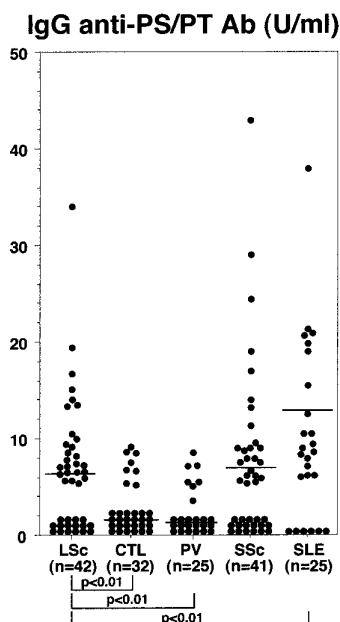
Statistical analysis was performed using

the Mann-Whitney U test for the comparison of Ab levels, Fisher's exact probability test for the comparison of frequencies, and Bonferroni's test for multiple comparisons were also used. A *p*-value of less than 0.05 was considered to be statistically significant. All data were shown as the mean  $\pm$  SD.

## Results

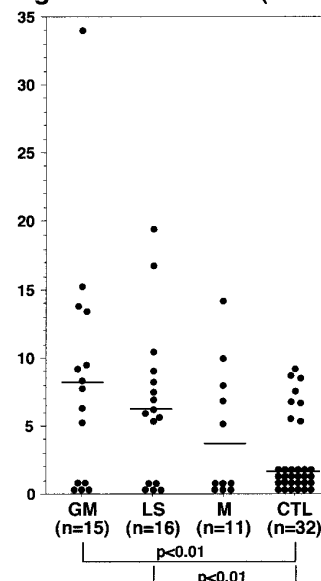
### Anti-PS/PT Ab levels in LSc

Patients with LSc exhibited mean IgG anti-PS/PT Ab levels ( $6.2 \pm 7.0$  U/ml) significantly higher than those for normal controls ( $2.0 \pm 3.2$  U/ml,  $p < 0.01$ ) or psoriasis vulgaris ( $1.6 \pm 2.8$  U/ml,  $p < 0.01$ , Fig. 1). The Ab levels were comparable with those of systemic sclerosis ( $7.0 \pm 10.9$  U/ml), although they were significantly lower than those for systemic lupus erythematosus ( $12.9 \pm 11.0$  U/ml,  $p < 0.01$ , Fig. 1). Among the LSc subgroups, patients with generalized morphea ( $8.2 \pm 9.0$  U/ml) and linear scleroderma ( $6.2 \pm 5.8$  U/ml) but not morphea ( $3.8 \pm 3.3$  U/ml) had significantly higher IgG anti-PS/PT Ab levels than normal controls ( $p < 0.01$ , Fig. 2).



**Fig. 1.** IgG Abs against PS/PT in serum samples from patients with localized scleroderma (LSc), normal controls (CTL), psoriasis vulgaris (PV), systemic sclerosis (SSc), and systemic lupus erythematosus (SLE). Anti-PS/PT Ab levels were determined by ELISA. The horizontal line shows the detection limit (5 U/ml) and the broken line represents the cut-off value (11.6 U/ml). The short bar indicates the mean value in each group.

### IgG anti-PS/PT Ab (U/ml)



**Fig. 2.** IgG anti-PS/PT Ab levels for 3 subgroups of localized scleroderma. Anti-PS/PT Ab levels expressed as a relative optical density (OD) were measured by ELISA in serum samples from patients with generalized morphea (GM), linear scleroderma (LS) or morphea (M) and normal controls (CTL). The horizontal line shows the detection limit (5 U/ml) and the broken line represents the cut-off value (11.6 U/ml). The short bar indicates the mean value for each group.

No significant difference in Ab levels was found for each LSc subgroup.

### Prevalence of anti-PS/PT Ab in LSc

Values higher than the mean + 3 SD (11.6 U/ml) of the normal control serum samples were considered to be positive. IgG anti-PS/PT Ab was found in 17% (7/42) of LSc, 17% (7/41) of systemic sclerosis, and 32% (8/25) of the systemic lupus erythematosus cases (Fig. 1). None of the normal controls or psoriasis vulgaris patients was positive for this Ab. Among the LSc subgroups, IgG anti-PS/PT Ab was detected in 27% with generalized morphea (4/15), 13% with linear scleroderma (2/16), and 9% with morphea (1/11, Fig. 2). Anti-nuclear Ab, anti-histone Ab, anti-ssDNA Ab, and rheumatoid factor were determined using the same serum samples that were assessed for anti-PS/PT Ab. Anti-nuclear Ab was more frequently detected in patients with anti-PS/PT Ab than those without it (Table I). Patients with positive anti-PS/PT Ab exhibited significantly higher levels of

IgG anti-histone Ab and IgG anti-ssDNA Ab than those without IgG anti-PS/PT Abs. Patients positive for anti-PS/PT Ab had increased number of linear and/or plaque lesions, number of affected body areas, or frequency of muscle involvement compared with those negative for the Ab, although they were not significant.

#### LSc patients with antiphospholipid Ab

Table II demonstrates LSc patients positive for anti-PS/PT Ab and/or lupus anticoagulant. Out of 42 LSc patients who were assessed for anti-PS/PT Ab, lupus anticoagulant activity was determined in 22 patients with LSc whose plasma samples were available. Anti-CL/ $\beta_2$ GPI Ab were examined in sera from all LSc patients. Although lupus anticoagulant was detected in 5 patients (23%), anti-CL/ $\beta_2$ GPI Ab was not detected in any LSc patients. Among 7 SSc patients with anti-PS/PT Abs, 3 patients had lupus anticoagulant and 2 patients were negative for lupus anticoagulant. Two patients had lupus anticoagulant among LSc patients without anti-PS/PT Ab. The titer of anti-PS/PT Ab was higher in LSc patients with lupus anticoagulant ( $n = 5$ ) than those without lupus anticoagulant ( $n = 17$ ,  $8.0 \pm 10.8$  vs.  $4.1 \pm 4.3$  U/ml), although the difference was not statistically significant.

#### Thromboembolism in LSc patients

Out of 42 LSc patients, two cases positive for anti-PS/PT Ab had symptomatic episodes of thrombosis.

**Case 1.** A 68 year-old Japanese man with no personal or family history of connective tissue disease presented with a 2-month history of total 4-well circumscribed brown to erythematous indurated plaques on the bilateral lower legs. A skin biopsy from the right lower leg showed collagen deposition in the dermis and subcutis. Thickening of the fascia or inflammatory cell infiltration of the fascia was not observed. He denied any associated pulmonary or gastrointestinal complaints or Raynaud's phenomenon, so, his condition was diagnosed as generalized morphea. Two years after the first examination (age 70), he presented with a 2-week history

**Table I.** Clinical and serological features of patients with localized scleroderma positive for IgG anti-PS/PT Ab.

	IgG anti-PS/PT Ab + (n = 7)	IgG anti-PS/PT Ab - (n = 35)
<b>Serological</b>		
Anti-nuclear Ab	5 (71) <sup>a*</sup>	6 (17)
IgG anti-histone Ab (OD)	$1.59 \pm 0.58^b$	$0.98 \pm 0.51$
IgG anti-ssDNA Ab (OD)	$0.79 \pm 0.69^*$	$0.40 \pm 0.50$
Rheumatoid factor	2 (29)	7 (19)
<b>Clinical</b>		
Sex (male/female)	2/5	13/22
Age at onset (years)	$24 \pm 24$	$18 \pm 16$
Disease duration (years)	$5.2 \pm 3.3$	$4.6 \pm 1.2$
No. of linear lesions	$1.4 \pm 0.9$	$0.8 \pm 0.9$
No. of plaque lesions	$4.4 \pm 3.3$	$2.3 \pm 2.7$
Total no. of lesions	$5.1 \pm 3.6$	$3.3 \pm 2.9$
No. of involved body areas	$2.8 \pm 1.7$	$2.1 \pm 1.7$
Muscle involvement	2 (29)	6 (17)

Unless otherwise indicated, <sup>a</sup> values are the number (%) of positive patients or <sup>b</sup> mean SD.

IgG Ab levels against PS/PT were examined by specific ELISA. Values higher than 11.6 U/ml were considered to be positive. IgG Abs against histone or ssDNA and rheumatoid factor as the relative optical density (OD) were determined by specific ELISA. \* $p < 0.01$ , versus patients without IgG anti-PS/PT Ab.

**Table II.** Anti-phospholipid Abs in patients with localized scleroderma.

Patient no.	Age	Sex	Symptomatic thrombosis	Anti-PS/PT Ab (U/ml)	Lupus anticoagulant	Anti-CL/ $\beta_2$ GPI Ab
1	6	M	+ (Brain)	+ (34)	+	-
2	33	F	-	+ (19.5)	+	-
3	50	F	-	+ (16.8)	ND	-
4	26	F	-	+ (15.2)	-	-
5	11	F	-	+ (13.8)	+	-
6	68	M	+ (Deep vein+Lung)	+ (13.4)	-	-
7	20	F	-	+ (13.2)	ND	-
8	29	M	-	- (7.8)	+	-
9	15	M	-	- (5.4)	+	-

anti- $\beta_2$  GPI/CL Ab;  $\beta_2$  glycoprotein I-dependent anti-cardiolipin Ab; ND, not done.

of swelling of the left lower leg. At this time, his total leukocyte count, hemoglobin, and platelet number were normal. The thrombin-antithrombin III complex value ( $4.4 \mu\text{g/L}$ ) was elevated, suggesting a hypercoagulable state. Rheumatoid factor was positive, although Abs against nuclear antigens, centromere, topoisomerase I, U1-RNP, Sm, SS-A, SS-B, ssDNA, and double-stranded (ds) DNA were negative with normal serum IgG, IgA, and IgM levels. Lupus anticoagulant and anti- $\beta_2$  GPI/CL Ab were negative and values of prothrombin time, activated partial thromboplastin time, antithrombin III, protein S, protein C, and each coagulation factor were normal. Radioactive isotope-venography and pulmonary perfusion/ventilation scintigraphy showed

that the patient had deep vein thrombosis of the left lower leg and small pulmonary infarction of the left upper lung. Although the cause of the thromboembolism was unknown, we detected anti-PS/PT Ab in the current study ( $13.4 \text{ U/ml}$ ). Therefore, there was a possibility that the thromboembolism was induced by anti-PS/PT Ab.

**Case 2.** A 6 year-old Japanese boy with no personal or family history of connective tissue disease presented with an 11-month history of multiple circumscribed indurated or sclerotic plaques on the neck, trunk, and bilateral lower legs. He had a restricted right ankle, bilateral knee and bilateral hip joints due to multiple sclerotic skin lesions. He denied any associated pulmonary or gastrointestinal complaints or Ray-

naud's phenomenon. At this time, his total leukocyte count, hemoglobin, and platelet number were normal, and rheumatoid factor and anti-nuclear Ab (1:640, homogeneous pattern) were positive. Although Abs against centromere, topoisomerase I, U1 RNP, Sm, and dsDNA were negative, anti-ssDNA Ab was elevated (470 U/ml, normal < 20 U/ml). Levels of serum IgG, IgA, IgM, and complement were normal. Values for prothrombin time, activated partial thromboplastin time, prothrombin fragment<sub>1+2</sub>, antithrombin III, protein S, protein C, and each coagulation factor were also normal. Lupus anticoagulant were positive and anti- $\beta_2$  GPI/CL Ab was negative. A symptomatic infarction of the right front-temporal lesion was detected by brain MRI. We diagnosed him as having generalized morphea with antiphospholipid syndrome. In addition, we detected elevated anti-PS/PT Ab levels (34 U/ml) in this case.

## Discussion

Although LSc is an autoimmune disease limited to the skin and subcutaneous skin tissues, the frequency of IgG anti-PS/PT Ab of generalized morphea (27%) was comparable with that of systemic lupus erythematosus (32%, Figs. 1 and 2). Autoimmunity plays a role in the induction of LSc since it, especially generalized morphea, is accompanied by various autoAbs including anti-ssDNA Ab, anti-histone Ab, and anti-topoisomerase II Ab (2-5, 16). We hypothesized that anti-nucleosome Ab is driven by native nucleosomes acting as immunoantigens in most LSc patients (17). Furthermore, anti-histone Ab in addition to anti-nucleosome Ab was observed in severe LSc patients such as those with generalized morphea, probably due to spreading of the autoimmune response from the native nucleosome to its individual components (DNA and histones) (17). Immune responses to autoantigens are likely induced by cryptic self-epitopes generated by the modification of self-antigens during apoptosis. Apoptosis can be detected in endothelial cells of early inflammatory lesions from LSc patients (18). Therefore, autoAbs against ssDNA and histone may be pro-

duced as a result by modification of these nuclear antigens during endothelial apoptosis in LSc. Since anti-PS/PT Ab was significantly associated with anti-ssDNA Ab or anti-histone Ab (Table II), these autoAbs may be derived from similar immunological abnormalities. Anionic phospholipids, such as phosphatidylserine and cardiolipin, which are not normally expressed on the surface of viable cells, are translocated to the surface of the plasma membrane of cells during apoptosis (19). Recent studies showed that prothrombin or  $\beta_2$  GPI binds specifically to the surface of apoptotic and not viable Jurkat cells (20, 21). Since  $\beta_2$  GPI that combines in apoptotic cells is immunogenic and can induce anti- $\beta_2$  GPI/CL Ab (22), we suppose that prothrombin bound to apoptotic endothelial cells is also immunogenic and causes anti-PS/PT Ab production in LSc.

Previously, some cases of LSc with antiphospholipid Ab have been reported (23, 24). We recently showed that anti-cardiolipin Ab (IgG or IgM) and lupus anticoagulant are frequently detected in LSc patients (46% and 24%, respectively), although anti- $\beta_2$  GPI Ab is not detected in LSc patients (12). In the present study, symptomatic thromboembolism was detected in 2 patients with generalized morphea among 7 LSc patients with anti-PS/PT Ab. By contrast, no patients had symptomatic thromboembolism in 35 LSc patients without anti-PS/PT Ab. Since the first case had not been positive for lupus anticoagulant or anti  $\beta_2$  GPI/CL Ab, the cause of the thrombosis was not identified before this study. Although Abs against PS/PT and/or  $\beta_2$  GPI/CL are major components of lupus anticoagulant, thromboembolism is present in some patients with anti-PS/PT Ab but not lupus anticoagulant and anti- $\beta_2$  GPI/CL Ab (10). Therefore, it may be useful to evaluate anti-PS/PT Ab when screening for antiphospholipid Ab in LSc patients, especially when they do not fulfill the criteria of antiphospholipid syndrome (8). In the second case, cerebral infarction occurred in a boy with generalized morphea. Congenital thrombotic disease was denied by his laboratory data. He showed elevated

anti-PS/PT Ab levels that were the highest of all the LSc patients. Lupus anticoagulant was positive and anti- $\beta_2$  GPI/CL Ab was negative in this patient. Anti-PS/PT Ab exhibits lupus anticoagulant activity and is closely associated with lupus anticoagulant (10, 25). Therefore, anti-PS/PT Ab may be a major component of lupus anticoagulant activity in this case.

The mean age of patients with antiphospholipid syndrome was 42 years, and only 2.8% of all patients in a large study of European Phospholipid Project Group developed anti-phospholipid syndrome before age 18 (26). Since LSc occurs frequently in infantile, the mean age was 27 in our LSc patients. Therefore, the younger age of these patients may be one reason why the prevalence of antiphospholipid syndrome is not a high in spite of high frequency of antiphospholipid Ab in LSc. However, we could not screen all patients for thromboembolism. Therefore, we cannot exclude the possibility that asymptomatic antiphospholipid syndrome occurs at a high frequency. We previously reported on a patient with generalized morphea who exhibited lupus anticoagulant and anti-cardiolipin Ab (12). In that case, asymptomatic pulmonary infarction was detected by screening his clinical signs for antiphospholipid syndrome. Careful observation and follow-up for thrombosis may be required for LSc patients with antiphospholipid Ab even if they do not exhibit symptomatic thromboembolism.

Finally, this ELISA results are reliable since some previous reports demonstrated the reproducibility and the utility of the ELISA kit (27-29). Anti-PS/PT Ab was detected in 67% of patients with antiphospholipid syndrome (28). Among SLE or lupus-like disease patients, anti-PS/PT Ab was detected more frequently in patients with antiphospholipid syndrome than in patients without the syndrome (44% vs. 14%,  $p < 0.005$ ) (29). Thereby, the present study demonstrated that anti-PS/PT Ab is a novel autoAb detected in patients with LSc. Although LSc is a rare disease, further investigation especially in a large patient group will be needed to

clarify the clinical relevance of this Ab in LSc.

## Acknowledgements

We thank Ms M. Matsubara for her technical assistance.

## References

1. TUFFANELLI DL, WINKELMANN RK: Systemic scleroderma. *Arch Dermatol* 1961; 84: 359-71.
2. TAKEHARA K, MOROI Y, NAKABAYASHI Y, ISHIBASHI Y: Antinuclear antibodies in localized scleroderma. *Arthritis Rheum* 1983; 26: 612-6.
3. FALANGA V, MEDSGER TA JR, REICHLIN M, RODNAN GP: Linear scleroderma. Clinical spectrum, prognosis, and laboratory abnormalities. *Ann Intern Med* 1986; 104: 849-57.
4. TAKEHARA K, KIKUCHI K, SOMA Y, IGARASHI A, ISHIBASHI Y: Anti-single-stranded DNA antibody and muscle involvement in localized scleroderma. *Arch Dermatol* 1990; 126: 1368.
5. SATO S, IHN H, SOMA Y *et al.*: Antihistone antibodies in patients with localized scleroderma. *Arthritis Rheum* 1993; 36: 1137-41.
6. SATO S, FUJIMOTO M, IHN H, KIKUCHI K, TAKEHARA K: Antigen specificity of antihistone antibodies in localized scleroderma. *Arch Dermatol* 1994; 130: 1273-7.
7. HARRIS EN, CHAN JK, ASHERSON RA, ABER VR, GHARAVI AE, HUGHES GR: Thrombosis, recurrent fetal loss, and thrombocytopenia. Predictive value of the anticardiolipin antibody test. *Arch Intern Med* 1986; 146: 2153-6.
8. WILSON WA, GHARAVI AE, KOIKE T *et al.*: International consensus statement on preliminary classification criteria for definite antiphospholipid syndrome: report of an international workshop. *Arthritis Rheum* 1999; 42: 1309-11.
9. GALLI M, LUCIANI D, BERTOLINI G, BARBUI T: Anti-beta 2-glycoprotein I, antiprothrombin antibodies, and the risk of thrombosis in the antiphospholipid syndrome. *Blood* 2003; 102: 2717-23.
10. ATSUMI T, IEKO M, BERTOLACCINI ML *et al.*: Association of autoantibodies against the phosphatidylserine-prothrombin complex with manifestations of the antiphospholipid syndrome and with the presence of lupus anticoagulant. *Arthritis Rheum* 2000; 43: 1982-93.
11. AMENGUAL O, ATSUMI T, KOIKE T: Specificities, properties, and clinical significance of antiprothrombin antibodies. *Arthritis Rheum* 2003; 48: 886-95.
12. SATO S, FUJIMOTO M, HASEGAWA M, TAKEHARA K: Antiphospholipid antibody in localized scleroderma. *Ann Rheum Dis* 2003; 62: 771-4.
13. SATO S, FUJIMOTO M, IHN H, KIKUCHI K, TAKEHARA K: Clinical characteristics associated with antihistone antibodies in patients with localized scleroderma. *J Am Acad Dermatol* 1994; 31: 567-71.
14. BRANDT JT, TRIPLETT DA, ALVING B, SCHARRER I: Criteria for the diagnosis of lupus anticoagulants: an update. On behalf of the Subcommittee on Lupus Anticoagulant/Antiphospholipid Antibody of the Scientific and Standardisation Committee of the ISTH. *Thromb Haemost* 1995; 74: 1185-90.
15. SATO S, IHN H, KIKUCHI K, TAKEHARA K: Antihistone antibodies in systemic sclerosis: association with pulmonary fibrosis. *Arthritis Rheum* 1994; 37: 391-4.
16. HAYAKAWA I, HASEGAWA M, TAKEHARA K, SATO S: Anti-DNA topoisomerase IIalpha autoantibodies in localized scleroderma. *Arthritis Rheum* 2004; 50: 227-32.
17. SATO S KM, HASEGAWA M, FUJIMOTO M, TAKAHARA K: Anti-nucleosome antibody is a major autoantibody in localized scleroderma. *Br J Dermatol* 2004; in press.
18. SGONC R, GRUSCHWITZ MS, DIETRICH H, RECHEIS H, ERIC GRESHWIN M, WICK G: Endothelial cell apoptosis is a primary pathogenic event underlying skin lesions in avian and human scleroderma. *J Clin Invest* 1996; 98: 785-92.
19. RUDEL T, BOKOCH GM: Membrane and morphological changes in apoptotic cells regulated by caspase-mediated activation of PAK2. *Science* 1997; 276: 1571-4.
20. D'AGNILLO P, LEVINE JS, SUBANG R, RAUCH J: Prothrombin binds to the surface of apoptotic, but not viable, cells and serves as a target of lupus anticoagulant autoantibodies. *J Immunol* 2003; 170: 3408-22.
21. PRICE BE, RAUCH J, SHIA MA *et al.*: Antiphospholipid autoantibodies bind to apoptotic, but not viable, thymocytes in a beta 2-glycoprotein I-dependent manner. *J Immunol* 1996; 157: 2201-8.
22. LEVINE JS, SUBANG R, KOH JS, RAUCH J: Induction of anti-phospholipid autoantibodies by beta2-glycoprotein I bound to apoptotic thymocytes. *J Autoimmun* 1998; 11: 413-24.
23. FREEMAN WE, LESHER JR JL, SMITH JR JG: Connective tissue disease associated with sclerodermoid features, early abortion, and circulating anticoagulant. *J Am Acad Dermatol* 1988; 19: 932-6.
24. CASTANET J, LACOUR J PH, PERRIN C, TAILLAN B, DUBOIS D, ORTONNE JP: Association of eosinophilic fasciitis, multiple morphea and antiphospholipid antibody. *Dermatology* 1994; 189: 304-7.
25. FLECK RA, RAPAPORT SI, RAO LV: Antiprothrombin antibodies and the lupus anticoagulant. *Blood* 1988; 72: 512-9.
26. CERVERA R, PIETTE JC, FONT J *et al.*: Antiphospholipid syndrome: clinical and immunologic manifestations and patterns of disease expression in a cohort of 1,000 patients. *Arthritis Rheum* 2002; 46: 1019-27.
27. KABURAKI J, KUWANA M, UEHARA R *et al.*: Development of ELISA kit to examine anti-phosphatidylserine/prothrombin complex antibodies. *Jpn J Med Pharmaceutical Sci* 2002; 47: 813-9.
28. KABURAKI J, KUWANA M, IKEDA Y: Clinical significance of anti-phosphatidylserine-prothrombin complex antibodies in the diagnosis of anti-phospholipid syndrome. *Jpn J Clin Hematol* 2003; 44: 28-30.
29. KABURAKI J, KUWANA M, KAMEDA H *et al.*: Clinical significance of anti-phosphatidylserine-prothrombin complex antibodies in antiphospholipid syndrome. *Jpn J Clin Hematol* 2005; 46: 19-21.