

## Back pain and condensation of the eighth thoracic vertebra: Is it always a metastatic disease?

G.A.W. Bruyn,  
P.R. Tondu

George A.W. Bruyn, MD, PhD, Department of Rheumatology and Philippe R. Tondu, MD, Department of Radiology, Medisch Centrum Leeuwarden, 8934 AD Leeuwarden, The Netherlands.

Please address correspondence to:  
George A.W. Bruyn, MD, PhD.  
E-mail: gawbruyn@wxs.nl

Received on January 10, 2005; accepted in revised form on October 6, 2005.

© Copyright CLINICAL AND EXPERIMENTAL RHEUMATOLOGY 2006.

### ABSTRACT

The case of a 55-year-old female patient with discogenic sclerosis of a thoracic vertebra is illuminated by a radiologic vignette. The clinical and radiologic features, including those of conventional radiography, computed tomography scanning and magnetic resonance imaging are hallmarked in this portrait. The importance of differentiating the condition particularly from infectious spondylodiscitis and metastatic disease to the spine is underpinned.

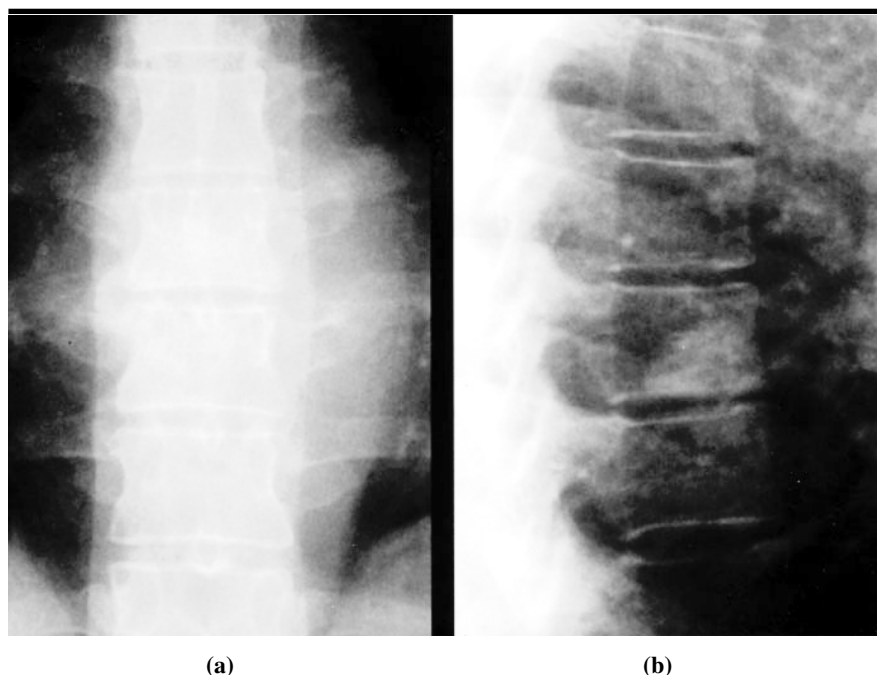
### Case history

A 55-yr-old woman was referred with chronic back pain and fatigue. There was no history of morning stiffness, fever, weight loss or general malaise. The back pain was located in the lower half of the spine and had started 2 years before. There was also pain at night. No radiation of the pain to the lower extremities was present. A visual analogue scale on pain was 71/100 mm. At physical examination, blood pressure was 170/90 mmHg, pulse rate 87/minute and temperature was 37.4 °C. There was no lymphadenopathy or hepatosplenomegaly. Examination of upper and lower extremities revealed changes of the joints of the hands and

knees compatible with osteoarthritis. Percussion of the spine revealed diffuse tenderness of the lumbar vertebrae. No exacerbation of the pain was induced by anteflexion, lateroflexion or retroflexion of the spine. A mild thoracic kyphosis was present. A modified Schober's test for lumbar spine mobility showed a normal increase. Neurologic examination revealed normal reflexes and no weakness or sensory deficits. Laboratory examination showed an erythrocyte sedimentation rate (ESR) of 20 mm first hour, CRP 12 mg per liter (<10), normal hemoglobin value, normal white blood cell (WBC) and platelet count, and normal liver and kidney function. The total protein level was normal, as were the serum calcium, phosphate, alkaline phosphatase, vitamin D, thyroid function tests, and glucose levels. Rheumatoid factor and antinuclear antibody testing was negative.

### Radiologic findings

Chest radiograph demonstrated no abnormalities of the heart and lungs. An ultrasound examination of the abdomen did not show any masses or aortic dilatation. A technetium 99m nuclear bone scan showed increased tracer uptake in T6, T7, T8, and T9. Con-



**Fig. 1.** (a) Anterior-posterior radiograph of the thoracic spine shows sclerosis of vertebral body T8. (b) The sclerosis is better visible on the lateral spine radiograph.

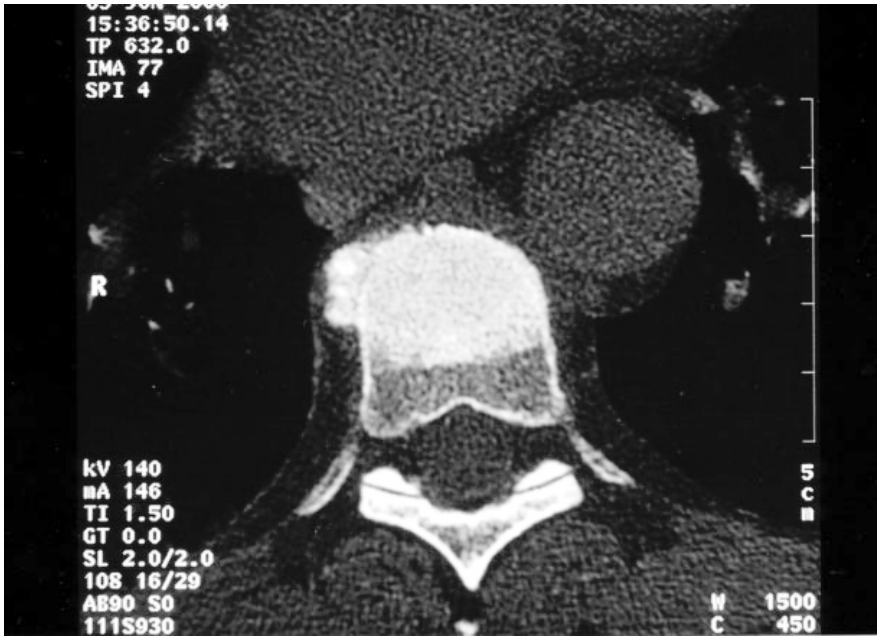

Fig. 2. Axial CT section demonstrates the sclerotic lesion of the anterior vertebral body of T8.

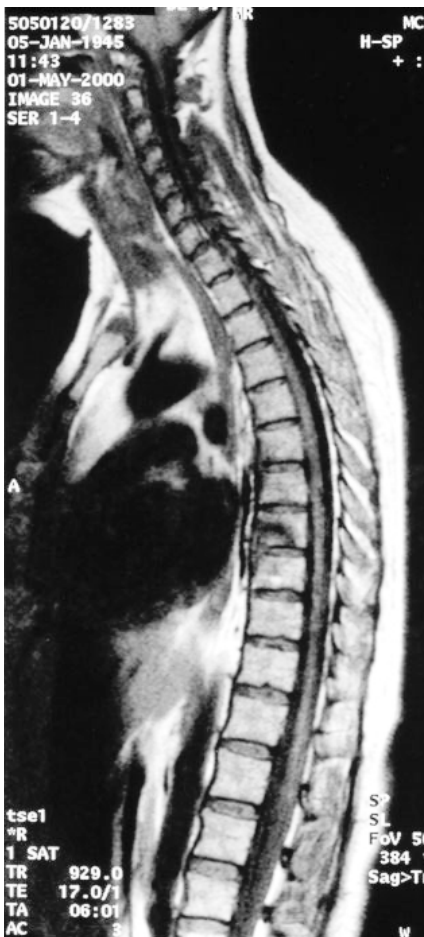

Fig. 3. Sagittal T1 weighted MR image demonstrates the isointensity of the central lesion and a low signal of the peripheral rim, no signs of osteolysis of the adjacent endplates and no widening of the disc space.

tional radiographs of the thoracic spine showed an ill-defined, anterior hemispherical sclerotic area of the 8th thoracic vertebra adjacent to the inferior end plate accompanied by small spondylophytes, with ventral disc-space narrowing (Fig. 1). The osseous boundaries were well demarcated. Axial 2

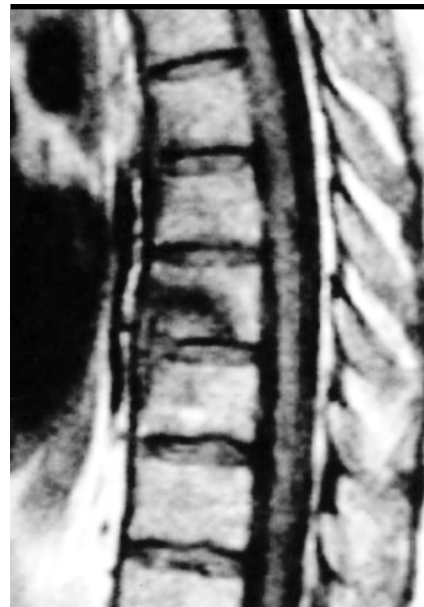

Fig. 4. A sagittal contrast-enhanced T1 weighted MR image shows the low signal of the peripheral rim.

mm computed tomographic (CT) scan images of the thoracic levels 7 to 9 showed a well-defined area of sclerosis covering more than half of the eight thoracic vertebra and a right-sided spur (Fig. 2). Magnetic resonance imaging (MRI) showed an well-defined lesion of the anterior and inferior aspect of the eighth thoracic vertebral body. This lesion showed a central isointensity on both T1-weighted (Figs. 3, 4) and T2-weighted images (Fig. 5) with a low signal peripheral rim on both sequences. There was a semicircular enhancement of the sclerotic margin after gadolinium diethylenetriamine-pentaacetic acid (DTPA) administration. Adjacent to the sclerotic lesion of the vertebra, a ventral disc-space narrowing of T8-9 was present. The T2 abnormality extended into the anterior disc and the adjacent anterior T9 endplate (Fig. 5). There was no abnormality of vertebral contour or soft-tissue abnormalities.

**Differential diagnosis**

The diagnosis was discogenic sclerosis of T8. Discogenic vertebral sclerosis must be differentiated from malignant neoplastic disease of the spine, especially in patients older than the age of

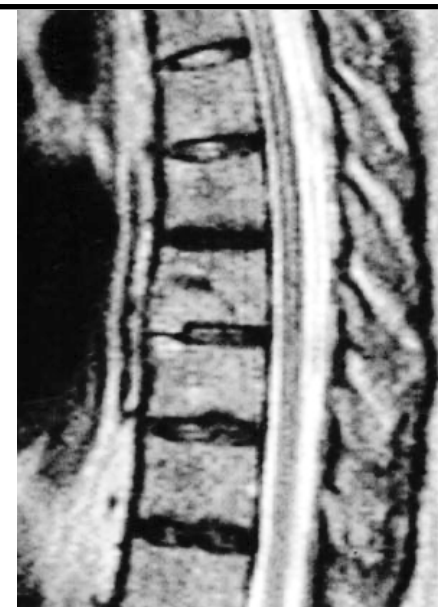

Fig. 5. A sagittal contrast-enhanced T2 weighted MR image demonstrates decreased semicircular signal within the T8 vertebral body. Anterior osteophytes of the vertebral bodies of T8 and T9 are clearly visible, with accompanying narrowing disc space.

40. The most common malignant disease is metastatic disease to the spine, of which the blastic lesions may give rise to so-called "ivory" vertebra on radiographs (1). Carcinomas that cause almost exclusively sclerotic metastases are those of the prostate, bronchial carcinoid tumor, bladder carcinoma involving the prostate, carcinomas of nasopharynx and stomach, and medulloblastoma and neuroblastoma. The bone involvement by lymphoma may be sclerotic (2,3), whereas the lesions of multiple myeloma are invariably lytic, with the exception of the POEMS syndrome (4,5). Standard imaging of metastatic disease starts with a nuclear bone scan, which has a high sensitivity for foci of increased bone turnover, but a low specificity. In metastatic disease, however, it usually shows multiple lesions, making recognition of the disorder easy. Radiographs, CT scanning and MR imaging are all indicated for the characterization of possible malignant bone lesions; the latter two are able to define the borders of the lesion and evaluate possible extension into the paravertebral spaces or the spinal canal.

Acute irregularity of the disc space, sclerosis of two adjacent vertebral bodies, and irregular vertebral end plates constitute a radiographic complex classically associated with infectious spondylitis and discitis. MR features of disc infection include disc enhancement with contrast as a primary finding. Other MR findings include high T2 signal, the presence of epidural or paravertebral enhancement of soft tissue, marrow oedema and osteomyelitis. Special attention should be paid to atypical infections like tuberculosis and fungal infections. Generally, tuberculosis causes no or little disc space changes, but tends to extend along the perivertebral tissues and spinal ligaments. Radiographs, CT and MR imaging all demonstrate the mild changes of disc space together with sclerosis of adjacent vertebral bodies; MR imaging may show the foci of bone marrow involvement and the soft tissue abnormalities (6).

Chronic narrowing of the disc space may be seen as the result of a degener-

ative disc disease, ankylosing spondylitis with a fracture sustained through the disc and posterior elements (7), dialysis spondylarthropathy and the rare neuropathic condition of the spine seen in paraplegics. The Schmorl's nodes of Scheuermann's disease, i.e., intrabody cartilaginous node formation, is a differential diagnostic consideration in younger patients. Lumbar localization of Scheuermann's disease is more painful than the thoracic counterpart (8). Paget's disease may also be a cause of sclerotic changes of vertebrae. Miscellaneous causes of sclerotic vertebral lesions are osteopetrosis, chronic osteomyelitis, dense bone islands, necrosis of caisson disease, radiation osteitis, renal osteodystrophy, and sarcoidosis.

### Discussion

In 1958, Ackerman and Schwartz were the first to report sclerotic changes of vertebrae in a series of 28 patients, 13 of which were non-malignant (9). A specific etiology could not be found. Subsequently, many authors have postulated an infectious etiology, although none was able to underpin this theory with microbiologic cultures (10-14). Previous trauma or degenerative changes of the intervertebral disc have also been mentioned as possible causes, yet the lesion may also appear in young adults, with an age range of 16-80 years. Histological examination of biopsy material usually reveals nonspecific findings, i.e., slightly thickened trabeculae with evidence of appositional bone formation and extensive remodeling, compatible with reactive sclerosis. The bone marrow may be slightly hyperplastic or fibrotic. No evidence of current or past osteoclastic activity or the typical mosaic pattern of Paget's disease have been found. Cultures of the biopsy material are sterile and no evidence of mycobacterial infection has been found (14).

Typical radiographic features of discogenic vertebral sclerosis include an ill-defined, hemispherical or bandform sclerotic lesion of the anterior third of a vertebral body, typically lumbar L4, L5 or S1. Other vertebrae, however, are not excluded. A narrowed disc space is almost invariably present. In some

series cases an associated erosion of the end plate, i.e., a Schmorl's node, is present. In some series, the sclerosis made up a very significant part of the vertebral body, i.e., the entire body or the anterior two-thirds (15). An accompanying spur may point to degenerative changes.

In the active phase, a nuclear bone scan demonstrates increased bone turnover, making the distinction with infection impossible. Similarly, MR imaging will detect bone marrow oedema in the early phase of degenerative disc disease. T1 sequences will demonstrate low signal and T2-weighted images will have increased signal. These changes have been described by Modic and are called Modic 1 type changes (16). MR imaging in this condition is extremely valuable because of the T1 and T2-weighted images appearances of discogenic vertebral sclerosis (Figs. 3-5). The lesion in our patient can be classified as a Modic type 1 change.

Differentiating the condition from infectious spondylodiscitis is important. In spondylodiscitis, the clinical features help to differentiate the disorder from discogenic vertebral sclerosis. The absence of fever, the relatively normal erythrocyte sedimentation rate and the normal white blood cell count are all helpful in making the right diagnosis. In addition, a paravertebral mass, distorted disc with an abnormal configuration, and no differentiation of the disc from the vertebral endplate are seen on MRI in infectious spondylodiscitis (17). Relative preservation of the disc may be an feature of tuberculous spondylodiscitis (17).

Metastatic bone involvement is another important differential consideration. Few carcinomas, e.g. prostate cancer, exclusively produce sclerotic metastases of the skeleton. Most carcinomas cause mixed sclerotic and lytic metastases and others cause exclusively lytic lesions. Malignant disease was carefully ruled out in our patient.

Careful examination of the radiologic series and comparison with older examinations help to distinguish the discogenic vertebral sclerosis from these important differential diagnostic considerations, i.e., the "ivory" lesions of me-

tastatic disease and Hodgkin's disease. Radiologic recognition of discogenic vertebral sclerosis obviates the necessity for further evaluation and biopsy.

### References

1. DREVELEGAS A, CHOURMOUZI G, BOULOGIANNI G *et al.*: Imaging of primary bone tumors of spine. *Eur Radiol* 2003; 13: 1859-71.
2. KIM HJ, RYU KN, CHOI WS *et al.*: Spinal involvement of hematopoietic malignancies and metastasis: differentiation using MR imaging. *Clin Imaging* 1999; 23: 125-33.
3. GUERMAZI A, BRIZE P, DE KERVILER EE *et al.*: Extranodal Hodgkin disease: spectrum of disease. *Radiographics* 2001; 21: 161-79.
4. GAXATTE C, GUILLERM G *et al.*: Multiple myeloma presenting with widespread osteosclerotic lesions. *Joint Bone Spine* 2004; 71: 79-83.
5. SINGH D, WADHWA J, KUMAR L *et al.*: EMS syndrome: experience with fourteen cases. *Leuk Lymphoma* 2003; 44: 1749-52.
6. FORRESTER DM: Infectious spondylitis. *Seminars Ultrasound CT MRI* 2004; 25: 461-73.
7. CAWLEY MID, CHALMERS TM, KELLGREN JH, BALL J: Destructive lesions of vertebral bodies in ankylosing spondylitis. *Ann Rheum Dis* 1972; 31: 345-58.
8. WENGER DR, FRICK SL: Scheuermann kyphosis. *Spine* 1999; 24: 2630-9.
9. ACKERMANN W, SCHWARTZ GS: Non-neoplastic sclerosis in vertebral bodies. *Cancer* 1958; 11: 703-8.
10. WILLIAMS JL, MOLLER GA, O'ROURKE TL: Pseudo-infections of the intervertebral disc and adjacent vertebrae? *Am J Roentgenol Radium Ther Nucl Med* 1968; 103: 611-5.
11. POPE TL, WANG G, WHITEHILL R: Discogenic vertebral sclerosis: a potential mimic of disc space infection or metastatic disease. *Orthopedics* 1990; 13: 1389-97.
12. RUSSELL AS, PERCY JS, LENTLE BC: Vertebral sclerosis in adults. *Ann Rheum Dis* 1979; 38: 18-22.
13. MCCARTHY EF, DORFMAN HD: Idiopathic segmental sclerosis of vertebral bodies. *Skeletal Radiol* 1982; 9: 88-91.
14. SAUSER DD, GOLDMAN AB, KAYE JJ: Discogenic vertebral sclerosis. *J Can Assoc Radiol* 1978; 29: 44-50.
15. DIHLMANN SW, EISENSCHENK A, MAYER HM, WEBER U: The "mirror image" and "two-thirds" types of hemispherical spondylosclerosis. *Eur Spine J* 1995; 4: 110-3.
16. MODIC MT, STEINBERG PM, ROSS JS, MASARYK TJ, CARTER JR: Degenerative disk disease: assessment of changes in vertebral body marrow with MR imaging. *Radiology* 1988; 166: 193-9.
17. MAIURI F, IACONETTA G, GALLICCHIO B, MANTO A, BRIGANTI F: Spondylodiscitis: clinical and magnetic resonance diagnosis. *Spine* 1997; 22: 1741-6.