

Charcot-like arthropathy: A newly-recognized subset of psoriatic arthritis

L. Candia¹, M.L. Cuellar²,
S.M. Marlowe¹, J. Marquez¹,
A. Iglesias³, L.R. Espinoza¹

¹Department of Medicine, Section of Rheumatology, Louisiana State University Health Sciences Center¹, Tulane University Medical Center, New Orleans, LA, USA; San Juan de Dios Hospital, National University of Colombia, Santa Fe de Bogota, Colombia³.

Liliana Candia, MD; Marta L. Cuellar, MD; Sally M. Marlowe, NP; Javier Marquez, MD; Antonio Iglesias, MD; Luis R. Espinoza, MD.

Drs. Candia and Marquez are post-doctoral research fellows at the Rheumatology Section, LSU Health Sciences Center at New Orleans, LA, USA. Presented in part at the 60th annual meeting of the American College of Rheumatology, Orlando, Florida, USA, 1996.

Please address correspondence and reprint requests to: L.R. Espinoza, M.D. LSU Medical Center, 1542 Tulane Avenue, New Orleans, LA 70112-2822, USA. E-mail: luisrolan@msn.com

Received on April 18, 2005; accepted in revised form on January 25, 2006.

© Copyright CLINICAL AND EXPERIMENTAL RHEUMATOLOGY 2006.

Key words: Synovial-like fibroblasts, apoptosis, rheumatoid arthritis.

ABSTRACT

Objective. *The aim of the study is to describe a group of patients with a highly destructive and asymptomatic form of psoriatic arthritis, mimicking a Charcot-like joint disease.*

Methods. *We studied 180 patients with psoriatic arthritis and identified 4 patients with arthritis mutilans mimicking a Charcot-like joint disease. Clinical history, physical exam, and immunological testing were performed as well as X-ray of affected joints. Synovial membrane and sural nerve biopsies were performed and diagnosis of psoriasis was confirmed by skin biopsy.*

Results. *Four patients with psoriatic arthritis mutilans according to Moll and Wright classification criteria (1) and Charcot-like joint disease were identified and evaluated. There were 2 males and 2 females, all Caucasians. The mean age \pm SD was 57.8 ± 14.2 years. Mean arthritis duration \pm SD was 6 ± 4.6 years and mean cutaneous duration \pm SD was 13 ± 10.4 years. All patients had polyarthritides and a sudden onset of bilateral, painless, and highly destructive arthropathy involving large, non-weight bearing (elbows) and weight bearing (knees), and also small joint of hands and feet. Synovial membrane biopsy showed findings similar to those found in Charcot joint disease, including ischemic neuropathy.*

Conclusion. *A newly-recognized subset of patients with psoriatic arthritis and Charcot-like joint disease according to clinical, radiographic and histological features is described. The proposed neurovascular theory may explain the pathogenesis of this presentation.*

Introduction

Psoriatic arthritis (PsA) is a chronic inflammatory joint disorder, related to the presence of cutaneous psoriasis. Several subsets of PsA are recognized, including: distal interphalangeal (DIP) joint involvement, peripheral asymmetric arthropathy, polyarticular symmetric involvement, psoriatic spondyloarthropathy and arthritis mutilans (1). The latter subset represents the most crippling and destructive of all forms of PsA and is characterized by erosions of the DIP joints, periostitis, joint anky-

losis and characteristic pencil in cup deformity and digital telescoping (opera glass finger) (1).

From biblical times leprosy had been mistaken with a variety of clinical disorders including PsA. The radiographic and microscopic study of ten skeletons found in a Byzantine monastery in the Judean desert evidenced characteristic lesions of PsA, identical to those described in the mutilans form (1, 2), lending credence to the notion that the painless and destructive nature of the findings led to the confusion between leprosy and PsA (2).

Patients with PsA are less tender over the affected joints than are patients with rheumatoid arthritis, although no peripheral neurological impairment has been described so far (3). The relation between PsA and trauma is well established, although its nature is not clear, and generally associated with the development of PsA in a patient with previously longstanding cutaneous disease (4).

Reflex sympathetic dystrophy is also precipitated by trauma and the presence of diffuse osteopenia in the initial stages of the disease is another similarity with PsA (5). Of great interest and relevance is the recent observation that PsA patients exhibit significant demineralization in more than two-thirds of patients with peripheral arthritis. This abnormality, however, was not related to indices of inflammation (6). Another rheumatologic condition associated with trauma is neuropathic arthropathy or Charcot joint disease. This condition is most commonly caused by diabetes mellitus, syringomyelia, leprosy, and meningomyelocele. Regarding rheumatologic causes of Charcot joint disease, this has been described in 2 children with juvenile rheumatoid arthritis (7), occasionally in association with calcium pyrophosphate deposit disease (CPPD) (8), and other crystal deposit disorders such as gout (9).

The aim of this report is to describe a recently recognized subset of patients with PsA characterized by the presence of Charcot-like joint disease. PsA, however, is not recognized as a common cause of Charcot-like joint disease.

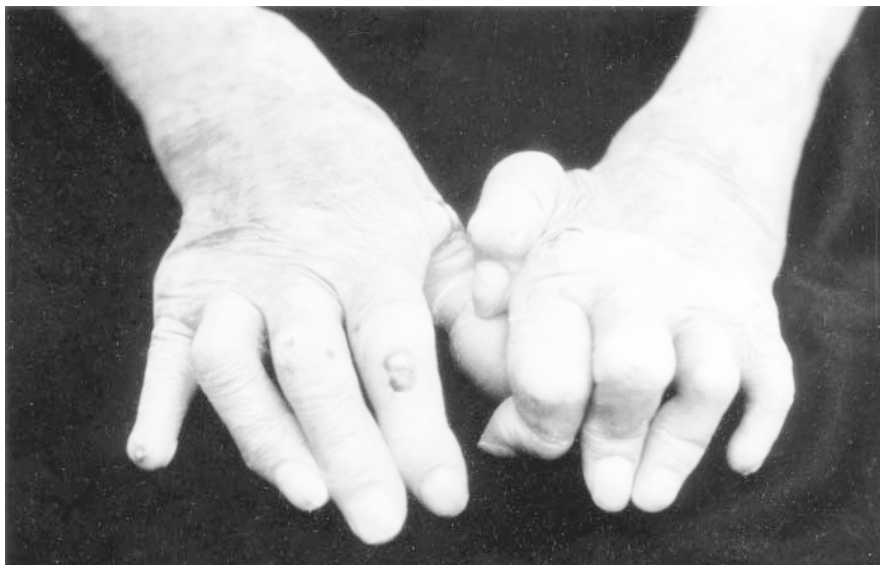

Fig. 1. Hands of patient no.2 demonstrating boutonniere deformities, and auto-amputation of the distal phalanx of the fifth digit.

Patients and methods

We performed a detailed evaluation of 180 patients with PsA seen at the rheumatology clinic, Louisiana State University Health Sciences Center, New Orleans, LA, USA and at the rheumatology service at San Juan de Dios Hospital, National University of Colombia, Santa Fe de Bogota, Colombia from 1976 to 2003. We identified 4 patients with arthritis mutilans and Charcot-like disease according to the criteria of Moll and Wright (1).

A detailed clinical history, physical exam and tender and swollen joint count were performed by experienced rheumatologists (LRE and AI), including a thorough neurological evaluation. Determinations of rheumatoid factor, antinuclear antibodies, and C-reactive protein were performed in all patients. In addition, plain radiographs of the affected joints were performed by case basis and were evaluated by a musculoskeletal radiologist (LSUHSC).

Biopsies: synovial membrane biopsy of the involved joints as well as sural nerve biopsy were obtained in all of our 4 patients. Patients were diagnosed as having cutaneous psoriasis after a detailed examination of a skin biopsy by a dermatopathologist (LSUHSC).

We also performed a pubmed search with no limits looking for the association of PsA and Charcot joint disease and we only found some case-reports

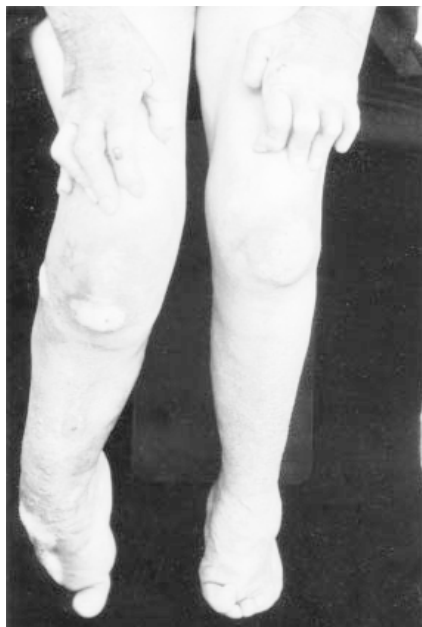

Fig. 2. Feet of patient no. 2 demonstrating cavus deformities, auto-amputation of several toes of the right foot, and psoriatic rash in both knees.

but did not find any case series. Descriptive statistics were employed.

Results

After a detailed evaluation of 180 PsA patients we identified 4 patients with PsA mutilans according to Moll and Wright criteria (1) and Charcot-like joint disease. There were 2 males and 2 females, and all were Caucasians. The mean age \pm SD was 57.8 ± 14.2 years (range = 45-71). Mean duration \pm SD

of arthritis was 6 ± 4.6 (range = 2-10) and mean duration \pm SD of cutaneous psoriasis was 13 ± 10.4 years (range = 1-20). All patients had a sudden onset of a painless, highly destructive polyarthritides involving large non-weight bearing (elbows) and weight bearing (knees), and small joints of the hands and feet. Physical exam revealed soft-tissue swelling around the affected joints, opera glass deformities and one patient exhibited ankylosis of the small joints in both hands (Fig. 1). One female patient was severely deformed as can be appreciated in the photographs. She had severe arthritis mutilans especially in feet, with auto-amputation of several toes in the right foot (Fig. 2). After a detailed neurological evaluation only two patients showed loss of deep sensation. None of the patients had a history of trauma, diabetes mellitus or syphilis. A 71-year male patient (patient no. 3) with a history of tennis elbow had a steroid injection in only one occasion and showed a rapidly progressive and destructive form of arthritis involving not only the elbows but also hands and feet. All patients were properly diagnosed by the dermatology service as having cutaneous psoriasis confirmed by biopsy and all of them had extensive cutaneous involvement. DMARD therapy was initiated after the patients were diagnosed with Charcot-like joint disease; methotrexate was the most common agent used, and all were receiving non-steroidal anti-inflammatory drugs (NSAIDs) and a few received low dose prednisone therapy. All 4 patients had negative tests for rheumatoid factor, antinuclear antibodies, and normal levels of C-reactive protein and erythrocyte sedimentation rate. Table I shows the demographic and clinical characteristics of the 4 patients with PsA and Charcot-like joint disease.

Radiographs of the affected joints showed extensive bone resorption and debris, sharp demarcation with remaining bones and no evidence of bone repair. In some cases lytic destruction of the tarsal bones and tibia, with total disappearance of toes was observed (Fig. 3). Synovium biopsies revealed: pannus formation invading cartilage and multi-

ple fragments of bone and cartilage embedded in the deep layer of the synovium (Fig. 4). Increased osteoclastic activity was also seen. Sural nerve biopsy revealed marked endothelial cell swelling with ischemic changes of the surrounding tissues.

Discussion

Four patients with PsA exhibiting a Charcot-like arthropathy are described. From a clinical, radiological and histopathological point of view the described patients are similar to those reported in Charcot-like joint disease.

The role of trauma deserves special consideration since it has been shown that trauma can trigger any form of PsA and may also play a role in Charcot joint disease. All the known disorders associated with Charcot joint disease such as diabetes mellitus have underlying peripheral neuropathy which is thought to be responsible for this destructive form of arthropathy. The so called neurotraumatic theory suggests that somatic muscular reflexes in charge of the protection of the joint from extreme range of motion, when lost secondary to neuropathy may lead to joint destruction. This theory, however, does not fully explain the changes observed in Charcot joint disease, considering that only a minority of patients with severe peripheral sensory neuropathy develop Charcot joints, and even when present it is not related to the degree of physical activity and/or severity of neuropathy (10). None of our 4 described PsA patients exhibited any known medical condition associated with Charcot joints and peripheral neurological involvement is not a recognized feature of PsA. The presence of endothelial cell swelling in blood vessels of the sural nerve and ischemic changes of surrounding tissues together with the increased osteoclastic activity observed in the multiple bone fragments embedded in the deep layer of synovium, lend support to the neurovascular theory for the pathogenesis of Charcot joint disease. This theory proposes a neurally initiated vascular reflex leading to active bone resorption by osteoclasts (11). More recent work, clearly demonstrates the presence of a

Table I. Demographic and clinical characteristics of patients with Charcot-like arthropathy.

Characteristics	Patient 1	Patient 2	Patient 3	Patient 4
Gender	Male	Female	Male	Female
Arthritis Duration (years)	2	10	2	10
Psoriasis Duration	20	1	2*	18
Involved Joints	hands, feet	hands, feet, Knees	Left elbow	hands, feet
Other causes of Charcot	No	No	No	No
Axial Involvement	No	No	No	No
Treatment **	MTX, NSAIDs	MTX, NSAIDs	MTX, PDN	MTX

* Nail involvement.

** Treatment initiated after diagnosis of Charcot-like joint disease made.

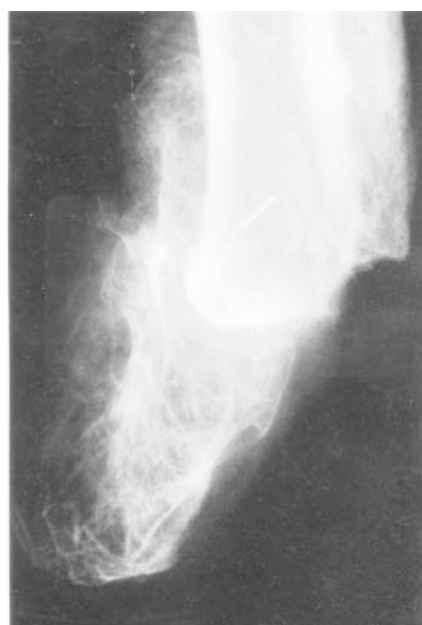

Fig. 3. Radiograph of the right foot of patient no.2 demonstrating extensive lytic destruction of the tarsal bones and involvement of the distal epiphyses of tibia and fibula.

marked increase in osteoclast precursors particularly in those PsA patients with bone erosions (12). Furthermore, similar endothelial cell changes and other vascular abnormalities have been described in the synovial membrane of patients with PsA (13, 14). The presence, however, of sensory neuropathy in 2 of our patients may have also contributed to the development of Charcot-like joint disease.

Of great interest is the recent observation made in patients with PsA describing an asymptomatic erosive form of peripheral PsA (15). The authors, however, did not describe any patient with a Charcot-like pattern of joint involvement and it is tempting to suggest that the patients described represent one

end of the clinical spectrum, while our patients represent another end- a more severe form. In support of this view, is the report of Offidini *et al.* demonstrating subclinical joint involvement by MRI in the hands and feet of subjects with pre-existing cutaneous psoriasis (16), which lends credence to the notion that erosive disease often asymptomatic, begins long before the clinical findings of arthritis are recorded.

In conclusion, a newly recognized subset of patients with PsA and Charcot-like disease is described. Histopathological findings in sural nerve biopsy provide support for the proposed neu-

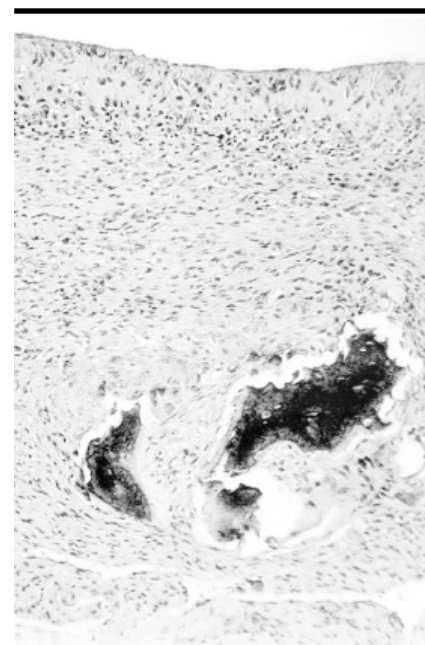


Fig. 4. Synovial membrane biopsy of the left elbow of patient no.3 revealing exuberant synovial proliferation with fibrosis, inflammatory infiltrate mainly composed of mononuclear cells and some plasma cells containing numerous shards of bone. These findings are consistent with neuropathic joint changes.

rovascular theory of the pathogenesis of this Charcot-like arthropathy.

References

- MOLL JMH, WRIGHT V: Psoriatic arthritis. *Sem Arthritis Rheum* 1973; 3: 55-78.
- ZIAS J, MITCHELL P: Psoriatic arthritis in a fifth-century Judean Desert monastery. *Am J Phys Anthropol* 1996; 101: 491-502.
- BUSKILA D, LANGEVITZ P, GLADMAN DD, UROWITZ S, SMYTHE HA: Patients with rheumatoid arthritis are more tender than those with psoriatic arthritis. *J Rheumatol* 1992; 19: 1115-9.
- SCARPA R, DEL PUENTE A, DI GIROLAMO C, DELLA VALLE G, LUBRANO E, ORIENTE P: Interplay between environmental factors, articular involvement, and HLA-B27 in patients with psoriatic arthritis. *Ann Rheum Dis* 1992; 51: 78-9.
- PAGES M, LASSOUED S, FOURNIE B, FOUNIE A: Psoriatic arthritis precipitated by physical trauma: destructive arthritis or associated with reflex sympathetic dystrophy? *J Rheumatol* 1992; 19: 185-6.
- FREDIANI B, ALLEGRI A, FALSETTI P *et al.*: Bone mineral density in patients with psoriatic arthritis. *J Rheumatol* 2001; 28: 138-43.
- ROTHSCHILD BM, HANISSIAN AS: Severe generalized (Charcot-like) joint destruction in juvenile rheumatoid arthritis. *Clin Orthop* 1981; 155: 75-80.
- SCUTELLARI PN, ORZINCOLO C, DROGHETTI M: Crystalline calcium pyrophosphate dehydrate deposit disease. *Radiol Med* 1985; 71: 129-34.
- LAVERSUCH CJ, BRUCKNER FE: Development of a "Charcot-like joint" in tophaceous gout. *JR Soc Med* 1995; 88: 713-5.
- O'CONNOR BL, BRANDT KD: Neurogenic factors in the etiopathogenesis of osteoarthritis. *Rheum Dis Clin NA* 1993; 19: 581-605.
- BROWER AC, ALLMAN RM: Pathogenesis of the neuropathic joint: neurotraumatic vs. neurovascular. *Radiology* 1981; 139: 349-54.
- RICHLIN CT, HAAS-SMITH SA, LI PING, HICKS DG, SCHWARZ EM: Mechanisms of TNF-alpha and RANKL-mediated osteoclastogenesis and bone resorption in psoriatic arthritis. *J Clin Invest* 2003; 111: 821-31.
- ESPINOZA, LR, VASEY FB, ESPINOZA, CG, BOCANEGRA TS, GERMAIN BF: Vascular changes in psoriatic synovium. A light and electron microscopic study. *Arthritis Rheum* 1982; 25: 677-84.
- ESPINOZA LR, LAUTER S, VASEY FB, OSTERLAND CK: Hemarthrosis in psoriatic arthritis. *Arthritis Rheum* 1977; 20: 1034-5.
- PALAZZI C, D'AGOSTINO L, D'AMICO E, PENESSE E, PETRICCA A: Asymptomatic erosive peripheral psoriatic arthritis: a frequent finding in Italian patients. *Rheumatology* 2003; 42: 909-11.
- OFFIDANI A, CELLINI A, VALERI G, GIOVAGNONIA: Subclinical joint involvement in psoriasis: magnetic resonance imaging and x-ray findings. *Acta Derm Venerol* 1999; 78: 463-5.