

## ***Propionibacterium acnes* and SAPHO syndrome: a case report and literature review**

M. Colina, A. Lo Monaco,  
M. Khodeir\*, F. Trotta

Sezione di Reumatologia, Dipartimento di Medicina Clinica e Sperimentale, Università degli Studi di Ferrara;  
\*Sezione di Microbiologia, Dipartimento di Patologia ed Oncologia, Azienda Ospedaliera/Universitaria Arcispedale Sant'Anna, Ferrara, Italy.

Matteo Colina, Andrea Lo Monaco,  
Micheline Khodeir, Francesco Trotta.

This work was supported by a grant of CARIFE in a framework of the University of Ferrara sponsorship collaboration.

Please address correspondence to: Matteo Colina MD, Sezione di Reumatologia, Dipartimento Medicina Clinica e Sperimentale, Università degli Studi di Ferrara, Azienda S. Anna, Corso della Giovecca 203, 44100 Ferrara, Italy.  
E-mail: teocolina@libero.it

Received on August 28, 2006; accepted in revised form on January 18, 2007.

© Copyright CLINICAL AND EXPERIMENTAL RHEUMATOLOGY 2007.

**Key words:** SAPHO syndrome, *Propionibacterium acnes*, osteitic lesions, anterior chest wall involvement.

Competing interests: none declared.

### **ABSTRACT**

**Objective.** To describe the presence of *Propionibacterium acnes* (*P. acnes*) in a series of patients with SAPHO syndrome in which a bone biopsy has been carried out and to discuss the results comparing them to the data described in the literature.

**Methods.** In 6 out of 56 patients with SAPHO syndrome, a bone biopsy from osteitic lesion was carried out. This invasive investigation was performed only in those cases in which it was necessary to clarify the diagnosis.

**Results.** Of the 6 biopsies processed, *P. acnes* was isolated in only one case. No other infectious agents were identified.

**Conclusions.** *P. acnes* is not often found in bone lesions of SAPHO syndrome. A bone biopsy may represent a procedure useful for corroborating the diagnosis or for excluding other diseases only in specific cases.

### **Introduction**

SAPHO syndrome is an acronym for "Synovitis, Acne, Pustulosis, Hyperostosis and Osteitis" introduced by Kahn and Chamot to describe a clinical picture affecting bones, joints and skin (1). Due to certain clinical and radiological aspects, some authors include SAPHO syndrome in the group of the seronegative spondyloarthropathies, while others consider it a reactive osteitis (2, 3). The prevalence of the syndrome is not completely understood. In fact the disease has long been considered rare, but the occurrence of confusing variants mean that it often goes unrecognised (4, 5).

At present, the pathogenesis is unknown. Although bone lesions are usually sterile, the role of *Propionibacterium acnes* (*P. acnes*), a bacterium involved in the pathogenesis of comedones and acne, is being questioned. Positive clues are the discovery of *P. acnes* in bone lesions from some patients with osteitis associated with acne and the isolation of the microorganism from the synovial tissue and fluid in patients with SAPHO syndrome (6).

We report here our experience in this topic, including the description of a case in which *P. acnes* was isolated from an osteitic sternal lesion.

### **Patients and methods**

Fifty-six patients (40 females, 16 males; mean age  $44 \pm 14$  years) with SAPHO syndrome were identified in our tertiary referral center from 1990 according to the currently proposed criteria (1). Forty-one patients presented both bone and skin lesions, while 15 had the purely osteitic/hyperostotic form of the disease. The most frequent cutaneous lesion was palmo-plantar pustulosis (26 cases) followed by severe acne.

In 6 cases, a CT-guided biopsy from osteitic lesions was carried out. All biopsies were taken only in those cases in which the osteolytic feature of the bone lesion and/or the progressive bone enlargement in subjects still without cutaneous involvement led to a diagnostic doubt. In 5 cases, the bone involved was the sternum, while in one case, it was the vertebral arch. All biopsies were taken from patients with a disease history of less than 2 years.

After written consent and an accurate disinfection of the biopsy site in order to exclude the possibility of contaminations, two biopsy specimens from every patient were microbiologically investigated for the possible presence of germs, including *P. acnes*. Besides blood and Sabourad's agar, the specimens were cultured in TYG (tryptone-yeast-glucose) with furazolidone for seven days at 37°C. In the positive case, an antibiogram was made. A histological examination was also carried out.

### **Results**

Features of the patients investigated are summarized in Table I. In one case out of 6, *P. acnes* was isolated from the bone biopsy specimen, while there was no bacterial growth in the other cases. No other infectious agent was identified. In all the cases, histological examination revealed aspecific patterns of acute (3 cases) or chronic (3 cases) inflammation, varying from a cellular infiltrate with a prevalence of polymorphonuclear cells to a macrophage-rich infiltrate with antigen-specific T cells and fibrosis.

### **Case description**

A 47-year-old female was admitted to our Unit with fever, anterior chest wall

**Table I.** Clinical and histological features of the cases studied at biopsy time.

	Age	Disease duration	Osteoarticular lesions	Cutaneous lesions	<i>P. acnes</i>	Histological pattern
1	28	13 months	vertebrae + peripheral	none (PPP after 5 months)	-	chronic inflammation*
2	41	9 months	sternum + peripheral	none	-	chronic inflammation*
3	37	11 months	sternum	none (PPP after 8 months)	-	chronic inflammation*
4	34	8 months	sternum	none	-	acute inflammation**
5	52	4 months	sternum + peripheral	none (acne conglobata after 25 months)	-	acute inflammation**
6	47	3 months	sternum	none (PPP after 1 months)	+	acute inflammation**

\*Macrophage-rich infiltrate with non-antigen specific T cell.

\*\*Cellular infiltrate with a prevalence of polymorphonuclear cells.

PPP: pustulosis palmo-plantaris.

pain, polyarthralgias and wheeziness, which had started 3 months earlier. Before admission, the patient had assumed steroids (prednisone 20 mg/day) without benefit, following a diagnosis, made in another Unit, of Adult-onset Still's disease.

The only significant clinical feature was a mild tenderness of the anterior chest wall. A chest radiography showed minimal pleural effusion and an ecography revealed a minimum pericardial effusion. Blood analysis showed increased erythro-sedimentation rate (ESR) and C-reactive protein (CRP: normal value < 0.6 mg/dl) (118 mm/h and 13 mg/dl, respectively), leukocytosis (17.800/mm<sup>3</sup>) with neutrophilia (81.5 %) and thrombocytosis (685,000/

mm<sup>3</sup>). A microcytic iposideremic anaemia was also evident. Bacteriological investigation of blood and urine were repeatedly negative.

A total-body scintigraphy was carried out and a focal hyper-captation at the syncondrosis manubrio-sternalis was documented (Fig. 1). A CT scan revealed hyperostosis of the sternum. After that, a biopsy of the sternal lesion was carried out in order to clarify the diagnosis. The culture resulted positive for *P. acnes*, while the biopsy histological picture showed an aspecific flogistic pattern. The antibiogram revealed that *P. acnes* was sensitive to doxycycline. Antibiotic therapy with doxycycline (100 mg twice daily) associated with NSAIDs and low dosage steroids was begun. In about two months this therapy induced an almost complete resolution of the osteo-articular symptoms and the normalization of laboratory parameters. One month after discharge, the patient came back to our Unit because of the occurrence of palmo-plantaris pustulosis. Cutaneous manifestations had a partial resolution after a couple of weeks. After two years, the patient is symptom-free from an articular point of view, while skin lesions have continued to recur regardless of therapy.

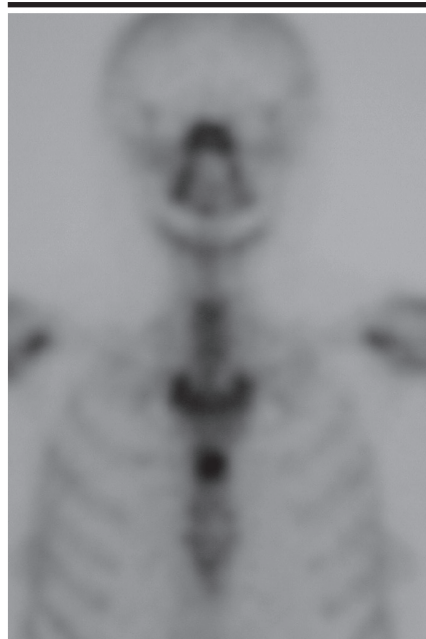
### Discussion

According to the proposed criteria, in the reported case, osteitis with positive culture for *P. acnes* followed by palmo-plantaris pustulosis, were sufficient to support the diagnosis of SAPHO syndrome (1). Typical cutaneous lesions of the syndrome, that may be absent, are palmo-plantar pustulosis and acne conglobata. Bone lesions are charac-

terized by osteitis-like features and hyperostosis, joint lesions being more frequently observed close to the bone involved (2).

In this case, the onset of the disease was quite unusual and possibly confusing, suggesting a diagnosis of Adult-onset Still's disease for which steroid therapy was begun in another hospital. An accurate re-examination of the clinical history, together with the data from the scintigraphy, led us to carry out a sternal biopsy that clarified the diagnosis.

*P. acnes* is a Gram-positive, motionless, non-spore-forming bacillus with maximum growth in anaerobiosis. Microorganisms involved in human pathology are of 5 biotypes: biotype III and I are the most commonly involved in the aetiopathogenesis of acne. They form part of the normal flora of the oral cavity, large intestine, conjunctiva, external ear conduct and the skin, in particular in the sebaceous follicles (7-9). Identification of *P. acnes* from bone biopsy in SAPHO syndrome has occasionally been reported, leading to the hypothesis that the micro-organism may play a part in the pathogenesis of the disease, although its exact role is currently unknown. At present, including the diseases actually related to SAPHO syndrome, 24 out of 69 cases studied have been reported. A part the series reported by Edlund *et al.* (10) and by Kirchhoff *et al.* (11) in which bacteria were isolated from the bone specimen of 7 out of 15 and 8 out of 14 patients with SAPHO syndrome respectively, in the other cases this micro-organism was only occasionally found in bacterial cultures (12-18) (Table II).



**Fig. 1.** Scintigraphic features of the reported case. A subsequent biopsy of the bone lesion showed the presence of *P. acnes*.

**Table II.** Positive findings of *P. acnes* in bone lesions (biopsies and cultures) in cases of SAPHO syndrome or related diseases reported in the literature.

Authors	Year	Investigated (number)	<i>P.acnes</i> positive (number)
Sherusan <i>et al.</i> <sup>12</sup>	1982	1	1
Collert <i>et al.</i> <sup>13</sup>	1982	1	1
King <i>et al.</i> <sup>14</sup>	1987	7	1
Edlund <i>et al.</i> <sup>10</sup>	1988	15	7
Gerster <i>et al.</i> <sup>15</sup>	1990	1	1
Kotilainen <i>et al.</i> <sup>16</sup>	1996	1	1
Reith <i>et al.</i> <sup>17</sup>	1996	8	2
Hayem <i>et al.</i> <sup>18</sup>	1999	15	1
Kirchhoff <i>et al.</i> <sup>11</sup>	2003	14	8
Our study	2006	6	1
Total		69	24

In the series reported here, *P. acnes* was found only in one case out of the 6 studied. Perhaps, the use of other procedures, such as polymerase chain reaction (PCR), should give us dates on the real frequency of *P. acnes* in osteitic bone lesions, leading to a better understanding of the aetio-pathogenesis of this disease.

The ability of the germ to persist in bone lesions in a form incompatible with culturing is another possible explanation. Recently *P. acnes* has also been identified in inter-vertebral disc material of patients with severe sciatica, suggesting that the chronic inflammation leading the symptoms may be triggered by a low virulence infection (19). Following this hypothesis, low virulence micro-organisms may have access to bone, thereby initiating or stimulating a chronic inflammatory response with accompanying symptoms. In several studies, it has been demonstrated that *P. acnes* may trigger a non-specific activation of cell-mediated immunity. The immunological response could be an attempt to eliminate the germ inducing the perpetuation of the inflammation (20). In addition, the complete genome sequence has been detected and it clearly reveals numerous gene products involved in degrading host molecules. This justifies the ability of the germ to colonize and survive in human skin sites as well as in a wide spectrum of environments including bone and synovial fluid (6, 21, 22). On the other hand, in the reported series

with many cases, a possible contamination cannot be excluded, considering the fact that *P. acnes* is an ordinary skin saprophyte (7, 8).

As *P. acnes* is often implicated in the pathogenesis of comedones and acne, its presence in osteitic lesions could indicate a subset of SAPHO patients, characterized by a notable response to antibiotic therapy. As in other reported cases, in our patient antibiotic therapy was effective in controlling the osteo-articular manifestations of the disease (6, 23-25). Conversely, palmo-plantar pustulosis was indifferent to the antibiotic therapy. Different responses to antibiotic therapy may also reflect different pathogenetic mechanisms of the SAPHO syndrome symptoms. In fact, *P. acnes* could simply be a trigger for osteitis and hyperostosis, with the damage continuing after its elimination. In conclusion, at least in some cases, *P. acnes* could represent the *primum movens* of SAPHO syndrome, osteitic lesions being the consequence of a reaction to a low virulence infection. An accurate selection of the patients who underwent bone biopsy may improve our knowledge regarding this topic.

## References

- BENHAMOU CL, CHAMOT AM, KAHN MF: Synovitis-acne-pustulosis hyperostosis-osteomyelitis (SAPHO). A new syndrome among the spondyloarthropathies? *Clin Exp Rheumatol* 1988; 6: 109-12.
- KAHN MF, KHAN MA: The SAPHO syndrome. *Bailliers Clin Rheumatol* 1994; 8: 333-62.
- MEJJAD O, DARAGON A, LOUVEL JP *et al.*:

- Osteoarticular manifestations of pustulosis palmaris et plantaris and of psoriasis: two distinct entities. *Ann Rheum Dis* 1996; 55: 177-80.
- TROTTA F, LA CORTE R, BAJOCCHI G, MANICARDI S: Hyperostosis and multifocal osteitis: a purely rheumatological subset of SAPHO syndrome. *Clin Exp Rheumatol* 1990; 8: 401-4.
- VAN DOORNUM S, BARRACLOUGH D, MCCOLL G, WICKS I: SAPHO: rare or just not recognized? *Semin Arthritis Rheum* 2000; 30: 70-7.
- SCHAEVERBEKE T, LEQUEN L, DE BARBEYRAC B *et al.*: *Propionibacterium acnes* isolated from synovial tissue and fluid in a patient with oligoarthritis associated with acne and pustulosis. *Arthritis Rheum* 1998; 41: 1889-93.
- PERRY AL, LAMBERT PA: *Propionibacterium acnes*. *Lett Appl Microbiol* 2006; 42: 185-8.
- FUNKE G, VON GRAEVENITZ A, CLARIDGE JE 3RD, BERNARD KA: Clinical microbiology of coryneform bacteria. *Clin Microbiol Rev* 1997; 10: 125-59.
- HIGAKI S, NAKAMURA M, MOROHASHI M, YAMAGISHI T: *Propionibacterium acnes* biotypes and susceptibility to minocycline and Keigai-rengyo-to. *Int J Dermatol* 2004; 43: 103-7.
- EDLUND E, JOHNSON U, LIDGREN L *et al.*: Palmo-plantar pustulosis and sternocostoclavicular arthro-osteitis. *Ann Rheum Dis* 1988; 47: 809-15.
- KIRCHHOFF T, MERKESDAL S, ROSENTHAL H *et al.*: Diagnostic management of patients with SAPHO syndrome: use of MR imaging to guide bone biopsy at CT for microbiological and histological work-up. *Eur Radiol* 2003; 13: 2304-8.
- SERUSHAN M, SPENCER DL, YEH WS, KAMINSKI M, SKOSEY JL: Osteomyelitis of cervical spine due to *Propionibacterium acnes*. *Arthritis Rheum* 1982; 25: 346-8.
- COLLERT S, ISACSON J: Chronic sclerosing osteomyelitis (Garre). *Clin Orthop Relat Res* 1982; 164: 136-40.
- KING SM, LAXER RM, MANSON D, GOLD R: Chronic recurrent multifocal osteomyelitis: a non-infectious inflammatory process. *Pediatr Infect Dis J* 1987; 6: 907-11.
- GERSTER JC, LAGIER J, LIVIO JJ: *Propionibacterium acnes* in spondylitis with palmo-plantar pustulosis. *Ann Rheum Dis* 1990; 49: 337-8.
- KOTILAINEN P, MERILAHTI-PALO R, LEHTONEN OP *et al.*: *Propionibacterium acnes* isolated from sternal osteitis in a patient with SAPHO syndrome. *J Rheumatol* 1996; 23: 1302-4.
- HAYEM G, BOUCHAUD-CHABOT A, BENALI K *et al.*: SAPHO syndrome: a long-term follow-up study of 120 cases. *Semin Arthritis Rheum* 1999; 29: 159-71.
- REITH JD, BAUER TW, SCHILS JP: Osseous manifestations of SAPHO (synovitis, acne, pustulosis, hyperostosis, osteitis) syndrome. *Am J Surg Pathol* 1996; 20: 1368-76.
- STIRLING A, WORTHINGTON T, RAFIQ M, LAMBERT PA, ELLIOTT TSJ: Association between sciatica and *Propionibacterium acnes*. *Lancet* 2001; 357: 2024-5.
- JAPPE U, BOIT R, FARRAR MD, INGHAM E,

- SANDOE J, HOLLAND KT: Evidence for diversity with *Propionibacterium acnes*: a comparison of the T cell stimulatory activity of isolates from inflammatory acne, endocarditis and the laboratory. *J Eur Acad Dermatol Venereol* 2004; 18: 450-4.
21. BRÜGGEMANN H, HENNE A, HOSTER F *et al.*: The complete genome sequence of *Propionibacterium acnes*, a commensal of human skin. *Science* 2004; 305: 671-3.
22. BRÜGGEMANN H: Insights in the pathogenic potential of *Propionibacterium acnes* from its complete genome. *Semin Cutan Med Surg* 2005; 24: 67-72.
23. ROTHSCILD B, SCHILS J, LAVELLE H: Potential therapeutic approach to SAPHO. *Semin Arthritis Rheum* 2000; 29: 332-4.
24. WAGNER AD, MAI U, HAMMER M, ZEIDLER H: Long term antibiotic therapy successful in patients with SAPHO syndrome. *Arthritis Rheum* 1997; 40 (Suppl. 9): S62.
25. ROZIN AP, NAHIR AM: Is SAPHO syndrome a target for antibiotic therapy? *Clin Rheumatol* 2006; 26: 1183-5.



# Chronic alcohol consumption as a predisposing factor for multiple tendon ruptures in unusual sites in a patient with rheumatoid arthritis

L.A. Bourikas<sup>1</sup>, H.D. Kritikos<sup>1</sup>,  
O.G. Papakostantinou<sup>2</sup>,  
G.A. Katsikas<sup>1</sup>, D.T. Boumpas<sup>1</sup>  
P.I. Sidiropoulos<sup>1</sup>

<sup>1</sup>Department of Rheumatology, Allergy and Clinical Immunology, and <sup>2</sup>Department of Radiology, University Hospital of Heraklion Crete.

Leonidas A. Bourikas, MD; Heraklis D. Kritikos, MD; Olympia G. Papakostantinou, MD; Georgios A. Katsikas, MD; Dimitrios T. Boumpas, MD, FACP; Prodromos I. Sidiropoulos, MD.

Please address correspondence and reprint requests to: Prodromos I. Sidiropoulos MD, Department of Rheumatology, Clinical Immunology and Allergy, University of Crete, University Hospital, Voutes 71110, Heraklion, Greece. E-mail: sidiropp@med.uoc.gr

Received on March 25, 2006; accepted in revised form on September 7, 2006.

© Copyright CLINICAL AND EXPERIMENTAL RHEUMATOLOGY 2007.

**Key words:** tendon rupture, rheumatoid arthritis, alcohol, IGF.

## Abstract

*Simultaneous bilateral patellar tendon ruptures are a rare complication of rheumatoid arthritis (RA). Systemic inflammatory diseases (RA, systemic lupus erythematosus (SLE), chronic renal failure, primary and secondary hyperparathyroidism, diabetes mellitus, obesity, sports activity, older age (>50) and drugs (prolonged use of high doses of steroids, local steroid injections and quinolones) are considered as potent predisposing factors for tendon rupture. We report a case of an alcoholic patient with RA and bilateral spontaneous tendon ruptures of the knees. Circumstantial evidence suggest that in this patient, chronic alcohol consumption, a very frequent cause of toxicity to striated and cardiac muscle, contributed to the injury.*

## Introduction

Rheumatoid arthritis (RA) is a chronic autoimmune disease that leads to substantial disability and reduced quality of life. In more than 50% of patients, tendons of the wrists are affected (1) and tendon ruptures may occur, possibly by overproduction of matrix metalloproteinases (MMPs 1, 2, 3, 8, 13) (2).

Although there are several case reports with bilateral simultaneous, non-traumatic, tendon ruptures of the knees, no large single-center case series exists due to the rarity of this injury. Recently Kellersmann *et al.* analyzed all reports and predisposing factors of bilateral simultaneous patellar tendon ruptures reported during the last 43 years (3). In 62% of 50 cases, no known predisposing factors existed. This observation suggests that in such cases investigation for additional predisposing factors is required.

## Case

A 52-year-old man was referred to our clinic with a 6-year history of rheumatoid arthritis with lung involvement. He had inadequate response to methotrexate and cyclosporine that had been discontinued 3 years ago. He occasionally received 2 mg of methylprednisolone daily for small periods during the last 6 months.

The patient experienced spontaneous

bilateral tendon ruptures of his knees 4 months ago, while walking peacefully on a level surface and he underwent plastic reconstruction of patellar tendons with no sequela.

Regarding his medical history, he reported consumption of more than 60 g of alcohol daily for the last 20 years and a serious car accident 12 years ago. Fifteen years ago he experienced a spontaneous rupture of the long head of the biceps brachii tendon of the right arm, but he did not seek medical attention. He was divorced and worked as a barman for the last 20 years. He had no history of quinolone intake.

Clinical examination revealed active RA (DAS28 = 7.35) and atrophy of the quadriceps muscles. Rales were present at the base of both lungs. The patient had nodulosis in the exterior surface of both elbows, while conventional radiographs of hands and feet showed soft tissue swelling and periarticular osteopenia of metacarpophalangeal and proximal interphalangeal joints of both hands, with no erosions. A muscular mass because of the rupture of the long head of the biceps brachii tendon was obvious in the middle of his right arm. Laboratory tests revealed macrocytosis due to alcohol abuse with no anemia, elevated lactate dehydrogenase (359U/l), hyperlipidemia (cholesterol = 253mg/dl, LDL-C = 179mg/dl), elevated C-reactive protein (4.44 mg/dl) and high titer of rheumatoid factor (3260 IU/ml). Antinuclear antibodies and anti-neutrophil cytoplasmic antibodies were negative. Thyroid tests and levels of parathormone were normal.

A high-resolution computed tomography (HRCT) of the chest revealed interstitial lung disease with honeycombing and no evidence of active alveolitis.

The histological examination of the surgical specimens from tendon and quadriceps, muscle revealed signs of chronic inflammatory arthritis and degenerative disorders of the striated muscle.

## Magnetic resonance (MR) imaging

The MR imaging study for both knees included a sagittal T1-weighted, an axial T1-weighted and an axial short-tau inversion recovery (STIR) sequence. MR imaging revealed rupture of the

Competing interests: none declared.