

## Distal Madelung-Launois-Bensaude disease: an unusual differential diagnosis of acromelic arthritis

O. Lemaire, C. Paul,  
L. Zabraniecki

Olivia Lemaire, MD, Registrar;  
Carle Paul, MD, Professor, Head of  
Department of Dermatology;  
Laurent Zabraniecki, MD, Consultant.

Departments of Rheumatology and  
Dermatology of Purpan Hospitalo-  
Universitary Center, Toulouse, France.

Please address correspondence and  
reprint requests to: Dr. O. Lemaire,  
Service de Rhumatologie, Hopital Purpan,  
Place du Dr Baylac, 31059 Toulouse  
Cedex 9, France.

E-mail: lemaire.o@chu-toulouse.fr

Received on August 13, 2007; accepted on  
November 27, 2007.

© Copyright CLINICAL AND  
EXPERIMENTAL RHEUMATOLOGY 2008.

**Key words:** Madelung-Launois-Bensaude disease, multiple symmetrical lipomatosis, distal, hands, feet.

### ABSTRACT

*Madelung-Launois-Bensaude (MLB) disease is uncommon and probably under-diagnosed. It is defined as a symmetrical proximal accumulation of fat. Its physiopathology is obscure, but favouring factors, like alcohol or corticosteroids, are well known. We describe, for the first time, an unusual case of distal form of the disease, involving hands and feet simultaneously. Moreover, this phenotype was associated with a proximal form of MLB, and new localizations in the elbows and knees have been identified. We review the literature concerning distal forms of MLB, and compare the features. This disease is an interesting new differential diagnosis of acromelic arthritis.*

### Introduction

Madelung-Launois-Bensaude disease (MLB), or acquired benign symmetrical lipomatosis, is defined as the presence of symmetrical fatty accumulations in the neck and upper trunk (1). It is an uncommon disorder or may be under-diagnosed (2). It affects adults (30-60 years old), predominantly men of Mediterranean populations (1). A high alcohol consumption is present in most cases (3). A few cases have been described in patients treated with corticosteroids, (4) or with metabolic diseases (hyperuricemia, lipids and insulin disorders, hypothyroidism, hypertension, renal tubular acidosis) (3).

There are three main phenotypes, more than one of which can be present in the same patient: type I, affecting men, with symmetrical, non-tender, accumulation of unencapsulated mature fatty tissues on proximal upper parts of the body, giving a pseudoathletic appearance. Extension to surrounding structures can happen: mediastinal involvement with compression of trachea, vena cava, nerves and aerodigestive tract causing dyspnoea and dysphagia (2), macroglossia (5); type II, affecting both sexes, with deposits located diffusely over the body including proximal lower part, giving an appearance of simple obesity, and no mediastinal complications; (2) type III, with a preponderance in thigh girth ("gynecoid type") (6).

MLB can be associated with specific

neuropathy (2), differing histologically from alcoholic complications (7).

Once fat is present, it usually does not disappear (8). Stopping the alcohol intoxication may allow stabilization of the disease (9). Only one case of malignant transformation has been reported (10). However, a thorough evaluation is recommended, because of the increased susceptibility of these patients to malignancies and mortality, attributed to alcohol (2, 11, 12).

The diagnosis is made by examination and confirmed by ultrasonography, CT scan or MRI. Histologic examination is generally not necessary. Extremities are usually not affected (3).

We report a case of MLB displaying unusual tissue distribution, which was initially misdiagnosed as acromelic arthritis.

### Case report

A 63-year-old woman was referred for a suspicion of acromelic arthritis. She was complaining of pain in her hands and knees and secondarily of progressively symmetrical swelling of limbs over seven years. She had a medical past history of alcoholism and hypothyroidism. Physical examination revealed a plethoric patient (BMI = 29.3 kg/m<sup>2</sup>), with mechanical pains in her knees, trapezo-metacarpal and distal interphalangeal joints. However, she presented with an unusual podgy aspect of the hands, with protrusive subcutaneous tumours predominantly located on the dorsal and palmar faces of carpa, and the first and second phalanges. Those tumours were symmetrical, painless, with a consistence suggestive of lipomas. The finger movements were not impaired. The same lesions were detected on the dorsal surface of feet and toes, elbows, shoulders and anterior face of knees (Fig. 1). Biological tests showed elevated gamma GT (283 UI/l, NR 7-38), hypertriglyceridemia (2.91 mmol/l, NR 0.6-1.70), hyperuricemia (407 µmol/l, NR 150-360), normal blood cell count, erythrocyte sedimentation rate, C-reactive protein and thyreostimuline hormone. Radiographs of joints showed osteoarthritis in the painful sites.

We evoked the diagnosis of MLB disease in spite of the unusual distal involvement. CT scan confirmed the presence

Competing interests: none declared.

of subcutaneous unencapsulated mass of normal-appearing fatty tissue (Fig. 2). We treated the osteoarthritis, which was the main complaint, and advised the patient to eliminate alcohol.

### Discussion

In this patient, the extensive proximal and distal localization of adipose tissue excess was highly unusual.

Reviewing the literature, only 4 other cases of distal MLB have been described (3 of hands: (13-15) and 1 of feet (16)) (Table I).

Although rare, distal forms appear to be more frequently reported in women (3/5), whereas classic proximal forms principally affect men (11). Hands are more frequently involved than feet (4/5 versus 2/5). The mean age is 54 years. The most frequent ethnic origin is Caucasian, but Black and Japanese people can be affected. The mean duration between the onset of the disease and the diagnosis is 2.6 years, suggesting difficulties in diagnosis and a good tolerance by the patients. Palmar and dorsal hands can be affected as well as plantar and dorsal feet. Distal phalanges appear to be spared. Compressive complications were never reported. Alcoholism was found to be associated in all cases except one. The second most frequent associated factor was thyroid dysfunction, present in two patients (15). Disturbances of GGT and transaminases were frequently associated, possibly due to alcohol. Dyslipidaemia was detected in two cases (present case (16)). Lipsker *et al.* described a case of distal benign symmetrical lipomatosis and challenged the diagnosis of MLB, because of its purely proximal nature in the initial description. However, whatever the name, the review of those cases suggests that they belong to the same entity based on similarities regarding adipose tissue distribution, precipitating factors and evolution. Distal forms may represent a new phenotypic variant of MLB. Our case displays three original features: it is the first describing the presence of lesions in both hands and feet, and the first associating proximal and distal lesion at the same time. Moreover, it describes new intermediate localisations in elbows

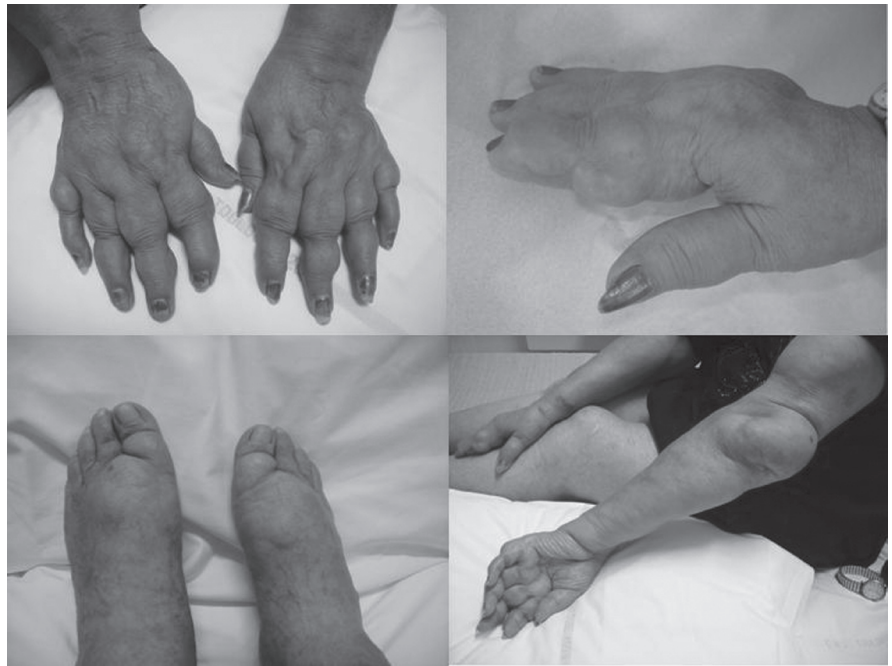

Fig. 1. Clinical aspect of hands, feet and elbows.

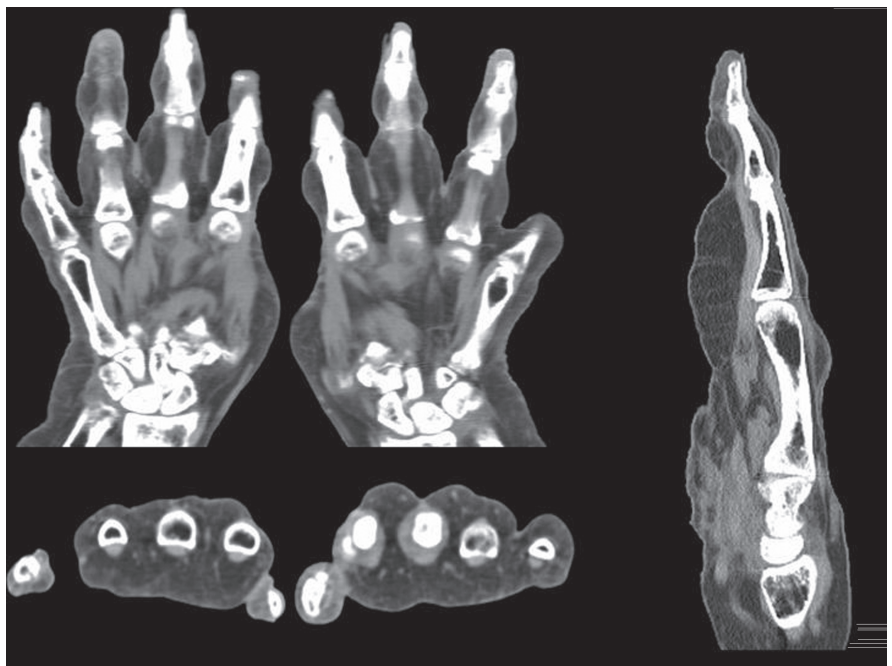


Fig. 2. CT scan of the hands: presence of subcutaneous unencapsulated fatty tissue.

and knees. Thus, this case could be the missing link between purely proximal and distal types.

The aetiology of MLB remains obscure. Association with alcoholism, and other metabolic diseases is frequent, however a causal relationship has not been established, indicating that MLB may be a syndrome with various underlying causes. Several theories have tried to

explain the uncontrolled proliferation, but none has been satisfying.

Due to the limited etiological insights, attempt of treatments are often disappointing. Abstinence from alcohol and treatment of other metabolic problems are recommended to avoid the progression of the disease, but are ineffective in its regression. The main treatment is surgical ablation of the fat (9) or

Table I. Cases of distal MLB.

	Site	Sex	Age	Ethnic group	Date of onset	Topography	Presumed cause	Metabolic abnormalities	Diagnosis confirmation
Case 1 Findlay <i>et al.</i> (15)	Hands	M	55	Black Bantu	6 months	Palmar, all digits, sparing distal phalanges	Alcohol	-Transaminases -GGT	Biopsy
Case 2 Lipsker <i>et al.</i> (14)	Hands	F	56	White	10 years	-Palmar, all digits, only first phalange -Dorsal, interpalmar	-Alcohol, -Systemic cortico-therapy	N	CT scan
Case 3 Yamamoto <i>et al.</i> (12)	Hands	F	62	Japanese	6 months	Dorsal surface of digits	Hashimoto's disease	N except antithyroid antibodies	Biopsy
Case 4 Requena <i>et al.</i> (16)	Feet	M	36	White	5 years	Plantar, big toe and medial surface of feet	Alcohol	-GGT -Cholesterol -TG	Biopsy
Case 5 Present case	Hands Feet Elbows Knees Shoulders	F	63	White	7 years	-Palmar and dorsal hands, sparing distal phalanges -Plantar and dorsal feet	-Alcohol -Treated hypothyroidism	-GGT -TG -Uricemia	-US -CT scan

N: Normal; GGT: Gamma GT; TG: Triglycerides; US: ultrasound; CT: Computed tomography.

liposuction (17), but only if the patient complains of aesthetic deformity or in the case of compressive complications, since the risk of recurrence is high.

## Conclusion

We describe a new distal phenotype of MLB, initially misdiagnosed as acromelic arthritis. This is the first description of distal MLB involving hands and feet, associated with a proximal form of the disease, also including intermediate lesions of elbows and knees. Classical predisposing factors for MLB were present. Clinical manifestations did not need any other treatment other than eliminating alcohol consumption. A better understanding of the etiopathological mechanism is required for an effective treatment.

## References

- GONZALEZ-GARCIA R, RODRIGUEZ-CAMPO FJ, SASTRE-PEREZ J, MUNOZ-GUERRERA MF: Benign symmetric lipomatosis (Madelung's disease): case reports and current management. *Aesthetic Plast Surg* 2004; 28: 108-12.
- PARMAR C, BLACKBURN C: Madelung's disease: an uncommon disorder of unknown aetiology? *Br J Oral Maxillofac Surg* 1996; 34: 467-70.
- ENZI G, INELMEN EM, BARITUSSIO A, DORIGO P, PROSDOCIMI M, MAZZOLENI F: Multiple symmetric lipomatosis: a defect in adrenergic-stimulated lipolysis. *J Clin Invest* 1977; 60: 1221-9.
- SORHAGE F, STOVER DE, MORTAZAVI A: Unusual etiology of cough in a woman with asthma. *Chest* 1996; 110: 852-4.
- KATOU F, SHIRAI N, MOTEGI K, SATOH R, SATOH S: Symmetrical lipomatosis of the tongue presenting as macroglossia. Report of two cases. *J Craniomaxillofac Surg* 1993; 21: 298-301.
- CALABRESI PA, SILVESTRI G, DI MAURO S, GRIGGS, RC: Ekbom's syndrome: lipomas, ataxia, and neuropathy with MERRF. *Muscle Nerve* 1994; 17: 943-5.
- POLLOCK M, NICHOLSON GI, NUKADA H, CAMERON S, FRANKISH P: Neuropathy in multiple symmetric lipomatosis. Madelung's disease. *Brain* 1988; 111: 1157-71.
- HUGO NE, CONWAY H: Benign symmetric lipomatosis: a case report. *Plast Reconstr Surg* 1966; 37: 69-71.
- BOOZAN JA, MAVES MD, SCHULLER DE: Surgical management of massive benign symmetric lipomatosis. *Laryngoscope* 1992; 102: 94-9.
- TIZIAN C, BERGER A, VYKOUPIK KF: Malignant degeneration in Madelung's disease (benign lipomatosis of the neck): case report. *Br J Plast Surg* 1983; 36: 187-9.
- RUZICKA T, VIELUF D, LANDTHALER M, BRAUN-FALCO O: Benign symmetric lipomatosis Launois-Bensaude. Report of ten cases and review of the literature. *J Am Acad Dermatol* 1987; 17: 663-74.
- LUSCHER NJ, PREIN J, SPIESSL B: Lipomatosis of the neck (Madelung's neck). *Ann Plast Surg* 1986; 16: 502-8.
- YAMAMOTO K, ICHIMIYA M, HAMAMOTO Y, MUTO M: Benign symmetrical lipomatosis of the hands. *J Dermatol* 2000; 27: 748-9.
- LIPSKER D, GARNIER C, DJERIDI N, GANJI A: [Symetric lipomatosis of the hands]. *Ann Dermatol Venereol* 2002; 129: 1159-60.
- FINDLAY GH, DUVENAGE M: Acquired symmetrical lipomatosis of the hands--a distal form of the Madelung-Launois-Bensaude syndrome. *Clin Exp Dermatol* 1989; 14: 58-9.
- REQUENA L, HASSON A, ARIAS D, MARTIN L, BARAT A: Acquired symmetric lipomatosis of the soles. A plantar form of the Madelung-Launois-Bensaude syndrome. *J Am Acad Dermatol* 1992; 26: 860-2.
- CARLIN MC, RATZ JL: Multiple symmetric lipomatosis: treatment with liposuction. *J Am Acad Dermatol* 1988; 18: 359-62.