

Sensory-motor axonal multineuropathy during etanercept therapy for rheumatoid arthritis

Sirs,

A 48-year-old woman had a 4-month history of polyarthritis without extra-articular features and particularly without skin lesions or neurologic impairment. Laboratory data showed RF at 203 IU/ml and elevated inflammatory markers while anti-CCP, ANA, ds-DNA, anti-ENA, APA, ANCA, serum complement and immunoglobulin levels were normal. Serology for recent infection was negative. X-rays of the wrists, hands and feet showed juxta-articular osteoporosis. These features were consistent with highly active early RA, refractory to treatment including prednisone (12.5 mg/die), NSAIDs and intraarticular injections of triamcinolone-acetonide. To achieve a rapid disease control with a monotherapy, etanercept (25 mg twice a week) without DMARDs was added to prednisone. About 2 months after initiating therapy, polyarthritis was uncontrolled. In addition she reported a burning sensation in the feet and asymmetric paroxysmal dysesthesia involving the legs. Methotrexate (MTX) was added (15 mg weekly). The patient achieved a reduction of the swollen and tenderness joint count. However, dysesthesia worsened, became chronic and symmetric in the lower limbs and spread asymmetrically in the upper limbs. Furthermore, the patient had developed severe motor distal deficit particularly in the lower limbs. The electromyographic pattern was compatible with a sensory-motor axonal multi-polyneuropathy. RF was raised at 445 IU/ml while serum complement, immunoglobulin levels, anti-CCP, ANA, anti-dsDNA, anti-ENA, APA, ANCA, anti-ganglioside, anti-myelin protein and anti-cerebellum were normal. Anti-PPD, anti-HIV, anti-Borrelia and serological hepatitis markers were negative. Investigations by PCR for HSV-1 and HSV-2 DNA, Cytomegalovirus DNA and Epstein-Barr virus DNA on blood were negative. Biopsy specimens were taken from the left sural nerve. Histological analysis showed axonal neuropathy without vascular inflammatory infiltrate (Fig. 1). Etanercept and MTX were discontinued and prednisone was increased (50 mg/die). Moreover, monthly plasma exchange followed by intravenous cyclophosphamide therapy (500mg/m²) and monthly therapy with high doses of intravenous Ig (400 mg/kg/die for 3 days) were given. Within 2 months the patient achieved a progressive improvement in the neurological features. Follow-up investigations 3 months later showed further improvement in the neuropathy.

Our patient had a sensory-motor axonal multi-neuropathy suggesting vasculitic

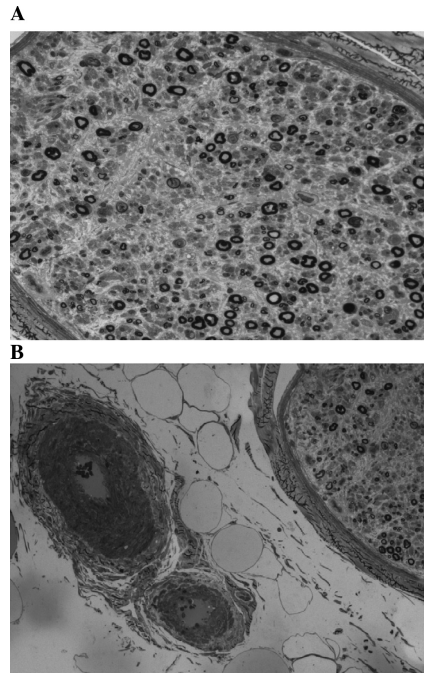


Fig. 1. A: Atrophy and axonal degeneration: a cross semithin section of sural nerve stained with toluidine bleu demonstrating myelinated fiber loss (residual density 1985/mm²) more evident in centronuclear area (x200); B: Semi-thin section of sural nerve stained with toluidine bleu no showed vasculitic changes in large perineural vessel (x100).

pathogenesis although histological analysis of nerve sample were characterised by absence of vascular inflammatory infiltrate. Some histological changes as pronounced multifocal myelinated fiber loss, more evident in centronuclear area, typically are seen in ischemic damage. On the contrary, the electromyographic and histological patterns exclude a demyelinating neuropathy (Guillain-Barré syndrome, etc.). We cannot definitely exclude the development of rheumatoid vasculitis-associated multineuropathy refractory to etanercept and MTX therapy. However, our patient did not have characteristics predisposing her to the development of rheumatoid vasculitis, particularly nodularity and skin lesions. On the contrary, the temporal relationship between the onset of neuropathy and the initiation of etanercept therapy suggest that the drug may have contributed to trigger the neurological disease.

While some reports have suggested that inhibition of TNF- α may be effective in rheumatoid vasculitis-associated mononeuritis (1-2), others have suggested that anti-TNF- α can induce, in patients with RA, the development of vasculitis (3-6) and particularly necrotizing vasculitis-associated sensory and motor neuropathy (7-8) or the progression of rheumatoid vasculitis-associated mononeuritis multiplex (8). There are a number of possible drug-related mechanisms that may be involved, immunopathogenic mechanism or infectious complications. In our case the

onset of multineuropathy was not associated with the production of autoantibodies and there were no signs of neurotoxic infective complications. Future studies should help to define the role of anti-TNF- α in the development of vasculitis and, particularly, in the development of axonal multineuropathy. Undoubtedly, an inflammatory axonal neuropathy may develop in patients with RA treated with anti-TNF- α . This possibility demand careful neurological monitoring in such patients and prompts us to suggest, in agreement with Richette (9) and Guillevin (10), the use of anti-TNF- α only in patients with vasculitis refractory to steroids and immunosuppressant agents.

R. DE STEFANO¹, MD
E. FRATI², Researcher
N. VOLPI³, Researcher
M. GALEAZZI³, Professor

¹U.O.C. of Rheumatology, Department of Specialistic Medicine, Azienda Ospedaliera Universitaria Senese, Siena; ²Department of Clinical Medicine and Immunological Sciences, Institute of Rheumatology, ³Department of Biomedical Sciences, Institute of Anatomy and Histology, University of Siena, Siena, Italy.

The work should be attributed to the Department of Clinical Medicine and Immunological Sciences, Institute of Rheumatology, University of Siena, Siena, Italy.

Author correspondence and reprint requests to: Renato De Stefano, viale Bracci 1, Siena, Italy. E-mail: donamara2006@libero.it

Competing interests: none declared.

References

1. RICHTER C, WANKE L, STEINMETZ C, REINHOLD-KELLER E, GROSS WL: Mononeuritis secondary to rheumatoid arthritis responds to etanercept. *Rheumatology* 2000; 39:1436-7.
2. ARMSTRONG D, MCCARRON MT, WRIGHT GD: Successful treatment of rheumatoid vasculitis-associated foot-drop with infliximab. *J Rheumatology* 2005; 32: 759.
3. JARRETT SJ, CUNNANE G, CONAGHAN PG *et al.*: Anti-Tumor Necrosis Factor-alpha therapy-induced vasculitis: case series. *J Rheumatol* 2003; 30: 2287-91.
4. GALARIA NA, WERTH VP, SCHUMACHER HR: Leukocytoclastic vasculitis due Etanercept. *J Rheumatol* 2000; 27: 2041-4.
5. LIVERMORE PA, MURRAY KJ: Anti-tumor necrosis factor therapy associated with cutaneous vasculitis. *Rheumatology* 2002; 41: 1450-2.
6. CUNNANE G, WARNOCK M, FYE KH, DAIKH DI: Accelerated nodulosis and vasculitis following etanercept therapy for rheumatoid arthritis. *Arthritis Rheum* 2002; 47: 445-9.
7. RICHETTE P, DIEUDE P, DAMIANO J, LACROIX C, LIOTE F, ORCEL P, BARDIN T: Sensory neuropathy revealing necrotizing vasculitis during infliximab therapy for rheumatoid arthritis. *J Rheumatol* 2004; 31: 2079-81.
8. RODRIGUEZ-ESCALERA C, BELZUNEGUI J, LOPEZ-DOMINGUEZ L, GONZALES C, FIGUEROA M: Multifocal motor neuropathy with conduction block in a patient with rheumatoid arthritis on infliximab therapy. *Rheumatology* 2005; 44: 132-3.
9. RICHETTE P, BARDIN T: Reply. *J Rheumatol* 2005; 32: 759.
10. GUILLEVIN L, MOUTHON L: Tumor necrosis factor-alpha blockade and the risk of vasculitis. *J Rheumatol* 2004; 31: 1885-7.