

Case report

Exuberant calcinosis and acroosteolysis. A diagnostic challenge

M.J. Saavedra¹, C. Ambrosio¹, A. Malcata¹, M. Matucci-Cerinic², J.A.P. Da Silva¹

¹Serviço de Reumatologia, Hospitais da Universidade de Coimbra, Portugal;

²Department of BioMedicine, Denothe Center, Division of Rheumatology, University of Florence, Italy.

Maria João Saavedra, MD

Catarina Ambrosio, MD

Armando Malcata, MD

Marco Matucci-Cerinic, MD, PhD

José Antonio P. Da Silva, MD, PhD

Please address correspondence to:

Marco Matucci-Cerinic,

Department of Biomedicine,

Division of Rheumatology,

Villa Monna Tessa,

viale Pieraccini 18,

50139 Firenze, Italy,

E-mail: cerinic@unifi.it

Received on June 25, 2009; accepted in revised form on July 17, 2009.

Clin Exp Rheumatol 2009; 27 (Suppl. 54): S55-S58.

© Copyright CLINICAL AND

EXPERIMENTAL RHEUMATOLOGY 2009.

Key words: Acroosteolysis, calcinosis, systemic sclerosis, skin involvement.

ABSTRACT

A case of exuberant acroosteolysis and subcutaneous tissue calcinosis in the absence of skin involvement is presented. Different hypotheses are discussed following the clinical unfolding of the case in practice.

Introduction

Acroosteolysis and calcinosis are a neglected problem in rheumatic diseases. We herein discuss and analyse a case presented over three vignettes.

Case vignette I

A 71-year-old female, presented with bilateral arthralgia and swelling of the wrists, MCPs, PIP, DIP and MTP joints evolving with variable intensity for fifteen years. She described typical bilateral Raynaud's phenomenon over the past four years, but denied any other relevant signs or symptoms.

The joints were tender and presented bony nodules that were inflamed over the right elbow and ankle. Facial telangiectasias (Fig. 1) were noted and no fibrosis was detectable on the hands (Fig. 2). General examination was normal.

X-rays revealed acroosteolysis in the hands (Fig. 3A) the knees, feet and Achilles tendon (Figs. 3B, C, D).

Discussion

Acroosteolysis consists of the resorption of bone extremities, more frequently the distal phalanxes.

It may be part of primary familial syndromes, which tend to follow an autosomal hereditary pattern. Acroosteolysis of distal phalanxes is usually found in all these conditions (Table I) but may also be accompanied by other bone modifications not seen in our patient.

Acroosteolysis may also develop as a result of local repetitive trauma (thermal, electrical and mechanical) or peripheral ischemia. It has been reported

to affect 1 to 3% of people chronically exposed to vinyl chloride (9).

It has been described in association with a variety of cutaneous diseases (psoriasis, leprosy, bullous epidermolysis, cutaneous porphiria, sífilis and pitiríasis rubra), metabolic diseases (gout, hyperparathyroidism, osteomalacia and diabetes mellitus) and neurological conditions (syringomyelia and sympathetic reflex dystrophy). Occasionally, acroosteolysis has been interpreted as a secondary manifestation to tumours, such as lung cancer, Sésary's syndrome and lymphoma (9).

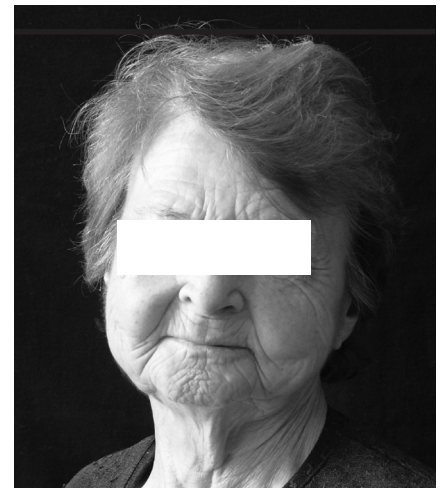

Fig. 1. Teleangiectasias are visible on the face of the patient.

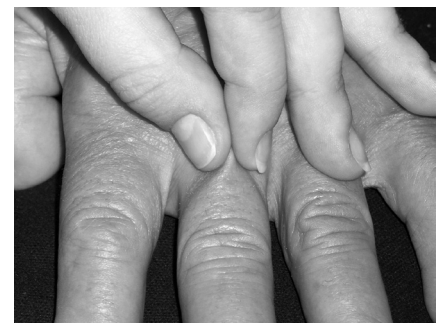

Fig. 2. The digits did not present edema or fibrosis; the skin can be pinched without any problem.

Competing interests: none declared.

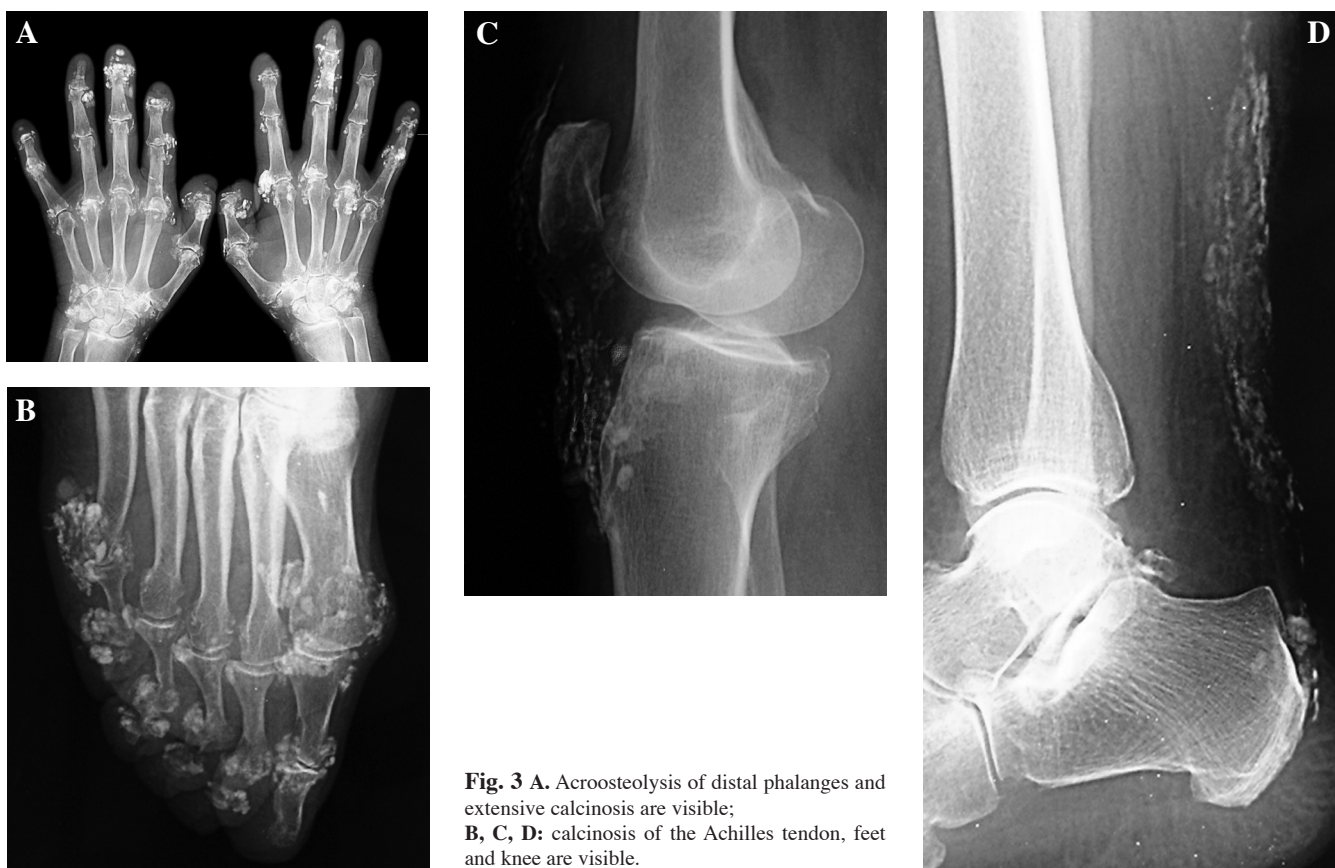

Fig. 3 A. Acroosteolysis of distal phalanges and extensive calcinosis are visible;
B, C, D: calcinosis of the Achilles tendon, feet and knee are visible.

More commonly, however, acroosteolysis is observed in patients with connective tissue diseases, with special emphasis on systemic sclerosis (SSc). However, patients with systemic lupus erythematosus, mixed connective tissue disease, Sjögren's syndrome, rheumatoid and psoriatic arthritis and sarcoidosis can also present resorption of distal and proximal phalanges (9-11).

Tissue calcinosis (deposition of insoluble calcium salts in soft tissues) can occur as a result of hypercalcemia, usually in the context of hyperparathyroidism. In idiopathic conditions, with normal circulating levels of calcium and phosphorus, nodular or milia-like deposits of calcium salts are found in the subcutaneous tissue (more commonly of the head or the extremities, the scrotum or

the periphery of joints). This situation affects young people or patients with Down's syndrome (12-13). However, in the absence of serum calcium abnormalities, calcinosis usually affects sites of previous lesions. This so called "dystrophic calcinosis" can be found in tumours and sites of trauma or infection but also in scarring tissue of patients with SLE, systemic sclero-

Table I. Hereditary syndromes causing distal phalanx osteolysis (1-8).

Condition	Hereditary pattern	Age at onset	Additional clinical features
Hadju-Cheney's syndrome	Dominant autosomal	Infancy	Cranial and facial anomalies; premature loss of teeth and micrognathia; short stature
Mandibucral syndrome	Recessive autosomal	Adolescence/young adulthood	Mandible and clavicle hypoplasia; cutaneous atrophy; lipodystrophy
Schinz disease	Dominant autosomal	Adolescence/ young adulthood	Recurrent finger ulcerations
Neurogenic acroosteolysis	Dominant or recessive autosomal	Childhood	Sensorial neuropathy; Mal perforans; vasomotor dysfunction; hyperhidrosis
Werner's syndrome	Recessive autosomal	Adolescence/ young adulthood	Precocious ageing; wrinkled skin; baldness; cataracts; muscular atrophy; diabetes mellitus
Pachydermoperiostosis (primary hypertrophic osteoarthropathy)	Recessive autosomal	Adolescents/adults	Finger clubbing, Periostosis, arthritis, seborrhoea, cutis verticis gyrata

sis, dermatomyositis, mixed connective tissue disease and Ehler-Danlos syndrome (12-16).

In summary, potential causes of concomitant acroosteolysis and tissue calcinosis appear to be limited to systemic sclerosis, SLE, mixed connective tissue disease and hyperparathyroidism.

Case vignette II

Laboratory evaluation showed normal full blood count and urinalysis, normal C-reactive protein (0.14mg/dl) and raised ESR (36mm). Serum calcium (9.4g/dl), phosphorus (3.7mg/dl), albumin (4.0g/dl), alkaline phosphatase (70U/L), parathormone (73.6 pg/ml) and thyroid hormones were all within the normal range.

Chest x-ray revealed a reticular pattern suggesting interstitial fibrosis (Fig. 4).

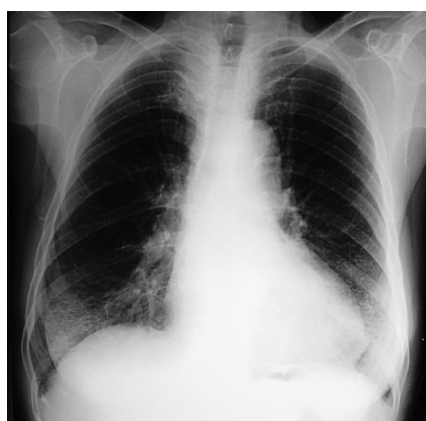

Fig. 4. Chest x-ray shows a reticular pattern.

Table II. Diagnostic criteria for systemic sclerosis *sine* scleroderma according to Poormoghim (21).

1. Raynaud's phenomenon or peripheral vascular equivalent (digital pitting scars, digital-tip ulcers, digital-tip gangrene or abnormal nail-fold capillaries)
2. AND
3. Positive antinuclear antibodies
4. PLUS one or more of the following
 - a. Distal oesophageal hypomotility
 - b. Small bowel hypomotility
 - c. Pulmonary interstitial fibrosis
 - d. Primary pulmonary arterial hypertension (without fibrosis)
 - e. Renal failure consistent with scleroderma renal crisis
 - f. Cardiac involvement typical of SS
5. Absence of any other connective tissue disease as a cause of 1, 2 or 3.

Hyperparathyroidism may be excluded on the basis of normal serum and urine calcium and phosphate, as well as serum parathormone. However, clinical criteria were missing for any connective tissue diseases.

Acroosteolysis makes SSc a major diagnostic hypothesis corroborated also by calcinosis. The major problem with this diagnosis in the present case is the absence of skin involvement and the late onset of Raynaud's phenomenon. The patient did not present other symptoms or signs that would reinforce this hypothesis, such as dyspnea or dysphagia.

The patient did not satisfy the ACR criteria for SSc classification which require the finding of either the sole major criterion (SSc proximal to metacarpophalangeal or metatarsophalangeal joints) or two or more of the minor criteria (sclerodactily, digital pitting scars, bibasilar pulmonary fibrosis) (17). Only one of the minor criteria was present in this case. Limitations of ACR criteria have been pointed out, especially regarding lack of sensitivity in limited cutaneous SSc subset (18). Abrams *et al.* described for the first time in 1954 a rare form of SSc (19) characterized by the presence of visceral manifestations without skin changes. The term SSc *sine* scleroderma (SSss) was coined in 1962 by Rodnan e Fennel (20). The largest case series, was published in 2000 (21) and included 48 cases of SSss representing 9% of 555 SSc patients. Based on this series, the authors proposed a set of diagnostic criteria for SSss (Table II).

Further investigations of our patient show that she satisfies these criteria.

Table III. Clinical and serologic comparison between SSc *sine* scleroderma and limited SSc according to Poormoghim (21).

	SSss	lcSS
ANA	94%	94%
Anti-centromere	31%	54%
Anti-RNA polymerase III	6%	1%
Other non-SSc associated antinuclear antibodies	44%	14%
Pulmonary involvement	68%	65%
Primary pulmonary arterial hypertension (PPAH)	23%	13%
PPAH as cause of death	52%	24%

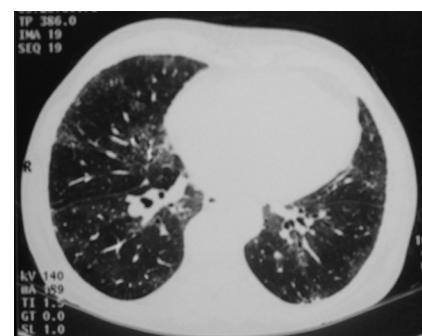


Fig. 5. Chest high resolution computed tomography shows the ground glass of lower lobes.

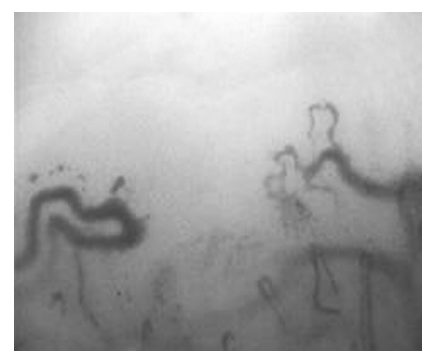

Fig. 6. Nailfold videocapillaroscopy: the pattern shows an avascular area.

Case vignette III

IgG rheumatoid factor (47 UI/ml, nephelometry), antinuclear antibodies (1:640 speckled and nucleolar pattern) and SSA were positive. While anti-centromere, anti-topo I or anti-RNP antibodies were negative.

Chest high-resolution CT-scan revealed areas of ground-glass in the lower lobes (Fig. 5). Respiratory function tests revealed a reduced alveolar diffusion (DLCO/VA – 66.6%). Oesophageal manometry was normal. Cardiac echocar-

diography did not detect increase in mean pulmonary pressure.

Capillaroscopy showed dysmorphic capillaries, megacapillaries, avascular areas and haemorrhages (22) (Fig. 6).

Poormoghim's series suggests that anti-centromere antibodies are less frequent in SSs than in the typical limited SSs subset, whereas other antibodies usually not related to SSs are more frequently present (Table III). The prevalence of pulmonary hypertension was higher in the SSs being the most frequent cause of death.

In 2002, Slobodin *et al.* (23) suggested the recognition of two different types of SSs. Some patients present with Raynaud's phenomenon, oesophageal dysmotility and antinuclear antibodies in the absence of previous connective tissue disease of any sort. Such cases, which represented the majority of Poormoghim's series, could be seen as incomplete forms of limited SSs and had a good prognosis. In other patients, features of SSs develop in the context of a previous undifferentiated connective tissue disease. This condition may be associated with a more aggressive course and SSs can be expected to appear in up to 60% of cases in the first 7 years. This latter pattern could be seen as SSs *before* (rather than *sine*) the onset SSs.

Our case seems to fit best in the first pattern even if it does not fulfil the ACR SSs criteria (17, 18). Although SSs is a lethal disease (24), the visceral involvement can be considered benign until now. This is in contrast with a very aggressive arthritis and exquisitely exuberant calcinosis and acroosteolysis, without skin involvement, twelve years after the onset of first symptoms of disease.

It is interesting to note that, in our patient, Raynaud's phenomenon started eight years after the proven onset of

acroosteolysis. This would question the view according to which acroosteolysis in SSs is an ischemic consequence (10). Calcinosis has been proposed as a potential factor for acroosteolysis through induction of subchondral bone infarction (9, 10).

In conclusion, this case points out the importance of acroosteolysis and calcinosis as two important clinical signs that should induce the clinician to carefully analyse the whole case in order to best perform the differential diagnosis in the field of rheumatic, metabolic and congenital diseases.

References

1. SZOKE G, VIZKELETY TL, RÉNYI-VAMOS A, ELEK E: Idiopathic carpotarsal osteolysis with Barter's syndrome. *Clin Orthop Relat Res* 1995; 310: 120-9.
2. BRENNAN AM, PAULI RM: Hajdu-Cheney syndrome: evolution of phenotype and clinical problems. *Am J Med Gen* 2001; 100: 292-310.
3. FAURE A, DAVID A, MOUSSALLY F *et al.*: Hajdu-Cheney syndrome and syringomyelia – case report. *J Neurosurg* 2002; 97: 1441-6.
4. DRAKE WM, HIRNS MP, KENDLER DL: Hajdu-Cheney syndrome: response to therapy with bisphosphonates in two patients. *J Bone Min Res* 2003; 18: 131-3.
5. RAMOS FJ, KAPLAN BS, BELLAH RD, ZACKAI EH, KAPLAN P: Further evidence that the Hajdu-Cheney syndrome and the "Serpentine fibula-polycystic kidney syndrome" are a single entity. *Am J Med Gen* 1998; 78: 474-81.
6. ANTONIADES K, KAKLAMANOS E, KAVADIA S, HATZISTILIANOU M, THESSALONIKI VA: Hajdu-Cheney syndrome (acroosteolysis): a case report of dental interest. *Oral Surg Med Pathol* 2003; 6: 725-31.
7. AGARWAL AK, FRYNS J-P, AUCHUS RJ, GARG A: Zinc metalloproteinase, ZMP-STE24, is mutated in mandibuloacral dysplasia. *Hum Mol Gen* 2003; 12: 1995-2001.
8. MATUCCI CERINIC M, LOTTI T, JAJIC I, PIGNONE A, BUSSANI C, CAGNONI M: The clinical spectrum of Pachydermoperiostosis. *Medicine* 1991; 70: 280-6.
9. KEMP SS, DALINKA MK, SCHUMACHER R: Acroosteolysis – Etiologic and radiological considerations. *JAMA* 1986; 255: 2058-61.
10. COHEN MG, HO KK, WEBB J: Finger joint calcinosis followed by osteolysis in a patient with multisystem connective tissue disease and anti-Jo-1 antibody. *J Rheumatol* 1987; 14: 605-8.
11. ALFREY AC: The role of abnormal phosphorus metabolism in the progression of chronic kidney disease and metastatic calcification. *Kidney Int* 2004; 66 (Suppl. 90): 513-7.
12. WALSH JS, FAIRLEY JA: Calcifying disorders of the skin. *J Am Acad Dermatol* 1995; 33: 693-706.
13. TAN AW, NG HJ, ANG P, GOH YT: Extensive calcinosis cutis in relapsed acute lymphoblastic leukaemia. *Ann Acad Med Singapore* 2004; 33: 107-9.
14. FRIEDMAN JS, WALTERS RF, WOOSLEY J, FINE JD: A unique presentation of calcinosis cutis in a patient with cystic fibrosis after double lung transplants. *J Am Acad Dermatol* 2003; 49: 1131-6.
15. TAYLOR EN, HENDERSON JM, RENNKE HG, MAGEE CC: Traumatic calcinosis cutis in a dialysis patient. *Am J Kidney Dis* 2004; 44: 18-21.
16. ELLIS IO, FOSTER MC, WOMACK C: Plumber's knee: calcinosis cutis after repeated minor trauma in a plumber. *Br Med J (Clin Res Ed)* 1984; 288: 1723.
17. SUBCOMMITTEE FOR SCLERODERMA CRITERIA OF AMERICAN RHEUMATISM ASSOCIATION OF THE DIAGNOSTIC AND THERAPEUTIC CRITERIA COMMITTEE: Preliminary criteria for the classification of systemic sclerosis (scleroderma). *Arthritis Rheum* 1980; 23: 581-90.
18. HUDSON M, TAILLEFER S, STEELE R *et al.*: Improving the sensitivity of the American College of Rheumatology classification criteria for systemic sclerosis. *Clin Exp Rheumatol* 2007; 25: 754-7.
19. ABRAMS HL, CARNES WH, EATON J: Alimentary tract in disseminated scleroderma with emphasis on small bowel. *Arch Int Med* 1954; 94: 61-81.
20. RODMAN GP, FENNELL RH: Progressive systemic sclerosis sine scleroderma. *JAMA* 1962; 180: 665-70.
21. POORMOGHIM H, LUCAS M, FERTIG N, MEDSGER TA: Systemic sclerosis sine scleroderma. *Arthritis Rheum* 2000; 43: 444-51.
22. CUTOLO M, MATUCCI-CERINIC M: Nailfold capillaroscopy and classification criteria for systemic sclerosis. *Clin Exp Rheumatol* 2007; 25: 663-5.
23. SLOBODIN G, ROSNER I, ROZENBAUM M, NASCHITZ JE, ZUCHERMAN E, YESHURUN D: Systemic sclerosis sine scleroderma: is it always the same disease? Report of three patients and discussion. *Rheumatol Int* 2002; 22: 170-2.
24. KARASSA FB, IOANNIDIS JP: Mortality in systemic sclerosis. *Clin Exp Rheumatol* 2008; 26 (Suppl. 51): S85-93.