

## Synovial colony-stimulating factor-1 mRNA expression in diffuse pigmented villonodular synovitis

B. Molena<sup>1</sup>, P. Sfriso<sup>1</sup>,  
F. Oliviero<sup>1</sup>, E. Pagnin<sup>1</sup>,  
A. Teramo<sup>1</sup>, F. Lunardi<sup>2</sup>,  
R. Stramare<sup>3</sup>, A. Scanu<sup>1</sup>,  
R. Nardacchione<sup>4</sup>, L. Rubaltelli<sup>3</sup>,  
F. Calabrese<sup>2</sup>, L. Punzi<sup>1</sup>, U. Fiocco<sup>1</sup>

<sup>1</sup>Department of Clinical and Experimental Medicine, <sup>2</sup>Institute of Pathology, Department of Diagnostic Medical Sciences and Special Therapies,

<sup>3</sup>Department of Medical-Diagnostic Science and Special Therapies, University of Padova, Padova, Italy;

<sup>4</sup>Department of Orthopedics, Leonardo Foundation, Abano Terme General Hospital, Abano Terme, Italy.

Beatrice Molena, PhD  
Paolo Sfriso, MD, PhD  
Francesco Oliviero, PhD  
Elisa Pagnin, PhD  
Antonella Teramo, PhD  
Francesca Lunardi, PhD  
Roberto Stramare, MD, PhD  
Anna Scanu, PhD  
Roberto Nardacchione, MD  
Leopoldo Rubaltelli, MD, PhD  
Fiorella Calabrese, MD, PhD  
Leonardo Punzi, MD, PhD  
Ugo Fiocco, MD, PhD

Please address correspondence and reprint requests to:

Ugo Fiocco, MD, PhD,  
Rheumatology Unit,  
University of Padova,  
Via Giustiniani 2,  
35128 Padova, Italy.  
E-mail: ugo.fiocco@unipd.it

Received on November 16, 2010; accepted in revised form on January 13, 2011.

© Copyright CLINICAL AND EXPERIMENTAL RHEUMATOLOGY 2011.

**Key words:** colony-stimulating factor-1, synovial gene expression, real-time polymerase chain reaction, diffuse pigmented villonodular synovitis, persistent gonarthrosis

Competing interests: none declared.

## SUMMARY

**Objective.** To delineate the molecular mechanisms underlying the process of the diffuse-type giant cell tumours, also called pigmented villonodular synovitis, a rare, aggressive condition of the synovium, the knee synovial tissue expression of colony-stimulating factor-1 gene, as detected by real-time polymerase chain reaction, was compared between patients affected with pigmented villonodular knee synovitis and knee meniscal tears, or persistent gonarthrosis.

**Methods.** Multiple synovial biopsies of the knee were performed by arthroscopy in five consecutive patients affected by diffuse pigmented villonodular knee synovitis and in 12 patients affected by knee meniscal tears (n. 6) or persistent active gonarthrosis (n. 6), recruited from the patients attending the Rheumatology Day Surgery Outpatient Clinic of the University of Padova Hospital. The ethics committee approved the study protocol and the participants signed consent statements after being informed about the content of the study. The diagnosis was made on the basis of a histological examination.

The colony-stimulating factor-1 gene expression was assessed by reverse transcription followed by real-time polymerase chain reaction.

**Results.** The detection by RT-PCR of synovial colony-stimulating factor-1 mRNA showed a wide spectrum of expression in the three groups of distinct knee joint disease affected patients, with significantly higher level of colony-stimulating factor-1 mRNA expression in synovial tissue of pigmented villonodular synovitis, in comparison to that of knee meniscal injuries and persistent gonarthrosis patients.

**Conclusions.** Our findings point out to an important role of colony-stimulating factor-1 in pigmented villonodular knee synovitis disease process and support the idea that colony-stimulating factor-1/colony-stimulating factor-1 receptor interaction may represent a potential therapeutic target of this disease.

## Introduction

Tenosynovial giant cell tumours (TS-GCT) are benign mesenchymal tumours of the synovial lining. Diffuse-type gi-

ant cell tumours, also called pigmented villonodular synovitis (PVNS), is a rare, predominantly intra-articular and aggressive infiltrative condition of the synovium primarily affecting large joints (1, 2). Histologically, PVNS consists of synovial-like histiocytes and multinucleated giant cells (MGCs), lymphocyte infiltrates, siderophages and lipid-loaded macrophages (1, 2). It has been reported that PVNS patients are at considerable risk of multiple local recurrence and of local destructive course.

The inflammatory nature of PVNS has been suggested by the immunohistochemical (IHC) marker expression by the synovial-like membrane consisting of areas containing monocyte/macrophages: CD68, CD163, CD55, matrix metalloproteinase (MMP) MMP-2,-9, colony-stimulating factor-1 (CSF-1), CSF-1 receptor (CSF-1R), receptor activator for nuclear factor  $\kappa$ B ligand (RANKL), typical of activated macrophages as well as the IHC phenotype of PVNS-MGCs: RANKL, CSF-1R, CD33, CD51, tartrate-resistant acid phosphatase (TRAP), calcitonin-receptor, characteristic of osteoclasts (3-8).

A neoplastic origin of TSGCTs has, instead, been supported by the finding of up-regulated telomerase activity, by the identification of DNA aneuploidy and of clonal karyotypic aberrations (4, 9, 10), and, more recently, by the observation of frequent chromosomal translocations involving CSF-1 locus and collagen type VI alpha-3 (COL6A3) genes in TSGCTs/D-TSGCT cells (11).

CSF-1 acts through CSF-1R, a tyrosine kinase receptor, encoded by the *c-fms* protooncogene (12), primarily expressed on mononuclear phagocytic cells (13). Up-regulation of CSF-1 has already been reported in chronic inflammatory diseases and in cancer (14-16).

The study was undertaken as part of a multidisciplinary collaborative study to explore new intraarticular therapeutic approach and synovial molecular targets in PVNS. To this end, the molecular mechanisms of synergic paracrine loop mediated by TNF- $\alpha$  and CSF1 were explored in both inflammatory and neoplastic conditions (17).

The present study was designed with the intent of delineating the mole-

cular mechanisms underlying the PVNS process by assessing CSF-1 messenger RNA (mRNA) expression in knee synovial tissue by real-time polymerase chain reaction (RT-PCR) and by comparing these values in patients affected with diffuse PVNS, with knee meniscal tears or persistent gonarthrosis.

### Patients and methods

Five consecutive patients affected with diffuse knee PVNS (the diagnosis was made on the basis of a histological examination) (5 knees) (4 male and 1 female) (age-range 20–35 years), characterised by persistent warmth, tenderness, swelling and effusion, proving to be resistant to repeat intraarticular corticosteroid injections, and six patients (6 knees) (4 male and 2 female) (age-range 38–51 years) affected with persistent active gonarthrosis despite undergoing >2 intraarticular corticosteroid injections during the year before (RM imaging showed diffuse knee joint synovial proliferation) were recruited from the patients attending the Rheumatology Outpatient Clinic of the University of Padova Hospital. All the patients were over 18 years of age. Six more consecutive patients over the age of 18 and affected with knee meniscal injuries (6 knees) (3 male and 1 female) (age-range 34–41 years), who were submitted to knee joint arthroscopic meniscectomy at the Multidisciplinary Outpatient Clinic of the University of Padova Hospital, were also studied (Table I).

The ethics committee approved the study protocol (Etanercept/TNR-001: n. 878P) and the participants signed consent statements after being informed about the content and methodology of the study.

### Synovial biopsy

Synovial biopsies of the knee were performed during arthroscopy carried out in our Department. The synovial specimens were obtained targeting the areas of intense synovial hyperemic proliferation. Multiple biopsy samples from each patient were preserved both in RNA-later and in paraformaldehyde and embedded en bloc in paraffin. Paraffin bloc sections (5 mm) were cut for histologic analysis. The synovial mem-

**Table I.** Clinical and demographic characteristics of patients affected with (A) diffuse pigmented villonodular knee synovitis, (B) persistent active gonarthrosis and (C) knee meniscal tears.

A) Patients affected with diffuse pigmented villonodular knee synovitis					
n.	Age	Sex	Side	Synovitis duration (years)	Disease duration (years)
1	35	F	L	4	12
2	30	M	L	4.5	4.5
3	32	M	R	4	8
4	31	M	L	5	5.8
5	20	M	L	2	2
mean	29.6			3.90	6.46
SD(±)	5.68			1.14	3.78
B) Patients affected with persistent active gonarthrosis					
n.	Age	Sex	Side	Gonarthrosis duration (years)	Disease duration (years)
1	44	M	L	11.5	13.5
2	40	F	L	8.9	9.1
3	40	F	L	8.9	9.1
4	44	M	L	11.5	13.5
5	51	M	L	5.7	22
6	38	M	R	6.4	8.4
mean	42.83			8.82	12.60
SD(±)	4.67			2.45	5.14
C) Patients affected with knee meniscal tears					
n.	Age	Sex	Side	Knee meniscal tears duration (years)	Disease duration (years)
1	40	F	L	2	4
2	41	M	R	1.8	3
3	34	F	L	2	2.9
4	36	M	L	1.5	3
5	35	M	R	1	1.4
6	38	F	R	3	4
mean	37.33			1.88	3.05
SD(±)	2.80			0.66	0.95

brane tissue specimens were stained with haematoxylin and eosin (H&E).

### Total RNA extraction

Total RNA was extracted from frozen biopsies using a commercially available kit (RNA Ble, RNA Extraction, Eurobio, France). The extracted RNA had a 280/260 OD ratio between 1.8 and 2.0 and RNA integrity was evaluated by agarose gel electrophoresis.

### Real-time PCR analysis of CSF-1 mRNA expression

Gene expression of the components of the CSF-1 was assessed by reverse transcription followed by real-time polymerase chain reaction (PCR; TaqMan; PE Applied Biosystems, Foster City, CA, USA). Briefly, RNA reverse transcription was performed using the Gene Amp RNA PCR Kit, essentially following the manufacturer's directions (Applied Biosystems, Foster City, CA,

USA). Briefly, RNA (~1 µg) was reverse transcribed using random hexamer primers and MuLV reverse transcriptase in a GeneAmp PCR System 2700 (Applied Biosystems) and in accordance with the following protocol: 15 min at 42°C, 5 min at 99°C and 5 min at 5°C.

Real-time polymerase chain reaction (RT-PCR) was carried out in an ABI Prism 7000 sequence detection system using TaqMan Universal PCR Master Mix, primers and probes mapping a common sequence of CSF-1 isoforms and glyceraldehyde 3-phosphate dehydrogenase (GAPDH) purchased from Applied Biosystems. After treatment with Uracil-N-Glycosylase (UNG) for 2 min at 50°C to minimise DNA contamination, and inactivation of this enzyme at 95°C for 10 min, the samples were amplified with the following protocol for 45 cycles: denaturation 95°C for 15 s, and annealing/extension 60°C for 1 min. Each PCR amplifica-

**Table II.** CSF-1 mRNA expression by real-time PCR in synovial knee joint specimens obtained in diffuse pigmented villonodular knee synovitis, persistent active gonarthrosis and knee meniscal tears affected patients. CSF-1 mRNA expression was estimated from the ratio of fluorescence intensity to GAPDH.

n.	CSF-1/GAPDHmRNA		
	Knee meniscal tears	Gonarthrosis	PVNS
1	0.97	14.05	22.91
2	8.71	18.98	25.14
3	0.84	17.87	24.61
4	0.76	13.13	22.98
5	1.85	18.3	25.44
6	7.94	16.39	
mean	3.51	16.45	24.22
SD(±)	3.76	2.39	1.20

tion was performed in duplicate. A pool of standard cDNA was used in a serial dilution of 1, 1:5, 1:25 and 1:125 for standard curves. A non-template (water) reaction mixture was prepared as a negative control. CSF-1 mRNA expression was estimated from the ratio of fluorescence intensity to GAPDH.

#### Statistical analysis

Statistical analysis was performed with SPSS software. Results were analysed using the non-parametric Kruskal-Wallis test. Pairwise group comparisons were made by Mann-Whitney test for

unpaired samples followed by Bonferroni correction (18). *P*-values <0.01 were considered significant.

#### Results

##### Histology

All the PVNS H&E stained synovial membrane tissue specimens showed moderate proliferation of the synovial lining, mononuclear cell infiltration, diffuse siderosis, intense stromal vascularity and extracellular matrix deposition.

##### Synovial CSF-1 mRNA expression

The detection by RT-PCR of synovial colony-stimulating factor-1 mRNA showed a wide spectrum of expression in the three groups of distinct knee joint disease affected patients, with significantly higher level of colony-stimulating factor-1 mRNA expression in synovial tissue of pigmented villonodular synovitis, in comparison to that of knee meniscal injuries and persistent gonarthrosis patients (Table II; Fig. 1).

#### Discussion

The results of this preliminary study are consistent with previous findings of high synovial CSF-1 expression by *in situ* hybridisation in PVNS patients (19, 20) and indicate that CSF-1 may also play a role in persistent inflammatory gonarthrosis (19, 20). Moreover, to

our knowledge, the direct comparison of CSF-1 expression between PVNS and meniscal injury or gonarthrosis, was previously unreported.

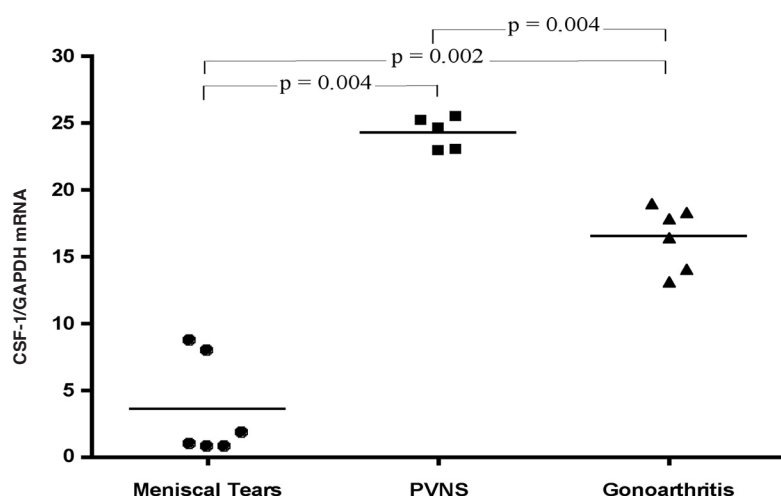
It was thought that the translocation of CSF-1 in PVNS limited to the neoplastic cells led to the recruitment of the majority of reactive non-neoplastic CD68<sup>+</sup> macrophages (11, 21, 22). The recent finding of high CSF-1 expression in translocation-negative PVNS patients implies that alternative mechanisms may lead to up-regulation of CSF-1 in these patients (23).

Synergistic activity of TNF- $\alpha$  and CSF-1 was found to be involved in monocyte activation, macrophage proliferation (24, 25) and osteoclast differentiation (26, 27). A paracrine synergistic loop, mediated by TNF- $\alpha$  and CSF-1 was indeed demonstrated in both inflammatory (20, 27, 28) and neoplastic conditions (16, 29), playing an important role in the regulation of differentiation/proliferation of mononuclear phagocytes and osteoclasts (26, 27), modulation of dendritic cells' (DCs) development and acceleration of angiogenesis and neo-vascularisation (29-32). Inflammatory or cancer cell-derived TNF- $\alpha$  has been shown, in fact, to stimulate TNF- $\alpha$  and CSF-1 production by macrophages, and CSF-1, in turn, induces macrophage VEGF-A and MMP-2 in an autocrine manner (16).

The exiguous number of patients studied by us is an important limitation of this study. Larger, controlled studies are, therefore, clearly warranted to further assess the clinical relevance of synovial CSF-1 in diffuse PVNS and the potential utility of CSF-1 mRNA expression as diagnostic biomarkers in the early phases of the disease.

Understanding the molecular pathways involved in the PVNS process will undoubtedly open the door to the development of new therapies targeting molecular alterations (33-35). Recent studies concerned with the biological effects of CSF-1 and of CSF-1R block (36-38) have produced promising findings both in inflammatory (39, 40) and neoplastic conditions (41-43).

Previous reports (11, 21, 22, 17), our preliminary findings concerning CSF-1 up-regulation in PVNS, and prelimi-



**Fig. 1.** CSF1-mRNA levels detected by real-time PCR in frozen samples of knee synovial tissues biopsies obtained from knee meniscal tears (n=6), gonarthrosis affected patients (n=6) and diffuse pigmented villonodular knee synovitis (n=5).

Results were analysed using the non-parametric Kruskal-Wallis test ( $p=0.0008$ ) followed by Mann-Whitney test with Bonferroni correction. All comparisons were statistically significant.

Horizontal lines represent mean value for each group.

CSF-1 mRNA expression was estimated from the ratio of fluorescence intensity to GAPDH.



nary data on imatinib for the systemic therapy of a patient with PVNS (44), seem to indicate that CSF1/CSF1R interaction may represent a potential therapeutic target.

## References

1. JAFFE HL, LICHTENSTEIN L, SUTRO CJ: Pigmented villonodular synovitis: bursitis and tenosynovitis. *Arch Pathol* 1941; 31: 731-65.
2. BYERS PD, COTTON RE, DEACON OW *et al.*: The diagnosis and treatment of pigmented villonodular synovitis. *J Bone Joint Surg Br* 1968; 50: 290-305.
3. YOSHIDA W, UZUKI M, KUROSE A *et al.*: Cell characterization of mononuclear and giant cells constituting pigmented villonodular synovitis. *Hum Pathol* 2003; 34: 65-73.
4. BERGER I, WECKAUF H, HELMCHEN B *et al.*: Rheumatoid arthritis and pigmented villonodular synovitis: comparative analysis of cell polyploidy, cell cycle phases and expression of macrophage and fibroblast markers in proliferating synovial cells. *Histopathology* 2005; 46: 490-7.
5. FINIS K, SULTMANN H, RUSCHHAUPT M *et al.*: Analysis of pigmented villonodular synovitis with genome-wide complementary DNA microarray and tissue array technology reveals insight into potential novel therapeutic approaches. *Arthritis Rheum* 2006; 54: 1009-19.
6. KOMANO Y, NANKI T, HAYASHIDA K, TANIGUCHI K, MIYASAKA N: Identification of a human peripheral blood monocyte subset that differentiates into osteoclasts. *Arthritis Res Ther* 2006; 8: R152.
7. GELDYYEV A, KOLEGANOVA N, PIECHA G *et al.*: High expression level of bone degrading proteins as a possible inducer of osteolytic features in pigmented villonodular synovitis. *Cancer Lett* 2007; 255: 2785-3.
8. FORSYTH RG, DE BOECK G, BAELDE JJ *et al.*: CD33<sup>+</sup> CD14<sup>+</sup> phenotype is characteristic of multinuclear osteoclast-like cells in giant cell tumor of bone. *J Bone Miner Res* 2009; 24: 70-7.
9. BRANDAL P, BJERKEHAGEN B, HEIM S: Molecular cytogenetic characterization of tenosynovial giant cell tumors. *Neoplasia* 2004; 6: 578-83.
10. MENDENHALL WM, MENDENHALL CM, REITH JD, SCARBOROUGH MT, GIBBS CP, MENDENHALL NP: Pigmented villonodular synovitis. *Am J Clin Oncol* 2006; 29: 548-50.
11. WEST BR, RUBIN BP, MILLER MA *et al.*: Landscape effect in tenosynovial giant-cell tumor from activation of CSF1 expression by a translocation in a minority of tumor cells. *Proc Natl Acad Sci USA* 2006; 103: 690-5.
12. SHERR CJ, RETTENMIER CW, SACCA R, ROUSSEL MF, LOOK AT, STANLEY ER: The c-fms protooncogene product is related to the receptor for the mononuclear phagocyte growth factor, CSF-1. *Cell* 1985; 41: 665-76.
13. ROTH P, STANLEY ER: The biology of CSF-1 and its receptor. *Curr Top Microbiol Immunol* 1992; 181: 141-67.
14. CHITU V, STANLEY ER: Colony-stimulating factor-1 in immunity and inflammation. *Curr Opin Immunol* 2006; 18: 39-48.
15. PIXLEY FJ, STANLEY ER: CSF-1 regulation of the wandering macrophage: complexity in action. *Trends Cell Biol* 2004; 14: 628-38.
16. ZINS K, ABRAHAM D, SIOUD M, AHARINEJAD S: Colon cancer cell-derived tumor necrosis factor- $\alpha$  mediates the tumor growth-promoting response in macrophages by up-regulating the colony-stimulating factor-1 pathway. *Cancer Res* 2007; 67: 1038-45.
17. FIOCCO U, SFRISO P, LUNARDI F *et al.*: Molecular pathways involved in synovial cell inflammation and tumoral proliferation in diffuse pigmented villonodular synovitis. *Autoimmun Rev* 2010; 9: 780-4.
18. ALTMAN DG: Practical statistics for medical research. London: Chapman and Hall, 1991: 211-2.
19. NAKANO K, OKADA Y, SAITO K *et al.*: Rheumatoid synovial endothelial cells produce macrophage colony-stimulating factor leading to osteoclastogenesis in rheumatoid arthritis. *Rheumatology* 2007; 46: 597-603.
20. PANIAGUA RT, CHANG A, MARIANO MM *et al.*: c-Fms-mediated differentiation and priming of monocyte lineage cells play a central role in autoimmune arthritis. *Arthritis Res Ther* 2010; 12: R32.
21. MOLLER E, MANDAHN N, MERTENS F, PANAGOPOULOS I: Molecular identification of COL6A3-CSF1 fusion transcripts in tenosynovial giant cell tumors. *Genes Chromosomes Cancer* 2008; 47: 21-5.
22. CUPP JS, MILLER MA, MONTGOMERY KD *et al.*: Translocation and expression of CSF1 in pigmented villonodular synovitis, tenosynovial giant cell tumor, rheumatoid arthritis and other reactive synovitides. *Am J Surg Pathol* 2007; 31: 970-6.
23. HUANG HY, WEST RB, TZENG CC *et al.*: Immunohistochemical and biogenetic features of diffuse-type tenosynovial giant cell tumors: the potential roles of cyclin A, P53, and deletion of 15q in sarcomatous transformation. *Clin Cancer Res* 2008; 14: 6023-32.
24. OSTER W, LINDEMANN A, HORN S, MERTELSMANN R, HERRMANN F: Tumor necrosis factor (TNF)- $\alpha$  but not TNF- $\beta$  induces secretion of colony stimulating factor for macrophages (CSF-1) by human monocytes. *Blood* 1987; 70: 1700-3.
25. BRANCH DR, TURNER AR, GUILBERT LJ: Synergistic Stimulation of Macrophage Proliferation by the Monokines Tumor Necrosis Factor-Alpha and Colony-Stimulating Factor 1. *Blood* 1989; 73: 307-11.
26. YAO Z, LI P, ZHANG Q *et al.*: Tumor necrosis factor-alpha increases circulating osteoclast precursor numbers by promoting their proliferation and differentiation in the bone marrow through up-regulation of c-Fms expression. *J Biol Chem* 2006; 281: 11846-55.
27. KOMANO Y, NANKI T, HAYASHIDA K, TANIGUCHI K, MIYASAKA N: Identification of a human peripheral blood monocyte subset that differentiates into osteoclasts. *Arthritis Res Ther* 2006; 8: R152.
28. KITAUURA H, ZHOU P, KIM HJ, NOVACK DV, ROSS FP, TEITELBAUM SL: M-CSF mediates TNF-induced inflammatory osteolysis. *J Clin Invest* 2005; 115: 3418-27.
29. DOUGLASS TG, DRIGGERS L, ZHANG JG *et al.*: Macrophage colony stimulating factor: not just for macrophages anymore! A gateway into complex biologies. *Int Immunopharmacol* 2008; 8: 1354-76.
30. ONO M: Molecular links between tumor angiogenesis and inflammation: inflammatory stimuli of macrophages and cancer cells as targets for therapeutic strategy. *Cancer Sci* 2008; 99: 1501-6.
31. EUBANK TD, GALLOWAY M, MONTAGUE CM, WALDMAN WJ, MARSH CB: M-CSF induces vascular endothelial growth factor production and angiogenic activity from human monocytes. *J Immunol* 2003; 171: 2637-43.
32. CURRY JM, EUBANK TD, ROBERTS RD *et al.*: M-CSF signals through the MAPK/ERK pathway via Sp1 to induce VEGF production and induces angiogenesis in vivo. *PLoS One* 2008; 3: e3405.
33. DEWAR AL, CAMBARERI AC, ZANNETTINO AC *et al.*: Macrophage colony-stimulating factor receptor c-fms is a novel target of imatinib. *Blood* 2005; 105: 3127-32.
34. GUO J, MARCOTTE PA, MCCALL JO *et al.*: Inhibition of phosphorylation of the colony-stimulating factor-1 receptor (c-Fms) tyrosine kinase in transfected cells by ABT-869 and other tyrosine kinase inhibitors. *Mol Cancer Ther* 2006; 5: 1007-13.
35. KUBOTA Y, TAKUBO K, SHIMIZU T *et al.*: M-CSF inhibition selectively targets pathological angiogenesis and lymphangiogenesis. *J Exp Med* 2009; 206: 1089-102.
36. BROWNLOW N, MOL C, HAYFORD C, GHAEM-MAGHAMI S, DIBB NJ: Dasatinib is a potent inhibitor of tumour-associated macrophages, osteoclasts and the FMS receptor. *Leukemia* 2009; 23: 590-4.
37. ANDO W, HASHIMOTO J, NAMPEI A *et al.*: Imatinib mesylate inhibits osteoclastogenesis and joint destruction in rats with collagen-induced arthritis (CIA). *J Bone Miner Metab* 2006; 24: 274-82.
38. EL HAJJ DIB I, GALLET M, MENTAVERRI R, SEVENET N, BRAZIER M, KAMEL S: Imatinib mesylate (Gleevec) enhances mature osteoclast apoptosis and suppresses osteoclast bone resorbing activity. *Eur J Pharmacol* 2006; 551: 27-33.
39. PANIAGUA RT, SHARPE O, HOPPE *et al.*: Selective tyrosine kinase inhibition by imatinib mesylate for the treatment of autoimmune arthritis. *J Clin Invest* 2006; 116: 2633-42.
40. D'AURA SWANSON C, PANIAGUA RT, LINDSTROM TM, ROBINSON WH: Tyrosine kinases as targets for the treatment of rheumatoid arthritis. *Nat Rev Rheumatol* 2009; 5: 317-24.
41. SCOTT DA, AQUILA BM, BEBERNITZ GA *et al.*: Pyridyl and thiazolyl bisamide CSF-1R inhibitors for the treatment of cancer. *Bioorg Med Chem Lett* 2008; 1: 4794-7.
42. PATEL S, PLAYER MR: Colony-stimulating factor-1 receptor inhibitors for the treatment of cancer and inflammatory disease. *Curr Top Med Chem* 2009; 9: 599-610.
43. SAGLIO G, KIM DW, ISSARAGRISIL S *et al.*: Nilotinib versus imatinib for newly diagnosed chronic myeloid leukemia. *N Engl J Med* 2010; 362: 2251-9.
44. BLAY JY, EL SAYADI H, THIESSE P, GARRET J, RAY-COQUARD I: Complete response to imatinib in relapsing pigmented villonodular synovitis/tenosynovial giant cell tumor (PVNS/TGCT). *Ann Oncol* 2008; 19: 821-2.