

Autologous stem cell transplantation in refractory paediatric Wegener's granulomatosis

Sirs,

Wegener's granulomatosis (WG) is a rare systemic granulomatous vasculitis of small to medium vessels, involving the upper and lower respiratory tract, and the kidneys. WG predominantly affects middle-aged adults, however, paediatric patients have been reported (1, 2). Prednisolone and cyclophosphamide (CY) are the mainstay of therapy and methotrexate (MTX) is used to maintain remission. Relapses are common in all age-groups and warrant research on new/alternative treatment-regimens (1, 2). Autologous stem-cell-transplantation (SCT) has the potential to eliminate auto-reactive lymphocytes and may be a therapeutic option in patients with autoimmune-disease (AID). SCT exerts a potent disease-arresting effect by reconstituting the immune-system with a "naïve" state (3). Over 700 patients with AID have been treated with SCT, some of which (35) were suffering from systemic vasculitis (4-6). In recent analyses (5, 6), clinical outcomes of 18 of these patients were investigated. Eight patients showed complete remission after SCT (44%), ten responded with partly remission (56%). Three patients had fatal complications (17%). Responses in WG patients were inconsistent. One patient (34 female)

responded to autologous SCT, while two patients (46 female, 18 male) responded incompletely (5-7). Thus, it remains to be investigated, under which circumstances SCT leads to a long-lasting stable remission.

We report a 16-year-old female patient with refractory WG. She was first diagnosed in 2007 at the age of 12, with granulomatous otitis, epistaxis, bilateral pulmonary lesions, and elevated inflammatory parameters (Fig. 1A/B). She initially responded to "classic" induction-therapy with CY-pulses and prednisolone, and was started on MTX maintenance-treatment (1, 2). Secondary to side-effects, she was switched to azathioprine and relapsed. CY was re-administered, using Fauci-protocols. High steroid-doses caused aseptic bone-necrosis (Fig. 1C), but remission was not obtained.

B lymphocytes and cANCA-autoantibodies play a central role in the pathophysiology of WG (8), and data from case reports and open-label-studies showed promising results with 70–100% remission-rates after B cell-depletion. Thus, in agreement with EULAR-recommendations (9), Rituximab (RTX) was applied and low-dose MTX was re-introduced. RTX induced temporary remission, but regardless of the absence of serum auto-antibodies and peripheral B lymphocytes, epistaxis and otitis re-occurred. Magnetic resonance imaging unveiled mastoid oedema, and maxillar-cavity-inflammation (Fig. 1D).

It has been reported that a subset of patients, in particular patients with significant

granuloma-formation, do not respond to B cell-depletion. Since germinal-center-like structures were observed in granulomatous lesions, therapy-resistance might be due to local plasma-cell-survival and autoantibody-production (8). T lymphocytes play an important role in granuloma-formation and T lymphocyte-directed therapies showed good effects in some reports (8). Thus, anti-TNF-treatment with infliximab was introduced; unfortunately without effects.

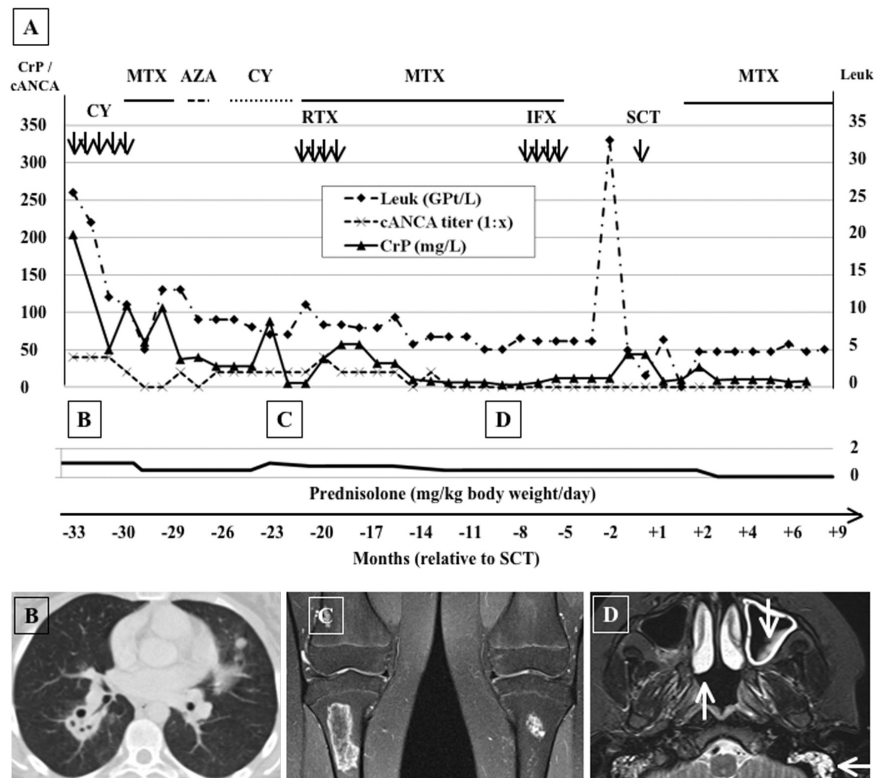
Secondary to chronic disease-progression, autologous SCT was performed to eliminate auto-reactive lymphocytes and re-introduce a "naïve" immune-system. Stem-cells were mobilized with CY (2g/m²) and G-CSF. The patient was conditioned with CY (5x50mg/kg) and anti-thymocyte globulin (3x20mg/kg). Ovarian function was preserved with gonadotropin-releasing-hormone analoga. Additionally, ovocytes were cryo-conserved. The graft was T-cell depleted by CD34⁺-selection (T-cell count <1x10⁵/kg) and 3.6x10⁶ CD34⁺ cells/kg were infused. Hematopoietic regeneration was observed at day +14 after SCT. Low-dose MTX was re-introduced to support stable remission and prevent reported re-development of auto-reactivity (4-6). Five months after SCT, our patient developed Escherichia coli-positive haemorrhagic cystitis. No further treatment-associated side-effects occurred during the 9-month follow-up. Currently, the patient is in stable remission. Thus, high dose immune-suppression, resulting in immune-ablation and followed by reconstitu-

Fig. 1. A) Laboratory findings and treatment applied in the course of a 12-year-old Wegener's granulomatosis (WG) patient. Leukocyte counts (Leuk), cANCA titers and CrP levels are displayed as markers of disease-activity. Induction-therapy was performed, using cyclophosphamide (CY) and oral prednisolone. Methotrexate (MTX) was administered as maintenance treatment. Secondary to side effects, azathioprine (AZA) was introduced. After a relapse, cyclophosphamide was re-administered orally and Rituximab® (RTX) in combination with methotrexate was started. Secondary to limited success Infliximab® (IFX) therapy was introduced, again with limited success. Stem cell transplantation (STC), followed by methotrexate maintenance-treatment was performed after 34 months of "classic" WG treatment and off-label use of biologicals. Stable remission was obtained after SCT. Time course is displayed as days relative to SCT.

B) Chest CT at the time of diagnosis, showing bilateral perihilar peribronchovascular nodules and partial cavitary masses with prominent walls.

C) PD-weighted MRI sequences of the knees with fat saturation, showing bone marrow oedema and osteonecrosis in the right femur and both tibiae.

D) MRI of the skull (TIRM-sequences) at month 23 after diagnosis. Swollen mucosa of the inferior conchae nasalis (↑), the left maxillary sinus (↓) and both mastoid cells (↔). No bone-destruction was detected.



tion with an "un-educated" immune-system by SCT was effective as rescue-therapy and resulted in stable remission.

To our knowledge, this is the first paediatric case of refractory WG, successfully treated with SCT. Early SCT might have reduced treatment-related side effects, such as aseptic bone-necroses. Based on previous reports, the efficacy of SCT in WG seems to be inconsistent (4-7). About 50% of patients responded with complete remission (5, 6), while 50% responded incompletely and/or relapsed (8). Even though the utilization and safety of SCT has evolved over the recent years, treatment-related morbidity still appears to be considerable in certain autoimmune diseases, such as systemic sclerosis (23%) (10). Refractory autoimmune-diseases have been the main target of SCT, although there is a tendency to treat systemic autoimmune-diseases in early stages to prevent multi-organ damage. Still, it is hard to predict the response to the considerably safe "classical" induction therapy with CY and prednisolone, followed by MTX maintenance treatment.

C.M. HEDRICH¹ M. BORNHÄUSER³
B. FIEBIG¹ M. GAHR¹
N. BRUCK¹ M. SUTTORP⁴
G. HAHN²

¹Paediatric Rheumatology and Immunology;
²Department of Radiology, Paediatric Radiology Section;
³Department of Haematology, Oncology and Hematopoietic Stem Cell Transplantation;
⁴Paediatric Haematology and Oncology, University Children's Hospital Dresden, Dresden, Germany.

Address correspondence to:
Dr Christian Hedrich, Paediatric Rheumatology and Immunology Section, University Children's Hospital Dresden, University of Technology Dresden, Fetscherstr. 74, D-01307 Dresden, Germany.
E-mail: christian.hedrich@uniklinikum-dresden.de
Competing interests: none declared.

References

1. CABRAL DA, URIBE AG, BENSELER S *et al.*; ARChiVe (A Registry for Childhood Vasculitis: entry) Investigators Network. Classification, presentation, and initial treatment of Wegener's granulomatosis in childhood. *Arthritis Rheum* 2009; 60: 3413-24.
2. BELOSTOTSKY VM, SHAH V, DILLON MJ: Clinical features in 17 paediatric patients with Wegener granulomatosis. *Pediatr Nephrol* 2002; 17: 754-61.
3. LEHNHARDT FG, SCHEID C, HOLTIK U *et al.*: Autologous blood stem cell transplantation in refractory systemic lupus erythematoses with recurrent longitudinal myelitis and cerebral infarction. *Lupus* 2006; 15: 240-3.
4. LEE RW, D'CRUZ DP: Novel therapies for anti-neutrophil cytoplasmic antibody-associated vasculitis. *Drugs* 2008; 68: 747-70.

5. KÖTTER I, DAIKELER T, AMBERGER C, TYNDALL A, KANZ L: Autologous stem cell transplantation of treatment-resistant systemic vasculitis—a single center experience and review of the literature. *Clin Nephrol* 2005; 64: 485-9.
6. DAIKELER T, KÖTTER I, BOCELLI TYNDALL C *et al.*; EBMT Autoimmune Diseases Working Party. Haematopoietic stem cell transplantation for vasculitis including Behçet's disease and polycondritis: a retrospective analysis of patients recorded in the European Bone Marrow Transplantation and European League Against Rheumatism databases and a review of the literature. *Ann Rheum Dis* 2007; 66: 202-7.
7. BORNHÄUSER M, ARINGER M, THIEDE C: Mixed lymphohematopoietic chimerism and response in Wegener's granulomatosis. *N Engl J Med* 2010; 362: 2431-2.
8. Schilder AM: Wegener's Granulomatosis vasculitis and granuloma. *Autoimmun Rev* 2010; 9: 483-7.
9. MUKHTYAR C, GUILLEVIN L, CID MC *et al.*; European Vasculitis Study Group. EULAR recommendations for the management of primary small and medium vessel vasculitis. *Ann Rheum Dis* 2009; 68: 310-7.
10. MARMONT AM: Will hematopoietic stem cell transplantation cure human autoimmune diseases? *J Autoimmun* 2008; 30: 145-50.