

Treatment of mixed cryoglobulinemia: a rheumatology perspective

S. De Vita

Rheumatology Clinic, Department of Medical and Biological Sciences, Azienda Ospedaliero-Universitaria "S. Maria della Misericordia", University of Udine, Udine, Italy.

Please address correspondence to:

Salvatore De Vita, MD,

Clinica di Reumatologia,

Azienda Ospedaliero Universitaria

"S. Maria della Misericordia"

University of Udine,

Piazzale S. Maria della Misericordia 1,

33100 Udine, Italy.

E-mail:

devita.salvatore@aoud.sanita.fvg.it

Received on March 16, 2011; accepted in

revised form on March 18, 2011.

Clin Exp Rheumatol 2011; 29 (Suppl. 64):
S99-S103.

© Copyright CLINICAL AND

EXPERIMENTAL RHEUMATOLOGY 2011.

Key words: mixed cryoglobulinemia,
treatment

ABSTRACT

The treatment of the cryoglobulinemic syndrome or vasculitis (CV) must be targeted to the individual patient, and requires clinical expertise and knowledge of the disease biology. In general, the treatment is suggested by the clinical picture, but biologic issues should also be considered.

Both immunosuppressive and antiviral approaches deserve equal attention based on the wide clinical spectrum and on disease biology, where the viral trigger and the downstream autoimmune response may play a different role in different disease stages. The severity of the disease, previous history and therapies administered, comorbidities and other individual factors should be analysed in the single case. Acute and life-threatening conditions usually require high dose steroids, plasmapheresis and/or cyclophosphamide. Rituximab often represents the best option for severe CV. Antiviral therapy is a cornerstone for the management of CV in hepatitis-related cases, and has the strongest biologic rationale, in general, in this disease and should be always considered in stabilised patients.

A multispecialistic approach is needed to better define treatment strategies in different subsets of patients.

Mixed cryoglobulinemia, or cryoglobulinemic syndrome or vasculitis (CV), is a systemic vasculitis prevalently mediated by immune complexes, associated with the hepatitis C virus (HCV) infection and non-neoplastic B-cell lymphoproliferation (1-4).

The treatment of CV remains a challenge, and requires the optimal integration, in the individual case, of clinical expertise with the knowledge of disease biology, based on the close relationship between chronic infection, autoimmunity, and lymphoproliferation in this disease (5, 6).

Treatment should be tailored to the single patient, taking into account the severity of the disease. Concomitantly, the previous history and therapies administered, including previous treatments for CV and for hepatitis C virus (HCV) infection, as well as comorbidities, should be considered. For life-threatening and severe disease manifestations, the rapidity of a given treatment to be effective is of primary importance. Low-dose aspirin should be considered, whenever possible, to reduce the cardiovascular risk.

Secondly, in CV there is evidence of an antigen-driven proliferation of rheumatoid factor-positive B cell clones leading to cryoglobulin production. Since rheumatoid factor-positive B-cells may be stimulated by immune complexes containing quite different antigens (7), HCV infection might be crucial for the induction of CV, while not for its persistence. Thus, treatment options for HCV-associated CV should attack both the viral trigger, when detected, and the autoimmune downstream events (6). This distinction is clinically relevant, and supported by experiments in the animal (8).

Overall, biologic issues must be considered to optimise the treatment suggested by the clinical picture.

Clinical issues have the absolute priority for treatment decisions in life-threatening and severe manifestations of CV. By contrast, the distinction of treatment approaches focusing on either the infectious trigger or on downstream immune activation has a primary role for the long term management of the disease, when stabilised.

Thirdly, the background of the physician proves also relevant in determining the final treatment decision. Thus, a better integration of specialists, in clinical practice and in consensus statements, is needed to improve the treatment of CV. The rheumatologist is usually more

Competing interests: none declared.

dedicated to severe cases of CV, and has a larger experience with immunosuppressive treatments, supported by the experience in treating similar manifestations in other autoimmune diseases. Hepatologists, gastroenterologists and infectivologists, in general, may have larger experience with antiviral therapy and with less severe CV cases. The experience of internal medicine and haematology specialists may be more variable and based on their personal interest. Interestingly, in a recent survey, infectious disease specialists, gastroenterologists and hepatologists resulted more prone to use antiviral therapy than rheumatologists (9).

With regard to these issues, a big effort was made in 2009 by the Italian Group for the Study of Cryoglobulinemia, named GISC, which promoted a consensus conference to discuss the currently used therapies for CV and the published evidence concerning their efficacy, joining physicians from different medical specialities (9). This is a strong point in favour of these recently proposed recommendations, since the bias of single-centre, single-speciality-oriented opinion is prevented. The aim of the conference was to define a core set of practical treatment recommendations by combining clinical trial data and expert opinion. Analysed treatments were divided into three groups: a) antiviral (interferon-based) therapies; b) biological (anti-B cell) therapies; and c) other therapeutic approaches including corticosteroids, apheresis, cyclophosphamide, colchicine, low-antigen-content diet, and analgesic and non-steroidal anti-inflammatory drugs.

The present paper will focus on rituximab (RTX) and antiviral therapy based on the perspective of a rheumatologist after previous consensus discussion (9), and starting from the clinical setting and not from drug classes. For the other treatments currently used in HCV-related CV, recent consensus statements are recommended (9). Regarding HCV-unrelated CV, fewer data are available and these will not be discussed.

Acute and life-threatening conditions

Early diagnosis and prompt treatment of CV acute and life-threatening mani-

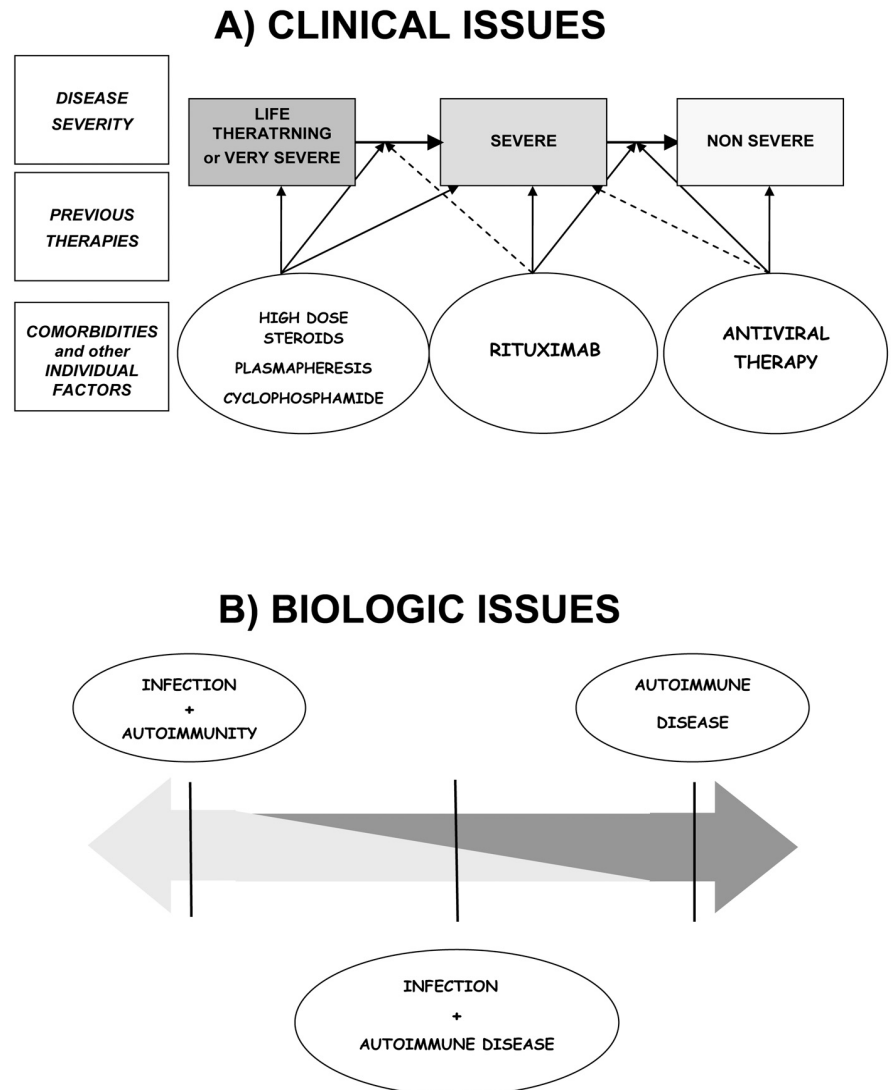


Fig. 1. Both clinical and biologic issues should be considered to decide the treatment of mixed cryoglobulinemia. Treatment should be tailored to the single patient taking into account disease severity, previous therapies, comorbidities and other relevant individual factors (panel A). Biologic issues are also relevant (panel B), since infection and the downstream autoimmune response may play a different role in different disease stages. There may be a rationale for using antiviral monotherapy, monotherapy directed to the autoimmune and lymphoproliferative response, or the combination of the two, and each option may be more useful in the single case.

festations, such as abdominal vasculitis, haemorrhagic alveolitis, and complicated hyperviscosity syndrome, is mandatory.

If a very early diagnosis is lacking, even in few hours and based only on clinical suspicion in selected cases, early treatment is impossible and further complications may occur, rendering subsequent therapy much more difficult. The risk of systemic organ failure and superimposed infection should be considered. High dose corticosteroids and plasmapheresis represent the most rapid approaches currently available (Fig. 1).

By contrast, antiviral therapy should not be considered a priority in acute and very severe cases of CV. Cyclophosphamide may be used after plasmapheresis (9). Cyclophosphamide associated with high dose steroids may also be an option (Fig. 1), but it is not adequately supported by the literature (9). Recently, RTX was used successfully in patients with CV and severe gastrointestinal vasculitis refractory to plasmapheresis and cyclophosphamide (10).

A major problem is represented by the heavy drug-induced immunosuppression, which may also antedate, and the

clinical setting. The risk of infections during the treatment of very severe CV is high. Prophylaxis, early recognition and prolonged treatment of these infectious complications are underscored since the patient remains immune suppressed for a long time. Thus, waiting for the effects of treatment, and also subsequently, when the patient is improving or the disease is more stable, surveillance for infections is as relevant as the monitoring of the immunosuppressive treatment chosen.

Acute motor neuropathy and rapidly progressive glomerulonephritis in CV may deserve an aggressive approach, as described above. However, according to the clinical setting and rapidity of progression, induction may be very short, and less aggressive therapies, as reported below, may be planned early.

Severe manifestations

The more common severe manifestations of CV include active glomerulonephritis, skin ulcers and peripheral neuropathy (motor, or sensory refractory to symptomatic therapy, or evolving) (11-13). In addition, CV is also severe in patients recovering from acute and life-threatening CV manifestations effectively managed, where additional, though less intense treatment may be advisable to stabilise the disease and to avoid the risk of hazardous relapses. Rituximab often represents the best current option for severe CV (Fig. 1). Other approaches targeting the immune activation downstream to viral infection such as steroids, plasmapheresis, and cytotoxic drugs may also prove effective, but rituximab appears superior based on recent open experience in different centres (9) and on the results of a recent controlled study (13).

RTX is a monoclonal antibody against the CD20 antigen, which is selectively expressed on B cells. CD20-positive cells are expanded and activated in CV, may harbour and present viral antigens, and play a crucial pathogenetic role in cryoglobulin production. The rationale underlying RTX treatment is to intervene downstream of the infectious trigger more selectively than with conventional immune suppression. RTX has led to very encouraging

results in open studies and single case reports (9). Glomerulonephritis and skin ulcers usually respond within the first 1-3 months, but complete healing of skin ulcers requires a longer time. Both sensitive and motor neuropathy improve within 1-5 months, with stable electromyography. A recent multicentre RCT involving 59 CV patients who had failed or were not eligible for antiviral therapy, compared RTX monotherapy (at the dose recommended in rheumatoid arthritis, *i.e.* 1 gram every two weeks for a total of two infusions, with or without low-dose steroids) with the best conventional immunosuppressive treatment (corticosteroids, cyclophosphamide, azathioprine or plasma exchange, as chosen by the clinician) (13). The preliminary results of the trial supported the superiority of RTX both in the short and long term (24 months). Importantly, RTX allowed steroid sparing, and the study regimen with low-dose or no steroids associated with RTX *ab initio* proved effective (13). The efficacy and safety of RTX in CV has also been recently highlighted by another multicentre series (14). The activity of RTX is supported by the restoration of some CV-related immune abnormalities (15), and the disappearance of bone marrow B cell clonal expansion (16).

The duration of the response to a single cycle of RTX may frequently last more than one year, but earlier relapses also occur. Retreatment with RTX after relapse has proved to be effective in most cases (9, 13), while maintenance schedules appear advisable, at present, only when a relapse would be very hazardous (10). However, the issue of maintenance treatment with RTX remains open and surely deserves additional investigation.

Short-term reactions to RTX infusions do not seem to be more frequent in CV than in rheumatoid arthritis, systemic lupus erythematosus or Sjögren's syndrome (9). Severe infectious complications are not increased in CV after RTX, but, as in the case of other biologics, these appear more frequent in patients heavily immunosuppressed by previous treatments, taking corticosteroids, or with hypogammaglobulinemia.

Up to now, RTX has not worsened liver function, even after retreatment during a follow-up of two years (9, 13), and has been recently given to CV patients with liver cirrhosis with improvement in both CV symptoms and in liver function (17).

By contrast, RTX may induce the severe reactivation of hepatitis B virus infection and should then be used in HbsAg-positive and in potential occult HBV carriers (HbsAg-negative/anti-HBc-positive) only when strictly needed, and in combination with antiviral therapy (9).

Serum sickness has rarely been reported in CV after RTX (about 1% in pooling data) (9). A French group, on the other hand, reported a higher incidence of serum sickness (18). Therefore, patients should be carefully monitored, and pre-medicated with 100mg of methylprednisolone, anti-histamine drugs and paracetamol may reduce the risk. We and others have never performed plasmapheresis before rituximab to reduce the risk of serum sickness, although this approach has been proposed (18). In patients with a history of heart failure or arrhythmia, the administration of half a dose per day on two consecutive days, and/or prolonging the duration of each infusion, may be considered.

Antiviral therapy is a cornerstone for the management of CV in HCV-related cases, and has the strongest biologic rationale, in general, in this disease.

However, with regard to the issue of a possible etiologic therapy for severe CV, the lower rapidity of the antiviral approach does not support its priority. Thus, antiviral monotherapy should not be considered as a first step approach, in general, for severe cases (Fig. 1). The possible persistence or onset of CV features in patients despite serum HCV RNA negativisation, although not frequent, should also be remembered (19). This suggests that the autoimmune process can become independent of viral triggering or may play a dominant pathogenetic role at some disease stages.

In sequential schedules, RTX should then be given before antiviral therapy in severe CV (Fig. 1).

Whether antiviral therapy may be of value given *ab initio* in severe CV as a combination, *i.e.* directly in conjunction with immunosuppressive therapy, and more effectively than immunosuppressive therapy alone, remains to be demonstrated. The combination might show some synergistic effects, but might as well prove inadvisable for safety and treatment decision issues.

The combination of antivirals and rituximab has been recently employed by French and Italian authors (20, 21), showing a superiority to antiviral therapy alone, as expected. In the French study (20) the combination therapy reduced the time to clinical remission, improved renal response rates (but not those of other organic manifestations), and led to higher rates of cryoglobulin clearance and clonal VH1-69+ B cell suppression than the monotherapy with PegIFN plus ribavirin. In the Italian study (21), a higher rate of complete response was achieved with the combination (12/22 cases: 54.5%) than with antiviral monotherapy (*vs.* 5/15 cases, 33.3%; $p < 0.05$).

However, no study has been designed, up to now, to define whether and when the combination of antivirals plus rituximab, given *ab initio*, is superior to rituximab monotherapy in terms of both efficacy and safety. Furthermore, starting directly with the combination regimen does not allow distinguishing between the efficacy and safety of the single regimen, while this is crucial for subsequent, long-term treatment choices. A sequential rather than a combined approach as a first step, with RTX monotherapy having the priority, appears then rationale. Antiviral therapy can be added to rituximab or may substitute rituximab, as a second step. The combination of rituximab plus antiviral therapy deserves attention in future studies, and may eventually prove the treatment of choice in cases to be defined (Fig. 1).

The issue of the management of severe patients who have already undergone immunosuppressive or antiviral therapy is finally underscored. The clinical history should guide the decisions, and great care should be devoted to the exact regimens already employed, and to the true causes of suspension.

Non-severe manifestations

Many patients present non-severe CV manifestations, such as constitutional features, purpura or arthritis. Other patients may show very mild renal and neurologic features. A high variability in the whole clinical picture may be observed, leading to very different treatment decisions. These also depend on either the chronicity or the frequency of relapsing manifestations, on the age and social activity of the patient, the concomitant liver disease, and comorbidities. Cases recovered from severe CV treated with rituximab or immunosuppressors, where a different treatment plan is needed for the long term, after an adequate period of disease stabilisation, may be also considered as non-severe.

The indication to antiviral therapy is crucial in this subset (Fig. 1). However, while antiviral therapy could be more obvious for younger patients and for those with active hepatitis, it may have no place at all in other patients where it is contraindicated, where the best antiviral regimen already failed or was not tolerated in the past, and in elderly patients with very mild or inconstant CV manifestations easily managed with symptomatic treatment. These situations represent the extremes of a spectrum of clinical pictures where treatment should be individualised.

In the recent consensus conference (9), it was widely agreed among experts that an attempt to eradicate HCV should be made whenever possible in CV, because suppressing viral replication may limit or arrest the immunopathogenic process. Pegylated IFN α -2a and α -2b combined with ribavirin is now the standard of care for HCV treatment. It leads to 41–54% sustained viral responses in the case of HCV genotype 1, and approximately 80% in the case of genotypes 2 and 3. The presence of CV does not seem to substantially affect the rate of sustained viral response observed in the general population of HCV-infected subjects (22).

An extended duration of treatment (up to 48 weeks for HCV genotypes 2 or 3 and 72 weeks for HCV genotypes 1 or 4) may be considered for virologi-

cal non-responders who show a clinical and laboratory improvement (9).

Major contraindications to antiviral treatment should be excluded and a careful monitoring is recommended due to the possible onset of side effects and possible worsening or onset of some vasculitic manifestations.

Lymphoma associated with cryoglobulinemic vasculitis

Again, treatment should be individualised. Aggressive B-cell lymphoma usually deserves the same treatment given by the haematologist for that histotype and stage in CV-unrelated cases. The concomitant systemic features of vasculitis and HCV infection, if present, should be considered in any case. Regimens consisting of rituximab associated with cytotoxic drugs may be more indicated. On the other hand, most cases of lymphoma in CV are indolent B-cell lymphomas involving the bone marrow and possibly the spleen, associated with HCV-related chronic hepatitis and intra-hepatic B-cell clonal expansion. Antiviral therapy likely represents the best option in these HCV-related indolent lymphomas, but priority should be given to very severe or severe systemic features, if present. Despite the clinical and histopathologic beneficial effects, however, a molecular regression of indolent B-cell lymphoma has not been observed after serum viral clearance (6). In any case, such a molecular regression may not represent the primary end point of treatment in the individual case.

Conclusions

Treatment of CV requires clinical expertise, knowledge of disease biology, and the acceptance of a multispecialistic approach with an open mind to novelties. The expertise coming from different medical backgrounds should finally help to define the best treatment strategy in very different subsets of patients. RTX therapy for instance, maybe the greatest advance for the treatment of CV in the last few years, was registered for lymphoma and then initially employed by haematologists and then by rheumatologists (23, 24).

Both immunosuppressive and anti-

ral approaches deserve equal attention based on the wide clinical spectrum and on disease biology, where the viral trigger and the downstream autoimmune response may play a different role in different disease stages.

The integration of less toxic immunosuppressive approaches with antiviral strategies should further improve the treatment of CV, and new antiviral drugs might further modify current treatment protocols in the near future.

References

- MELTZER M, FRANKLIN EC: Cryoglobulinemia—a study of twenty-nine patients. I. IgG and IgM cryoglobulins and factors affecting cryoprecipitability. *Am J Med* 1966; 40: 828-36.
- FERRI C, GRECO F, LONGOMBARDO G *et al.*: Association between hepatitis C virus and mixed cryoglobulinemia. *Clin Exp Rheumatol* 1991; 19: 621-4.
- DE VITA S, DE RE V, GASPAROTTO D *et al.*: Oligoclonal non-neoplastic B cell expansion is the key feature of type II mixed cryoglobulinemia. *Arthritis Rheum* 2000; 43: 94-102.
- DE VITA S, SOLDANO F, ISOLA M *et al.*: Preliminary classification criteria for the cryoglobulinemic vasculitis. *Ann Rheum Dis* 2011 (in press).
- DELLA ROSSA A, BALDINI C, TAVONIA, BOMBARDIERI S: How HCV has changed the approach to mixed cryoglobulinemia. *Clin Exp Rheumatol*; 27 (Suppl. 52): S115-23.
- DE VITA S, QUARTUCCIO L, FABRIS M: Hepatitis C virus infection, mixed cryoglobulinemia and BlyS upregulation: targeting the infectious trigger, the autoimmune process, or both? *Autoimmun Rev* 2008; 8: 95-9.
- CARSON D, CHEN PP, KIPPS TJ: New roles for rheumatoid factor. *J Clin Invest* 1991; 87: 379-83.
- DE RE V, SANSONNO D, SIMULA MP *et al.*: HCV-NS3 and IgG-Fc crossreactive IgM in patients with type II mixed cryoglobulinemia and B-cell clonal proliferations. *Leukemia* 2006; 20: 1145-54.
- PIETROGRANDE M, DE VITA S, ZIGNEGO A *et al.*: Recommendations for the management of mixed cryoglobulinemia syndrome in hepatitis C virus-infected patients. *Autoimmun Rev* 2011. Epub Feb 14.
- QUARTUCCIO L, PETRARCA A, MANSUTTI E *et al.*: Efficacy of rituximab in severe and mild abdominal vasculitis in the course of mixed cryoglobulinemia. *Clin Exp Rheumatol* 2010; 28 (Suppl. 57): 84-7.
- TARANTINO A, CAMPISE M, BANFI G *et al.*: Long-term predictors of survival in essential mixed cryoglobulinemic glomerulonephritis. *Kidney Int* 1995; 47: 618-23.
- FERRI C, SEBASTIAN M, GIUGGIOLI D *et al.*: Mixed cryoglobulinemia: demographic, clinical, and serologic features and survival in 231 patients. *Semin Arthritis Rheum* 2004; 33: 355-74.
- DE VITA S, QUARTUCCIO L, MASOLINI P *et al.*: A randomized, controlled, multicenter phase III study of the efficacy and safety of rituximab monotherapy versus the best available treatment in patients with mixed cryoglobulinemia syndrome. *Ann Rheum Dis* 2010; 69 (Suppl. 3): 93.
- FERRI C, SEBASTIANI M, CACOUB P *et al.*: Effects of rituximab in a large series of patients with HCV-associated mixed cryoglobulinemia syndrome. *Ann Rheum Dis* 2010; 69 (Suppl. 3): 234.
- SAADOUN D, ROSENZWAJG M, LANDAU D, PIETTE JC, KLATZMANN D, CACOUB P: Restoration of peripheral immune homeostasis after rituximab in mixed cryoglobulinemia vasculitis. *Blood* 2008; 111: 5334-41.
- QUARTUCCIO L, SALVIN S, FABRIS M, SACCO S, DE VITA S: Disappearance of bone marrow B cell clonal expansion in patients with type II hepatitis C virus-related cryoglobulinemic glomerulonephritis after clinical efficient rituximab therapy. *Ann Rheum Dis* 2008; 67: 1494-5.
- PETRARCA A, RIGACCI L, CAINI P *et al.*: safety and efficacy of rituximab in patients with hepatitis C virus-related mixed cryoglobulinemia and severe liver disease. *Blood* 2010; 116: 335-42.
- SENE D, GHILLANI-DALBIN P, AMOURA Z, MUSSET L, CACOUB P: Rituximab may form a complex with IgMk mixed cryoglobulin and induce severe systemic reactions in patients with hepatitis C virus-induced vasculitis. *Arthritis Rheum* 2009; 60: 3848-55.
- QUARTUCCIO L, DE MARCHI G, FABRIS M, DE VITA S: Development of type II mixed cryoglobulinaemic syndrome after effective and persistent hepatitis C virus eradication. *Rheumatology (Oxford)* 2006; 4: 367-8.
- SAADOUN D, RESCHE RIGON M *et al.*: Rituximab plus Peg-interferon-alpha/ribavirin compared with Peg-interferon-alpha/ribavirin in hepatitis C-related mixed cryoglobulinemia. *Blood* 2010; 116: 326-34.
- DAMMACCO F, TUCCI FA, LAULETTA G *et al.*: Pegylated interferon-alpha, ribavirin, and rituximab combined therapy of hepatitis C virus-related mixed cryoglobulinemia: a long-term study. *Blood* 2010; 116: 343-53.
- GHANY MG, STRADER DB, THOMAS DL, SEEFF LB: Diagnosis, management, and treatment of hepatitis C: an update. *American Association for the Study of Liver Diseases. Hepatology* 2009; 49: 1335-74.
- ZAJA F, RUSSO D, FUGA G, PATRIARCA F, ERMACORA A, BACCARANI M: Rituximab for the treatment of type II mixed cryoglobulinemia. *Haematologica* 1999; 84: 1157-8.
- ZAJA F, DE VITA S, MAZZARO C *et al.*: Efficacy and safety of rituximab in type II mixed cryoglobulinemia. *Blood* 2003; 101: 3827-34.