

Ultrasound imaging for the rheumatologist

XXXIV. Sonographic assessment of the painful foot

G. Meenagh¹, G. Sakellariou², A. Iagnocco³, A. Delle Sedie⁴, L. Riente⁴, E. Filippucci⁵,
W. Grassi⁵, S. Bombardieri⁴, G. Valesini³, C. Montecucco²

¹Department of Rheumatology, Antrim Hospital, Antrim, United Kingdom;

²Cattedra di Reumatologia, IRCCS Policlinico San Matteo, Università di Pavia, Pavia, Italy;

³Cattedra di Reumatologia, Sapienza Università di Roma, Roma, Italy;

⁴Unità Operativa di Reumatologia, Università di Pisa, Pisa, Italy;

⁵Cattedra di Reumatologia, Università Politecnica delle Marche, Ancona, Italy.

Gary Meenagh, MD

Garifallia Sakellariou, MD

Annamaria Iagnocco, MD

Andrea Delle Sedie, MD

Lucrezia Riente, MD

Emilio Filippucci, MD

Walter Grassi, MD, Professor of Rheumatology;

Stefano Bombardieri, MD, Professor of Rheumatology

Guido Valesini, MD, Professor of Rheumatology

Carlomaurizio Montecucco, MD, Professor of Rheumatology

Please address correspondence and reprint requests to:

Dr Gary Meenagh,

Department of Rheumatology, Antrim Hospital,

Antrim, United Kingdom.

E-mail: garymeenagh@yahoo.co.uk

Received and accepted on July 20, 2011.

Clin Exp Rheumatol 2011; 29: 601-603.

© Copyright CLINICAL AND

EXPERIMENTAL RHEUMATOLOGY 2011.

Key words: foot, ultrasound, arthritis, synovitis, pain

Competing interests: none declared.

ABSTRACT

The foot is increasingly the focus of attention for rheumatologists when assessing patients presenting to a clinic and may represent underlying intra-articular inflammatory pathology or involvement of the surrounding soft tissues.

This study describes the correlation between clinical and ultrasound (US) findings in patients presenting with a variety of rheumatic disorders linked with foot pain.

Poor correlation was found between conventional clinical examination and US in cases with joint inflammation, tendonitis and, more particularly, those cases with enthesopathy.

Introduction

The foot is increasingly the focus of attention for rheumatologists when assessing patients presenting to a clinic and may represent underlying intra-articular inflammatory pathology or involvement of the surrounding soft tissues (1-12). It is now recognised that a rheumatologist may under-estimate the extent of the findings solely by performing a clinical assessment (13, 14). This is particularly likely to be the case in the distal lower limb owing to the complexity of the anatomy within the foot. Ultrasound (US) examination is now well incorporated into standard clinical assessment by rheumatologists and therefore likely to lend greater accuracy to blind clinical examination (1, 2, 15, 16).

The present study was aimed at investigating the value of US in the assessment of rheumatic patients presenting to clinic with foot pain.

Methods

The study was conducted according to the Declaration of Helsinki and local

regulations, and informed consent was obtained from all patients.

Patients

Sixty-four patients with foot pain, attending the out-patient and the in-patient clinics of the Rheumatology Departments involved in this multicentre study were consecutively recruited in the study. Basic patient demographic and clinical data of the study population are reported in Table I.

Study design

All patients underwent a complete clinical assessment by an expert rheumatologist who recorded the presence/absence of pain/tenderness (by palpation and/or active or passive mobilisation of the foot) and foot swelling at joint level. Due to the difficulties in distinguishing between individual joints of the mid-foot, the region was analysed as if it were a single joint. Prior to the beginning of the study, sonographers reached a consensus on both the scanning technique to adopt and the pathological findings to detect. One sonographer for each centre performed the US examinations, blinded to patients clinical and laboratory data.

US scanning technique

US examinations were carried out using a Logiq 9 (General Electrics Medical Systems, Milwaukee, WI) with a linear probe operating at 10 MHz for joints assessment and 14 MHz for tendons and entheses evaluation, and a My Lab70 XVG (Esaote SpA, Genoa, Italy) equipped with a multi-frequency linear probe (4-13 MHz).

All US examinations of the foot were performed using a multi-planar technique and the foot in a neutral position following the indications provided by

the EULAR guidelines for musculoskeletal ultrasound in rheumatology (17). Sonographic measurements of enthesal thickness were performed where it appeared maximal as in previous studies by the group (9-12).

US image interpretation

Sonographic findings indicative of foot pathology were documented and reported. For the detection of joint effusion, synovial hypertrophy, tenosynovitis, enthesopathy and bone erosion the US definitions described by the OMERACT special interest group (18) were adopted. Enthesitis was defined as hypoechoogenicity and/or thickening of the entheses, as well as the presence of power Doppler signal at the enthesal level as in our previous studies (10); plantar fascia proximal insertion has been considered as an enthesis. Because of the study design (not assessing the presence of hallux valgus, frequently associated to erosions of the medial part of the first metatarsal head), we decided to consider as a real erosion of the first metatarsophalangeal (MTP) joint only those situated on the dorsal aspect. Cartilage evaluation was performed to assess the presence of hyperechoic enhancement of the chondro-synovial margin indicative of monosodium urate (MSU) deposits (19). The presence of osteophytes was defined by the detection of characteristic irregularities of the bone profile as described in previous studies concentrating on osteoarthritis (20).

Results

A total of 64 patients with unilateral foot pain were examined clinically and sonographically (6 patients had bilateral foot pain and in this instance only the more painful foot was investigated according to a patient visual analogue scale for pain).

Table II shows the relationship between clinical and US findings indicative of foot joint pathology.

The most common clinical finding was that of joint effusion in 33% of cases. Subsequent US assessment however showed that 60% of cases demonstrated an effusion. US examination of the volar aspect of the MTP joints did not

Table I. Patient demographic and clinical data.

Number of patients	64
Gender (female/male)	40/24
Age in years (range)	54.6 (23–81)
Underlying diagnosis	27 OA; 9 RA; 8 PsA; 7 gout; 5 undifferentiated arthritis; 2 SpA; 6 undefined diagnosis.

OA: osteoarthritis; RA: rheumatoid arthritis; PsA: psoriatic arthritis; SpA: seronegative spondyloarthropathies.

Table II. Correlation between clinical examination and ultrasound findings.

Disease finding	Clinical examination	Ultrasound examination
Joint effusion	33%	60%
Enthesopathy	19%	39%
Tenosynovitis	15%	21%

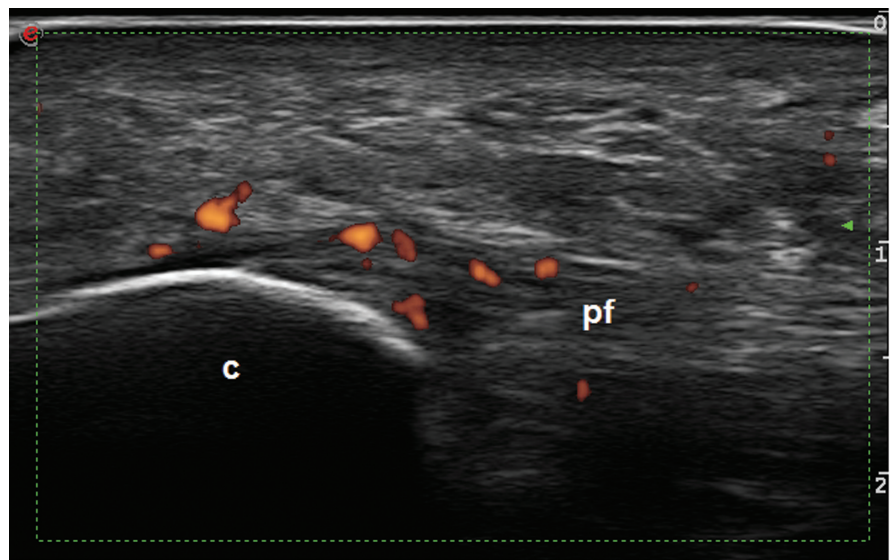


Fig. 1. Seronegative spondyloarthropathy. Plantar fasciitis. Longitudinal view showing power Doppler signal within the plantar fascia at its insertion into the calcaneus. c: calcaneus; pf: plantar fascia.

lend additional clinical information to the diagnosis. The most common joints to show inflammatory activity were 1st–3rd MTP joints (91% cases). Synovial hypertrophy and intra-articular power Doppler signal were seen in 36% and 29% of the examined joints. Bone erosions were identified in 16 cases predominantly within the fore-foot joints.

Clinical suspicion of enthesopathy was recorded in 19% of cases whilst there was sonographic evidence of enthesopathy in 39%. All cases reported related to the plantar fascial insertion (Fig. 1). Tendon pathology was seen in 21% of cases but suspected clinically in only 15%. US evidence of marginal osteo-

phyte was seen in 75% of feet in patients with osteoarthritis.

In patients with gout chondro-synovial enhancement was seen in 65% and bony erosion identified in 39%.

Discussion

The painful foot is a common complaint made by patients with a spectrum of rheumatic disorders and often presents the rheumatologist with a diagnostic dilemma due to the complexity of foot anatomy together with pain often presenting in a diffuse manner. Plain x-rays and blood investigations often add little to the diagnostic conundrum.

To date, the role of US in the assessment of patients with foot pain has yet

to be fully defined and validated internationally. Several investigators, including our own group, have described the expected US findings in different rheumatic conditions involving the foot (4-12).

This observational multicentre study has clearly demonstrated that in a random cohort of patients presenting to clinic with 'foot pain' US was a more sensitive indicator of inflammation within the joints of the foot than clinical assessment. This has been documented elsewhere at other anatomical sites by our group (10, 11). The commonest sites for inflammatory activity and the detection of erosion was the forefoot, particularly the first 3 MTP joints. As has previously been reported, there was poor correlation between the clinical impression of enthesopathy and tendinopathy when compared to US confirmation.

The important take-home messages from US assessment of foot pain are:

- Perform an exhaustive search of both intra-articular and extra-articular structures when scanning the foot;
- Particular attention should be paid to the enthesis and to tendon structures as clinical examination appears to be a poor indicator of likely pathology at this level.

It is inevitable that further observational and interventional studies will be required to enable US examination to become a conventional approach adopted by all rheumatologists when assessing patients with foot pain.

References

1. McNALLY EG: Ultrasound of the small joints of the hands and feet: current status. *Skeletal Radiol* 2008; 37: 99-113.
2. SZKUDLAREK M, NARVESTAD E, KLARLUND M, COURT-PAYEN M, THOMSEN HS, ØSTERGAARD M: Ultrasonography of the metatarsophalangeal joints in rheumatoid arthritis. *Arthritis Rheum* 2004; 50: 2103-12.
3. KOSKI JM: Ultrasonography of the subtalar and midtarsal joints. *J Rheumatol* 1993; 20: 1753-5.
4. WAKEFIELD RJ, FREESTON JE, O'CONNOR P *et al.*: The optimal assessment of the rheumatoid arthritis hindfoot: a comparative study of clinical examination, ultrasound and high field MRI. *Ann Rheum Dis* 2008; 67: 1678-82.
5. RIENTE L, DELLE SEDIE A, IAGNOCCO A *et al.*: Ultrasound imaging for the rheumatologist V. Ultrasonography of the ankle and foot. *Clin Exp Rheumatol* 2006; 24: 493-8.
6. BOWEN CJ, CULLIFORD D, DEWBURY K *et al.*: The clinical importance of ultrasound detectable forefoot bursae in rheumatoid arthritis. *Rheumatology* 2010; 49: 191-2.
7. BOWEN CJ, EDWARDS CJ, HOOPER L *et al.*: Improvement in symptoms and signs in the forefoot of patients with rheumatoid arthritis treated with anti-TNF therapy. *J Foot Ankle Res* 2010; 3: 10.
8. SHEANE BJ, BEDDY P, O'CONNOR M, MILLER S, CUNNANE G: Targeted ultrasound of the fifth metatarsophalanheal joint in an early inflammatory arthritis cohort. *Arthritis Rheum* 2009; 61: 1004-8.
9. SCIRÈ CA, IAGNOCCO A, MEENAGH G *et al.*: Ultrasound imaging for the rheumatologist XXXIII. Sonographic assessment of the foot in early arthritis patients. *Clin Exp Rheumatol* 2011; 29: 465-9.
10. DELLE SEDIE A, RIENTE L, FILIPPUCCI E *et al.*: Ultrasound imaging for the rheumatologist XXXII. Sonographic assessment of the foot in patients with psoriatic arthritis. *Clin Exp Rheumatol* 2011; 29: 217-22.
11. RIENTE L, DELLE SEDIE A, SCIRÈ CA *et al.*: Ultrasound imaging for the rheumatologist XXXI. Sonographic assessment of the foot in patients with rheumatoid arthritis. *Clin Exp Rheumatol* 2011; 29: 1-5.
12. IAGNOCCO A, RIENTE L, DELLE SEDIE A *et al.*: Ultrasound imaging for the rheumatologist XXII. Achilles tendon involvement in spondyloarthritis. A multi-centre study using high frequency volumetric probe.
13. SALAFFI F, FILIPPUCCI E, CAROTTI M *et al.*: Inter-observer agreement of standard joint counts in early rheumatoid arthritis: a comparison with grey scale ultrasonography—a preliminary study. *Rheumatology* 2008; 47: 54-8.
14. DOUGADOS M, JOUSSE-JOULIN S, MISTRETTA F, D'AGOSTINO MA, BACKHAUS M, BENTIN J: Evaluation of several ultrasonography scoring systems for synovitis and comparison to clinical examination: results from a prospective multicentre study of rheumatoid arthritis. *Ann Rheum Dis* 2010; 69: 828-33.
15. BACKHAUS M: Ultrasound and structural changes in inflammatory arthritis: synovitis and tenosynovitis. *Ann NY Acad Sci* 2009; 1154: 139-51.
16. BACKHAUS M, OHRNDORF S, KELLNER H *et al.*: Evaluation of a novel 7-joint ultrasound score in daily rheumatologic practice: a pilot project. *Arthritis Rheum* 2009; 61: 1194-201.
17. BACKHAUS M, BURMESTER GR, GERBER T, GRASSI W, MACHOLD KP, SWEN WA: Working Group for Musculoskeletal Ultrasound in the EULAR Standing Committee on International Clinical Studies including Therapeutic Trials. Guidelines for musculoskeletal ultrasound in rheumatology. *Ann Rheum Dis* 2001; 60: 641-9.
18. WAKEFIELD RJ, BALINT PV, SZKUDLAREK M, FILIPPUCCI E, BACKHAUS M, D'AGOSTINO MA; OMERACT 7 SPECIAL INTEREST GROUP: Musculoskeletal ultrasound including definitions for ultrasonographic pathology. *J Rheumatol* 2005; 32: 2485-7.
19. FILIPPUCCI E, RIVEROS MG, GEORGESCU D, SALAFFI F, GRASSI W: Hyaline cartilage involvement in patients with gout and calcium pyrophosphate deposition disease. An ultrasound study. *Osteoarthritis Cartilage* 2009; 17: 178-81.
20. NAREDO E, CABERO F, PALOP MJ, COLLADO P, CRUZ A, CRESPO M: Ultrasonographic findings in knee osteoarthritis: a comparative study with clinical and radiographic assessment. *Osteoarthritis Cartilage* 2005; 13: 568-74.