

Ultrasound imaging for the rheumatologist XL. Sonographic assessment of the hip in rheumatoid arthritis patients

L. Di Geso¹, E. Filippucci¹, L. Riente², G. Sakellariou³, A. Delle Sedie², G. Meenagh⁴, A. Iagnocco⁵, S. Bombardieri², C. Montecucco³, G. Valesini⁵, W. Grassi¹

¹Rheumatology Clinic, Università Politecnica delle Marche, Ancona, Italy;

²Rheumatology Unit, Università di Pisa, Pisa, Italy;

³Rheumatology, IRCCS Policlinico San Matteo, Università di Pavia, Pavia, Italy;

⁴Department of Rheumatology, Antrim Hospital, Antrim, United Kingdom;

⁵Dipartimento di Medicina Interna e Specialità Mediche, Sapienza Università di Roma, Roma, Italy.

Luca Di Geso, MD

Emilio Filippucci, MD

Lucrezia Riente, MD

Garifallia Sakellariou, MD

Andrea Delle Sedie, MD

Gary Meenagh, MD

Annamaria Iagnocco, MD

Stefano Bombardieri, MD, Professor of Rheumatology

Carlomaurizio Montecucco, MD,

Professor of Rheumatology

Guido Valesini, MD, Professor of Rheumatology

Walter Grassi, MD, Professor of Rheumatology

Please address correspondence to:

Luca Di Geso, MD,

Clinica Reumatologica,

Università Politecnica delle Marche,

Ospedale "C. Urbani",

Via dei Colli 52,

60035 Jesi (Ancona) - Italy.

E-mail: lucadigeso@libero.it

Received and accepted on August 20, 2012.

Clin Exp Rheumatol 2012; 30: 464-468.

© Copyright CLINICAL AND

EXPERIMENTAL RHEUMATOLOGY 2012.

Key words: rheumatoid arthritis, ultrasound, hip

Competing interests: none declared.

ABSTRACT

Objectives. The aim of the present study was to correlate clinical and laboratory data with those obtained by ultrasound (US) evaluation of the hip in a cohort of patients with rheumatoid arthritis (RA).

Methods. Fifty-two RA patients attending the Rheumatology Departments involved in the present study were enrolled. Demographic (age, gender), clinical (body mass index, disease duration, treatments, history or current hip pain, tenderness by internal or external hip rotation or palpation of the greater trochanteric region), laboratory (erythrocyte sedimentation rate, C-reactive protein, rheumatoid factor and antibodies anti-citrullinated peptides) and clinimetric data (disease activity score 28 – DAS28, Health Assessment Questionnaire – HAQ, Lequesne index) were collected. All patients underwent an US examination of both hips according to international guidelines.

Results. A total of 100 hips were scanned in 52 patients with RA. Approximately half of the patients reported a history of hip pain, one fourth complained of current pain, and the physical examination (internal and/or external rotation and palpation of the greater trochanteric region) evoked pain up to 19% and 22% of the patients, respectively. US examination found signs of hip joint abnormalities in 42% of the patients; US changes indicative of hip joint inflammation and damage were detected respectively in 24% and 32% of the cases. No patient presented power Doppler signal in the hip joint. A significant correlation between US pathological findings at hip level was found with clinical data (current pain and evoked pain by internal or exter-

nal hip rotation). Furthermore, US cartilage lesion correlated with age of the patient, and US bone erosions with the disease duration. No correlation was found between the sonographic assessment and laboratory data, DAS 28, and Lequesne index.

Conclusions. US abnormalities at hip joint level obtained in the present study correlated with clinical findings, while no correlation was found with DAS28 or laboratory data. Further investigations are encouraged to clarify the US additional value at hip level in patients with RA.

Introduction

Rheumatoid arthritis (RA) is a chronic, systemic autoimmune inflammatory disease which mainly affects the diarthrodial joint and clinically manifests as joint pain, stiffness, and swelling (1).

The hip joint is frequently affected and its involvement can progressively lead to secondary osteoarthritis with a consequent joint damage requiring total joint replacement in case of aggressive disease (2-5). RA represents the third most common cause for lower limb joint replacement in North America and Northern Europe (6). In spite of the impact of hip joint inflammation on the quality of life in RA patients (7), little is known about its involvement in RA, starting from its real prevalence.

Ultrasound (US) has been shown to be a suitable and sensitive imaging technique to assess joints, revealing both signs of inflammation (joint cavity widening, caused by effusion and/or synovial hypertrophy, and pathological perfusion, detectable using power Doppler technique) and joint damage (cartilage lesions and bone abnormalities) (8-14). US may be particularly useful

in hip assessment overcoming the limits of the clinical examination.

The aim of present study was to correlate clinical and laboratory data with those obtained by US evaluation of the hip in patients with RA.

Patients and methods

Fifty-two RA patients attending the out-patient or in-patient clinics of five centres (Rheumatology Department of the Università Politecnica delle Marche, University of Pisa, University of Pavia, the Sapienza University of Rome, in Italy, and Antrim Hospital, in Northern Ireland, UK) were consecutively enrolled in this study. All patients fulfilled the 1987 American College of Rheumatology criteria or the 2010 American College of Rheumatology/European League Against Rheumatism classification criteria for rheumatoid arthritis (15, 16).

Clinical assessment

All patients underwent a complete clinical examination carried out by an expert rheumatologist and the outcome measures to evaluate the disease activity score (DAS28, disease activity score in 28 joints) and health assessment (HAQ, Health Assessment Questionnaire) were acquired (17-19).

Furthermore, for both hip joints the following data were recorded: previous or current hip pain, tenderness during external or internal rotation, and evoked by the palpation of the great trochanter region. Current therapy was recorded (use of DMARDs, biological agents, NSAIDs, and corticosteroids).

The Lequesne index, originally developed for assessing severity of hip osteoarthritis, was adopted as index to clinically evaluate hip disease (21).

C-reactive protein (CRP), erythrocyte sedimentation rate (ESR) and presence or absence of rheumatoid factor and antibodies anti-citrullinated peptides were obtained as laboratory tests.

US scanning technique and image interpretation

US hip assessment was carried out according to EULAR guidelines for musculoskeletal US in rheumatology using a Logiq 9 machine (General Electric Medical Systems, Milwaukee, WI)

equipped with a 6–8 MHz multi-frequency linear probe (22).

The patient was supine with the hip in neutral position (or with a slight external rotation, as proposed by Koski *et al.*) for the anterior aspect assessment (22, 23). The lateral aspect was scanned with the patient lying on the opposite hip assuming an oblique lateral or true lateral position (according to the Musculoskeletal Ultrasound Technical Guidelines - Hip, from the European Society of Musculoskeletal Radiology) (24). Adopting this patient position, the following areas were examined: hip joint, and distal insertion of gluteus medius and gluteus minimus tendon.

The following US pathological findings were recorded (presence/absence): joint synovial effusion, synovial hypertrophy (with or without power Doppler signal), bone erosion, osteophytes, damage of the femoral head cartilage; enthesopathy (for gluteus medius and gluteus minimus tendon). Furthermore, for each joint, the capsular height (distance between the ilio-femoral ligament and the femoral neck) was calculated in millimeters. The hip joint cavity widening was considered if this distance was ≥ 7 mm or the right-left comparison shown a value > 1 mm (23). Synovial effusion and hypertrophy, bone erosion and enthesopathy were considered according to the preliminary definition provided by Outcome Measures in Rheumatoid Arthritis Clinical Trials (OMERACT) (25). Osteophytes and cartilage damage were defined as previously (26, 27), respectively. Power Doppler setting parameters were adjusted according to the indications provided by Torp-Pedersen *et al.* (28). Each pathological US finding was confirmed in almost two perpendicular scans.

Informed consent was obtained from all the patients and the study was carried out after approval by the local ethics committee according to the declaration of Helsinki.

Statistical analysis

Descriptive results are reported as median \pm standard deviation (SD). The relationship between different variables was analysed using Spearman's rank correlation test. *P*-values less than

0.05 were considered statistically significant.

Results

A total of 100 hips were scanned in 52 patients with RA. Four patients underwent unilateral total hip replacement and data acquired at those four hips were not included in the overall results. The demographic and clinical data of the enrolled patients are reported in Table I. Correlation between US findings and demographic, laboratory, and clinical data are shown in Table II.

Approximately half of our patients reported a history of hip pain, one fourth (24%) complained of current pain, and the clinical examination (internal and/or external rotation and palpation of the greater trochanteric region) evoked pain up to 19% and 22% of the patients, respectively.

Table I. Demographic, clinical, laboratory and US data.

A	
Number of patients	52
Age in years (median \pm SD)	62 \pm 15
Male/female (n)	13/39
Disease duration, months (median \pm SD)	116 \pm 88
ERS, mm/h (median \pm SD)	14 \pm 18.6
CRP, mg/dl (median \pm SD)	0.36 \pm 2.99
BMI, kg/m ² (median \pm SD)	22.9 \pm 3
NSAIDs (n. %)	8.15
Steroids (n. %)	26.50
DMARDs (n. %)	28.54
Biological agent (n. %)	23.44
Rheumatoid factor (n. %)	32.62
Antibodies anti-citrullinated peptides (n. %)	27.52
DAS28 (median \pm SD)	3.1 \pm 1.1
Lequesne index (median \pm SD)	2 \pm 5
HAQ score (median \pm SD)	0.7 \pm 0.8
B	
Number of hips	100
History of hip pain	50
Current spontaneous hip pain	48
Evoked pain by internal and external rotation of the hip	38
Evoked pain by the palpation of the great trochanter region	44
US hip joint inflammation	27
US synovial effusion	24
US synovial hypertrophy	24
US hip joint damage	32
US bone erosions	10
US cartilage lesion	32
US osteophytes	18

US: ultrasound; SD: standard deviation; BMI: body mass index; ESR: erythrocyte sedimentation rate; CRP: C-reactive protein; DAS28: Disease Activity Score 28; HAQ: Health Assessment Questionnaire.

Table II. *p*-value of correlations between US findings and demographic, clinical, and laboratory data.

	Capsular height	Synovial effusion	Synovial hypertrophy	Bone erosions	Cartilage lesion	Osteophytes	
Age (years)	0.17	0.90	0.80	0.47	0.02	0.21	
Disease duration (months)	0.95	0.91	0.45	0.02	0.06	0.04	
BMI (kg/m ²)	0.73	0.78	0.89	0.06	0.01	0.57	
ESR (mm/h)	0.94	0.79	0.62	0.60	0.06	0.82	
CRP (mg/dl)	0.99	0.37	0.92	0.81	0.17	0.31	
Rheumatoid factor	0.17	0.46	0.17	0.89	0.70	0.63	
Antibodies anti-citrullinated peptides	0.14	0.30	0.67	0.60	0.69	0.79	
Lequesne index	0.20	0.13	0.21	0.19	0.30	0.80	
DAS 28	0.82	0.67	0.42	0.54	0.75	0.81	
HAQ	0.27	0.20	0.35	0.89	0.10	0.23	
		0.092		0.039		0.048	
	Capsular height	Synovial effusion	Synovial hypertrophy	Bone erosions	Cartilage lesion	Osteophytes	Minimus and/or medius gluteus tendinopathy
History of hip pain	0.046	0.15	0.09	0.21	0.04	0.005	0.89
Current spontaneous hip pain	0.010	0.31	0.007	0.28	0.64	0.07	0.34
Evocated pain by internal and external rotation of the hip	0.016	0.009	0.002	0.007	0.006	0.24	0.46
Evocated pain by the palpation of the great trochanter region	0.28	0.43	0.21	0.68	0.13	0.13	0.34

BMI: body mass index; ESR: erythro sedimentation rate; CRP: C-reactive protein; DAS28: Disease Activity Score 28; HAQ: Health Assessment Questionnaire.

US examination found signs of hip joint abnormalities in 42% of the patients; US changes indicative of hip joint inflammation and damage were detected respectively in 24% and 32% of the cases. A pathological measurement of the capsular height was recorded in 42% of patients. No patient presented power Doppler signal in the hip joint. Figure 1 shows representative examples of US findings indicative of hip joint inflammation and damage.

A significant correlation was found between age and cartilage damage, and disease duration and the presence of bone erosions and osteophytes, respectively, while age and disease duration have not resulted to correlate either with synovial effusion and/or hypertrophy or with the value of measurement of the joint distension in the anterior recess. Body mass index (BMI) presented a significant correlation only with the cartilage involvement.

Taking into account the laboratory tests, we did not find any correlation between either acute phase reactants (ESR and CRP) or rheumatoid factor and antibodies anti-citrullinated peptides with any US finding of joint involvement.

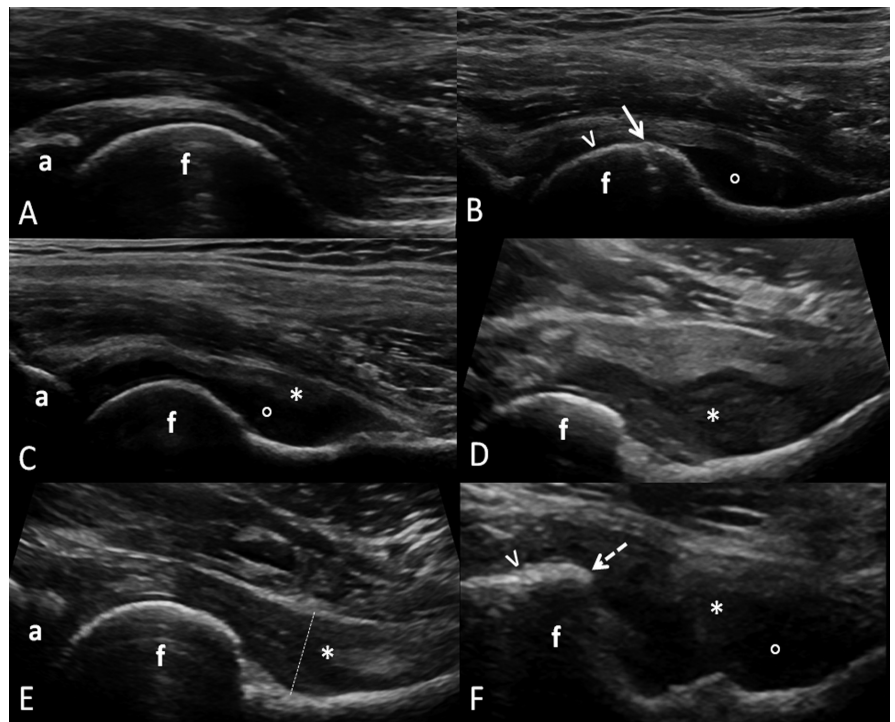


Fig. 1. Hip joint. Longitudinal anterior scan. **A.** Healthy subject. **B-F.** Images showing representative examples of US findings indicative of hip joint inflammation and damage. In **B**, synovial effusion (°), bone erosion (arrow), and cartilaginous lesion (arrowhead); in **C**, synovial effusion (°) and hypertrophy (*); in **D**, synovial hypertrophy, with an evident joint cavity widening (convexity of the capsular outline at femoral neck level); in **E**, synovial hypertrophy (*) with a minimal joint cavity widening (concavity of the capsular outline at femoral neck level) and capsular height less than 7 mm (dotted line); in **F**, synovial effusion (°) and hypertrophy (*), an osteophyte (dotted arrow) and cartilage damage (arrowhead). a: acetabulum; f: femur.

(DAS28 or Lequesne index), and US signs of hip involvement.

HAQ score did not correlate significantly with any specific US pathological finding, but a positive correlation was found with the presence of at least one US pathological finding.

As regards clinical findings, there was a significant correlation between the tenderness during internal and external rotation and all US findings indicative of hip joint disease, except capsular height and osteophytes.

Discussion

To the best of our knowledge, this is the first study in RA patients, aimed to investigate the correlation of clinical and laboratory data with US findings indicative of abnormalities in the hip area, including both joint and peri-articular structures.

Even if in the recent ACR/EULAR classification criteria for RA, large joints have a lower weight than small joints in the score-based algorithm, their involvement is not uncommon and is clinically relevant. A radiographic evidence of disease has been reported in up to 90% for the shoulder, 60% for the elbow, 30% for the knee (2-6). At hip level, 20–50% of well-established RA subjects present radiographic signs of the disease, with relevant impact on the quality of life (3, 4).

We found that more than half of the patients recruited in the present study experienced past and/or current pain at hip level. It is interesting to note that tenderness was induced by the internal and/or external rotation only in 56% of patients with current spontaneous pain, suggesting that they may refer “hip joint pain” even when also extra-articular structures are involved (in half of the cases, tendinopathy of gluteus minimus and/or medius was found).

The US assessment revealed hip abnormalities in almost half of the patients, and osteochondral pathology resulted more common than synovial effusion/hypertrophy (one fourth and one third, respectively).

Measurement of the capsular height provided a higher number of inflamed hip joints with respect to the detection of synovial effusion and/or hypertrophy,

suggesting a discrepancy between the quantitative assessment and the qualitative one. In the absence of a gold standard it is impossible to establish if these data are related to the fact that the latter assessment underestimates or the former one overestimates the hip involvement. The difficulty in the qualitative detection of joint cavity widening when only a small amount of synovial hypertrophy with no concomitant joint effusion is present, may explain this discrepancy. This is supported by the fact that in 2 of the 3 cases with a pathological capsular height value less than 7 mm, arising from the right-left comparison higher than 1 mm, no fluid was found in the pathological side. Thus, it is important to underline the importance of a comparative assessment of hip joint.

The absence of power Doppler signal at synovial tissue level is in line with the results of other studies using US to assess the hip. The most likely explanation is related to the depth of the joint, especially in overweight patients, which requires low frequency probes with a consequent reduction of power Doppler sensitivity (29, 30).

Cartilage damage was the most common US finding indicative of hip joint damage. Osteophytes were found in almost one fifth of cases and such a percentage is similar to that obtained in a recent paper conducted in patients with psoriatic arthritis (30). The relative low prevalence of US bone erosions can be explained by the limited acoustic window (30).

The disease duration correlated positively with bone erosions and osteophytes, but not with cartilage lesion. This may be interpreted as the result of the fact that in RA patients the cartilage involvement can occur in the earliest stage of the hip joint damage. Moreover, the positive correlation between the cartilage damage and the BMI supports the role of the mechanical factor. In contrast with the positive correlation observed in other inflammatory arthritis, no correlation between acute phase reactants and hip involvement was observed in the RA patients of the present study. In a recent paper it has been shown that CRP values were higher in subjects affected by ankylosing spond-

ylitis presenting US abnormalities at hip joint level (31). The authors argued that a high CRP value can be considered an important laboratory parameter to perform an US examination of the hip even in asymptomatic patients with ankylosing spondylitis (31). According to our results, the decision to scan the hip in patients with RA should not depend only on the laboratory findings.

No correlation was found between DAS28 and US signs of hip disease. This can be considered an expected result considering that the calculation of DAS28 does not include the hip among the count of tender and/or swollen joints. Nevertheless, these data, together with those about ESR and CRP, suggest a lack of correlation between hip involvement and disease activity in RA.

Moreover, the Lequesne index was not correlated with sonographic abnormalities at hip level. A possible explanation can be the fact that this index was designed for hip osteoarthritis. In RA the final value may be influenced by the concomitant involvement of other anatomic sites of the lower limbs, such as knee, ankle or foot.

If considered separately, each US finding did not reach a significant correlation with the HAQ score. We found a significant correlation between HAQ score and the presence of US evidence of hip joint damage, suggesting an important role of this in the global health of RA.

We found a significant correlation between the tenderness caused by internal and external rotation and all US findings indicative of hip joint involvement (with the exception of the presence of osteophytes). On the other hand, a history of hip pain and a spontaneous current hip pain correlated with synovial hypertrophy, and cartilage damage and osteophytes, respectively.

These data underline that an accurate physical examination is a fundamental step for the physician to reveal hip involvement in RA patients. Nevertheless, it does not give univocal information indicative for the presence of active joint inflammation or early joint damage.

For extra-articular structures, it could be interesting to note the lack of correlation between tenderness by palpation of the greater trochanteric region and the pres-

ence of gluteus minimum and/or medius tendinopathy. However, the presence of tendinopathy in the greater trochanteric region is commonly described by the patient as a "hip pain", representing a potential confusing factor.

Taking all these data together, we may argue that in an elderly patient with long-standing RA we can expect to find US osteochondral abnormalities, while a current spontaneous pain, especially when enhanced by mobilisation of the hip, suggests the presence of US evidence of hip joint inflammation, such as synovial fluid and/or pannus.

The results of the present study should be interpreted in the light of the following limitations. Firstly, given the small cohort and the consequent small sample size effect, it must be considered as a preliminary study. The number of enrolled patients did not allow us to calculate data of prevalence. Furthermore, the present study is a cross-sectional study and does not provide longitudinal information. A larger cohort and a longitudinal evaluation are required to select sub-groups of patients and to assess the effect of different parameters on the patient outcome. Finally, the lack of a "gold standard" technique in assessing the hip inflammatory changes did not allow us to extrapolate information on sensitivity and specificity of clinical and US examinations, and a comparison between these two assessments.

In conclusion, hip pain is common in patients with RA, and both clinical and US assessments were positive in a high number of patients. Furthermore, we found a strong correlation between some clinical features and US findings indicative of hip joint involvement in RA. Nevertheless, an accurate collection of clinical history and physical examination can only lead to the suspicion of hip pathology which requires imaging findings to be confirmed. Finally, laboratory data may not help the physician to identify RA patients with a high suspicion of hip involvement. The results of the present study suggest the need to integrate the clinical and laboratory-based assessment of the hip in RA with the US examination to confirm the suspicion or to reveal sub-clinical hip involvement.

Further studies are needed to evaluate if the additional data obtained by US can play a role in predicting the patient's outcome and in the treatment decision making.

References

1. LEE DM, WEINBLATT ME: Rheumatoid arthritis. *Lancet* 2001; 358: 903-11.
2. LEARCH TJ: Imaging of rheumatoid arthritis. In: HOCHBERG M (Ed.) *Rheumatology*. Edinburgh: Mosby, 2008: 793-800.
3. HARRIS ED JR, FIRESTEIN G: Clinical features of rheumatoid arthritis. In: FIRESTEIN GS, BUDD RC, HARRIS ED JR, MCINNES IB, RUDDY S, SERGENT JS *Kelley's Textbook of Rheumatology* (8th ed.): Saunders Elsevier, 2008: 1095.
4. HARTUNG W, KELLNER H, STRUNK J *et al.*: Development and evaluation of a novel ultrasound score for large joints in rheumatoid arthritis: one year of experience in daily clinical practice. *Arthritis Care Res* 2012; 64: 675-82.
5. DROSSAERS-BAKKER KW, KROON HM, ZWINDERMAN AH *et al.*: Radiographic damage of large joints in long-term rheumatoid arthritis and its relation to function. *Rheumatology* 2000; 39: 998-1003.
6. SLEDGE CB: Introduction to surgical management of patients with arthritis. In: SAUNDERS WB (Ed.) *Kelley's Textbook of Rheumatology*. Philadelphia; 2001.
7. BENONI AC, BREMANDER A, NILSDOTTER A: Patient-reported outcome after rheumatoid arthritis-related surgery in the lower extremities. *Acta Orthop* 2012; 83: 179-84.
8. WALTHER M, HARMS H, KRENN V, RADKE S, KIRSCHNER S, GOHLKE F: Synovial tissue of the hip at power Doppler US: correlation between vascularity and power Doppler US signal. *Radiology* 2002; 225: 225-31.
9. HARTUNG W, KELLNER H, STRUNK J *et al.*: Development and evaluation of a novel ultrasound score for large joints in rheumatoid arthritis: one year of experience in daily clinical practice. *Arthritis Care Res* 2012; 64: 675-82.
10. RIENTE L, DELLE SEDIE A, SCIRÈ CA *et al.*: Ultrasound imaging for the rheumatologist. XXXI. Sonographic assessment of the foot in patients with rheumatoid arthritis. *Clin Exp Rheumatol* 2011; 29: 1-5.
11. RIENTE L, DELLE SEDIE A, FILIPPUCCI E *et al.*: Ultrasound imaging for the rheumatologist XXVII. Sonographic assessment of the knee in patients with rheumatoid arthritis. *Clin Exp Rheumatol* 2010; 28: 300-3.
12. FILIPPUCCI E, IAGNOCCO A, MEENAGH G *et al.*: Ultrasound imaging for the rheumatologist VII. Ultrasound imaging in rheumatoid arthritis. *Clin Exp Rheumatol* 2007; 25: 5-10.
13. GUTIERREZ M, FILIPPUCCI E, SALAFFI F, DI GESO L, GRASSI W: Differential diagnosis between rheumatoid arthritis and psoriatic arthritis: the value of ultrasound findings at metacarpophalangeal joints level. *Ann Rheum Dis* 2011; 70: 1111-4.
14. IAGNOCCO A, FILIPPUCCI E, MEENAGH G *et al.*: Ultrasound imaging for rheumatologist III. Ultrasonography of the hip. *Clin Exp Rheumatol* 2006; 24: 118-22.
15. ARNETT FC, EDWORTHY SM, BLOCH DA *et al.*: The American Rheumatism Association 1987 revised criteria for the classification of rheumatoid arthritis. *Arthritis Rheum* 1988; 31: 315-24.
16. ALETAHAD, NEOGIT, SILMAN AJ *et al.*: 2010 Rheumatoid arthritis classification criteria: an American College of Rheumatology/European League Against Rheumatism collaborative initiative. *Arthritis Rheum* 2010; 62: 2569-81.
17. VAN RIEL PL: Provisional guidelines for measuring disease activity in clinical trials on rheumatoid arthritis. *Br J Rheumatol* 1992; 31: 793-6.
18. FELSON DT, ANDERSON JJ, BOERS M *et al.*: The American College of Rheumatology preliminary core-set of disease activity measures for rheumatoid arthritis clinical trials. *Arthritis Rheum* 1993; 36: 729-40.
19. VAN DER HEIJDE DM, VAN'T HOF M, VAN RIEL PL *et al.*: Development of a disease activity score based on judgement in clinical practice by rheumatologists. *J Rheumatol* 1993; 20: 579-81.
20. LEQUESNE M, MERY C, SAMSON M, GERARD P: Indexes of severity for osteoarthritis of the hip and knee. Validation—value in comparison with other assessment tests. *Scand J Rheumatol* 1987; 65: 85-9.
21. FRANCHIGNONI F, SALAFFI F, GIORDANO A, CIAPETTI A, CAROTTI M, OTTONELLO M: Psychometric properties of index-administered Lequesne Algofunctional Indexes in patients with hip and knee osteoarthritis: an evaluation using classical test theory and Rasch analysis. *Clin Rheumatol* 2012; 31: 113-21.
22. BACKHAUS M, BURMESTER GR, GERBER T *et al.*: Working Group for Musculoskeletal Ultrasound in the EULAR Standing Committee on International Clinical Studies including Therapeutic Trials. Guidelines for musculoskeletal ultrasound in rheumatology. *Ann Rheum Dis* 2001; 60: 641-9.
23. KOSKI JM, ANTILLA PJ, ISOMÄKI HA: Ultrasonography of the adult hip joint. *Scand J Rheumatol* 1989; 18: 113-7.
24. <http://www.essr.org/html/img/pool/hip.pdf>
25. WAKEFIELD RJ, BALINT PV, SZKUDLAREK M *et al.*: Musculoskeletal ultrasound including definitions for ultrasonographic pathology. *J Rheumatol* 2005; 32: 2485-7.
26. GRASSI W, FILIPPUCCI E, FARINA A: Ultrasonography in osteoarthritis. *Semin Arthritis Rheum* 2005; 34: 19-23.
27. MEENAGH G, FILIPPUCCI E, IAGNOCCO A *et al.*: Ultrasound imaging for the rheumatologist VIII. Ultrasound imaging in osteoarthritis. *Clin Exp Rheumatol* 2007; 25: 172-5.
28. TORP-PEDERSEN ST, TERSLEV L: Settings and artefacts relevant in colour/power Doppler ultrasound in rheumatology. *Ann Rheum Dis* 2008; 67: 143-9.
29. MEENAGH G, SAKELLARIOU G, IAGNOCCO A *et al.*: Ultrasound imaging for the rheumatologist XXXIX. Sonographic assessment of the hip in fibromyalgia patients. *Clin Exp Rheumatol* 2012; 30: 319-21.
30. RIENTE L, DELLE SEDIE A, SAKELLARIOU G *et al.*: Ultrasound imaging for the rheumatologist XXXVIII. Sonographic assessment of the hip in psoriatic arthritis patients. *Clin Exp Rheumatol* 2012; 30: 152-5.
31. SAKELLARIOU G, IAGNOCCO A, MEENAGH G *et al.*: Ultrasound imaging for the rheumatologist XXXVII. Sonographic assessment of the hip in ankylosing spondylitis patients. *Clin Exp Rheumatol* 2012; 30: 1-5.