

**Successful adalimumab treatment of HLA B27 negative heel enthesitis documented with MRI and US**

Sirs,

Enthesitis is a well-known hallmark of spondyloarthritis (SpA) (1). No set of classification criteria can identify patients presenting isolated peripheral enthesitis and there are no guidelines regarding its treatment. Recently, several reports have proposed the use of tumour necrosis factor alpha (TNF- $\alpha$ ) antagonists (infliximab, etanercept, adalimumab) in the treatment of refractory heel enthesitis in HLA B27 positive SpA (2-4).

We report the successful use of adalimumab in a patient with an erosive, seronegative, isolated enthesopathy and we document the response to therapy with magnetic resonance imaging (MRI) and ultrasonography (US).

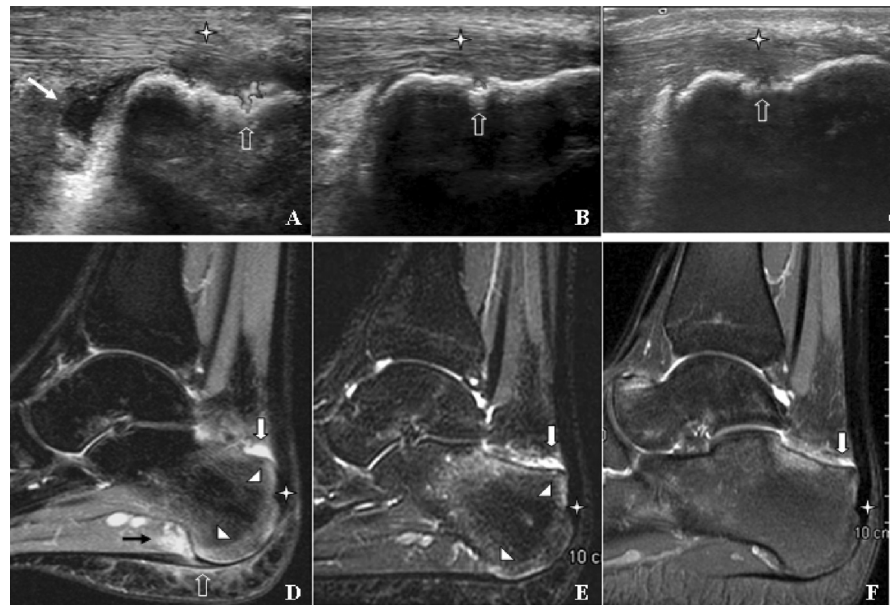
A 19-year-old Caucasian male student was referred to us with a 15-month history of talgia on the left foot, more severe during the first steps on rising, worsened by sport activity, and with serious disability.

He had no personal or family history of psoriasis or SpA; he denied traumatic injury and any typical SpA features. Previous treatments (3 months at full doses of diclofenac and ibuprofen; physical therapy, multiple steroid injections) failed. Clinical examination revealed soft tissue swelling at the insertion of the left Achilles tendon, with pain on dorsiflexion and inversion of the foot, and tenderness of plantar fascia. There was no restriction of spinal mobility or pain/swelling peripheral joint or enthesal sites or psoriatic skin lesions or nail dystrophy.

Both the Maastricht Ankylosing Spondylitis Enthesitis Score (MASES) (5) and the Leeds Enthesitis Index were 1 (6). The visual analogue scale (VAS) pain level was 100. Erythrocyte sedimentation rate and C-reactive protein were normal; rheumatoid factor and HLA-B27, 38 and 39 genotype were negative.

MRI of the left foot showed thickness of the insertion of both the Achilles tendon and plantar fascia; a retrocalcaneal bursitis, bone marrow oedema of the calcaneus. US evaluation showed a diffuse hypoechoic thickening of the Achilles tendon enthesitis and plantar fascia with bone cortical break at both insertions, and a deep retrocalcaneal bursitis. Power Doppler signal (PDS) was positive at both sites (Fig. 1).

Because of the severity of clinical and radiological findings and since data about the efficacy of sulfasalazine and methotrexate on peripheral enthesitis are conflicting (7), we decided to start adalimumab therapy (40 mg every other week) after obtaining written informed consent from the patient. In-



**Fig. 1.** MRI and US images of the left foot.

Longitudinal US images showed a mild thickening and reduced echogenicity of normal fibrillar echotexture of the Achilles tendon related to inflammatory oedema (star), distension of retrocalcaneal bursae (white solid arrow), bone cortical erosions in the proximal part of the enthesitis with signs of hypervascularisation on power Doppler imaging inside the erosion (open arrow), before (A), after 3 (B) and 6 months (C) of therapy.

Sagittal MRI fat-sat images showing irregularities of cortical bone at the enthesitis of the Achilles tendon (star), retrocalcaneal bursitis (white solid arrow), diffuse bone marrow oedema (arrowheads), particularly at the insertions of both the Achilles tendon and plantar fascia, soft tissue oedema (black solid arrow), and plantar fasciitis (open arrow). Findings improved progressively, as shown in the following images: before (D), after 3 (E) and 6 months (F) of therapy.

deed, ASAS/EULAR recommendations for the management of ankylosing spondylitis suggest anti-TNF- $\alpha$  in patients with symptomatic enthesitis for whom appropriate local treatment failed (8). Finally, the Italian guidelines for the appropriate use of anti-TNF- $\alpha$  therapy in patients with psoriatic arthritis suggest their use in patients with peripheral enthesitis resistant to conventional therapies (9).

Anti-TNF- $\alpha$  treatment led to rapid and marked improvement of signs and symptoms after first injection with significant improvement in the VAS pain, MASES and LEI scores; at third month of follow-up they were 10, 0 and 0, respectively. Heel MRI and US showed gradual and marked improvement during the six months of therapy (Fig. 1). At the last clinical examination (at ninth month of therapy) no residual inflammatory signs were noted and the VAS pain was 0. We decided to continue adalimumab therapy until the normalisation of MRI and US findings.

We report the description of the first case of undifferentiated isolated heel enthesitis in a HLA B27 negative patient without other signs of undifferentiated SpA treated successfully with anti-TNF- $\alpha$  therapy. We decided to perform both US and MRI imaging modalities to detect and monitor heel enthesitis since they provide distinct data: MRI is important to assess the presence of bone oedema, whereas US combined with PDS was used to measure the increased blood flow due to inflammation (10). We

suggest that therapy could be stopped when MRI bone oedema and PDS are completely resolved.

L. MANCARELLA<sup>1</sup>,  
M. BATTAGLIA<sup>2</sup>,  
O. ADDIMANDA<sup>1</sup>,  
P. PELOTTI<sup>2</sup>,  
S. GALLETTI<sup>2</sup>,  
R. MELICONI<sup>3</sup>

<sup>1</sup>Rheumatology Unit, <sup>2</sup>Ultrasonology Unit, Istituto Ortopedico Rizzoli, Bologna, Italy; <sup>3</sup>Rheumatology Unit, Istituto Ortopedico Rizzoli and University of Bologna, Bologna, Italy.

Address correspondence and reprint requests to: Riccardo Meliconi, MD, Rheumatology Unit, Istituto Ortopedico Rizzoli, Via Pupilli 1, 40136 Bologna, Italy.

E-mail: riccardo.meliconi@ior.it

Competing interests: none declared.

**References**

1. D'AGOSTINO MA, OLIVIERI I: Enthesitis. *Best Practice & Research Clinical Rheumatology* 2006; 20: 473-86.
2. D'AGOSTINO MA, BREBAN M, SAID-NAHAL R, DOUGADOS M: Refractory inflammatory heel pain in spondylarthropathy: a significant response to infliximab documented by ultrasound. *Arthritis Rheum* 2002; 46: 840-1.
3. OLIVIERI I, SCARANO E, PADULA A, D'ANGELO S, CANTINI F: Switching tumor necrosis factor  $\alpha$  inhibitors in HLA-B27-associated severe heel enthesitis. *Arthritis Rheum* 2007; 57: 1572-4.
4. OLIVIERI I, SCARANO E, GIGLIOTTI P, GIASI V, PADULA A: Successful treatment of juvenile-onset HLA B27 associated severe and refractory heel enthesitis with adalimumab documented by magnetic resonance imaging. *Rheumatology (Oxford)* 2006; 45: 1315-7.

## Letters to the Editor

---

5. HEUFT-DORENBOSCH L, SPOORENBERG A, VAN TUBERGEN A *et al.*: Assessment of enthesitis in ankylosing spondylitis. *Ann Rheum Dis* 2003; 62: 127-32.
6. HEALY PJ, HELLIWELLS PS: Measuring clinical enthesitis in psoriatic arthritis: assessment of existing measures and development of an instrument specific to psoriatic arthritis. *Arthritis Rheum* 2008; 59: 686-91.
7. GENÇ H, DUYUR ÇAKIT B, NACIR B, SARA-  
COĞLU M, KACAR M, ERDEM HR: The effects of sulfasalazine treatment on enthesal abnormalities of inflammatory rheumatic diseases. *Clin Rheumatol* 2007; 26: 1104-10.
8. ZOCHLING J, VAN DER HEIJDÉ D, BURGOS-VARGAS R *et al.*: ASAS/EULAR recommendations for the management of ankylosing spondylitis. *Ann Rheum Dis* 2006; 65: 442-52.
9. SALVARANI C, OLIVIERI I, PIPITONE N *et al.*:  
Recommendations of the Italian Society for Rheumatology for the use of biologic (TNF-alpha blocking) agents in the treatment of psoriatic arthritis. *Clin Exp Rheumatol* 2006; 24: 70-8.
10. D'ANGELO S, PADULA A, NIGRO A *et al.*: Italian evidence-based recommendations for the management of ankylosing spondylitis: the 3E Initiative in Rheumatology. *Clin Exp Rheumatol* 2008; 26: 1005-11.