

Ultrasound imaging for the rheumatologist

XLVI. Ultrasound-guided injection in the shoulder: a descriptive literature review

A. Delle Sedie¹, L. Riente¹, A. Iagnocco², L. Carli¹, F. Ceccarelli², L. Di Geso³,
E. Filippucci³, G. Sakellariou⁴, S. Bombardieri¹

¹Rheumatology Unit, University of Pisa, Pisa, Italy; ²Rheumatology Unit, Department of Internal Medicine, Sapienza University of Rome, Policlinico Umberto I°, Rome, Italy; ³Rheumatology Clinic, Polytechnic University delle Marche, Jesi, Italy; ⁴Chair and Division of Rheumatology, IRCCS Polyclinic San Matteo Foundation, Pavia, Italy.

Andrea Delle Sedie, MD
Lucrezia Riente, MD
Annamaria Iagnocco, MD
Linda Carli, MD
Fulvia Ceccarelli, MD
Luca Di Geso, MD
Emilio Filippucci, MD
Garifallia Sakellariou, MD
Stefano Bombardieri, MD, Prof.

Please address correspondence to:
Andrea Delle Sedie, MD,
U.O. Reumatologia,
Università di Pisa,
Via Roma 67,
Pisa 56126, Italy.
E-mail: adellese@lycos.com

Received on June 30, 2013; accepted in revised form on July 17, 2013.

Clin Exp Rheumatol 2013; 31: 477-483.

© Copyright CLINICAL AND EXPERIMENTAL RHEUMATOLOGY 2013.

Key words: ultrasound, shoulder, injection, corticosteroid, hyaluronic acid

ABSTRACT

Shoulder pain represents one of the most frequent clinical conditions in the general population and it can be generated by a large spectrum of pathologies. The most frequent approach of most rheumatologists to shoulder pain, in daily clinical practice, mainly based on their personal experience, is to locally inject drugs. Since the literature on this topic provides conflicting results due to the wide heterogeneity in the study designs, we decided to report the most relevant studies. Not enough data are available to assess whether US-guided injections are more efficient in controlling shoulder pain with respect to the landmark approach. However, it is likely that US-guided technique shows a more rapid improvement, possibly by providing a higher corticosteroid volume injected right where it is needed. When injecting hyaluronic acid, a more accurate localisation of the medicament might be useful to improve efficacy and avoid adverse effects (i.e. pain), however, there are no studies comparing the blind approach to the US-guided one. Finally, new treatments for shoulder pain have been used but they still need future validation in more appropriate RCTs.

Introduction

Shoulder pain represents one of the most frequent clinical conditions in the general population, with a prevalence ranging from 7% to 10% in different studies (1) and it can be generated by a large spectrum of pathologies, related to the complexity of this anatomic site, involving joints, tendons and bursae, which frequently overlap. Different approaches to shoulder pain have been applied by rheumatologists in daily

clinical practice (i.e. systemic and/or local drugs administration, physical therapy or their combinations), mainly based on the personal experience of the physician. In fact, the scientific evaluation of the efficacy of different kinds of treatment has produced conflicting results, which are the natural consequence of the wide heterogeneity in the study designs. The diagnosis and the monitoring of the efficacy have been obtained using methods with different sensitivity, such as questionnaires, physical examination or imaging modalities (x-ray, ultrasound, MRI), at different times (short- or long-term monitoring). Moreover, both local and systemic factors may affect in different ways the subjective improvement referred by patients after an injection for shoulder pain. In fact, specific shoulder conditions could influence response to the corticosteroid (CS) injection in varying degrees (i.e. acute inflammation might be more likely to respond to injections than conditions such as rotator cuff tears or long-standing degenerative joint disease), and patients with active inflammatory arthritis may experience a benefit from CS injection independently of their shoulder pathology (2). Shoulder pain can also resolve spontaneously and local injection has a significant placebo effect (3-5). Even if it has been demonstrated that CS works better than oral non-steroidal anti-inflammatory drugs (NSAIDs) in reducing pain, increasing active abduction and improving functional limitation in patients with rotator cuff tendonitis (6), conflicting results were obtained comparing CS plus lidocaine to lidocaine alone (in subacromial impingement syndrome patients) (7-8). No definite results are provided regarding the dose

Competing interests: none declared.

of CS to inject (triamcinolone acetate 40 mg failed to be more effective with respect to 20 mg) (9) and whether a local or systemic injection is the most effective (no differences between ultrasound (US)-guided CS injection in the subacromial bursa and gluteal injections for improvement in the overall shoulder pain and disability index score) (10).

Furthermore, in the case of the local injection therapy, the procedure can be performed using the anatomic landmarks (blinded) or guided-methods (fluoroscopy or ultrasound). In the last decade, the US-guided approach has been chosen by a large number of rheumatologists attracted by the opportunity to obtain higher rates of correct placement of the medication (much less than 50% of the blind injections are accurately placed (11)). Even if there is not a unequivocal literature supporting the fact that this goal always means higher efficacy than the blinded procedures, especially for soluble drugs such as CS (12), it is reasonable to hypothesise that a higher level of accuracy could imply a higher degree of safety. Another relevant advantage of the US-guided procedure is that the approach can be tailored to the patient, after a preliminary US evaluation, according to the most suitable insertion site for both the patient and the operator, thus reducing the risks (*i.e.* neuro-vascular bundle contact) and the patient's discomfort. Finally, while the clinically oriented procedures are, paradoxically, based on normal anatomy, US-guided injections can be strictly personalised according to the pathologic condition. Injection in the shoulder area could allow the administration of different drugs or substances: anesthetics, CS, hyaluronic acids (HA) and new drugs. The first group is not the field of the rheumatologist, however, there is a great deal of literature dealing with this and more than 90 papers are actually present in PubMed. US guidance, in that case, is used to reach the diffusion areas, typically around vessels, possibly minimising the dose of the drug. The other groups are the main interest for rheumatologists and those will be discussed in this review.

Materials and methods

Search strategy

The search for relevant papers was performed using the electronic databases MEDLINE (PubMed) and EMBASE, as well as a manual search of the abstracts accepted at the EULAR and ACR meetings held in 2012. No language or publication restrictions were applied at this step. Two strings of research were used in MEDLINE (PubMed) with different sensitivities:

- (“Shoulder/ultrasonography” [Mesh]) OR “Shoulder Pain/ultrasonography” [Mesh]) OR “Shoulder Impingement Syndrome/ultrasonography” [Mesh]) OR “Bursitis/ultrasonography” [Mesh]) AND “Injections” [Mesh].
- (“shoulder” [MeSH Terms] OR “shoulder” [All Fields]) AND (“ultrasonography” [Subheading] OR “ultrasonography” [All Fields] OR “ultrasound” [All Fields] OR “ultrasonography” [MeSH Terms] OR “ultrasound” [All Fields] OR “ultronics” [MeSH Terms] OR “ultronics” [All Fields]) AND (“injections” [MeSH Terms] OR “injections” [All Fields] OR “injection” [All Fields])

The search in the EMBASE electronic database was made both using the emtree and free language. The search was meant to be quite broad, to be more sensitive than specific, and was last carried out on May 23rd, 2013.

Eligibility criteria

After completion of the search, all randomised controlled trials referring to ultrasound-guided injections into the shoulder were included in the review, while papers referring to paediatric, animal and cadaver studies as well as articles published in languages other than English, French or Italian were now excluded.

Study selection

The titles of all of the papers were examined and the abstracts read. In the case of eligibility, the full-text article was retrieved and assessed. In the end, the ones considered to be suitable (RCT involving US-guided injections of CS and HA in the shoulder) were included in the review. We also included studies

on other substances, to report what the future direction of the research could be.

Results

The search strategy identified a total of 514 records: 222 papers in the electronic databases MEDLINE (PubMed) (24 using MESH string and 215 using only the boolean connector “AND”, with 17 duplicate titles) and 292 in EMBASE (48 records from the em-tree and 301 from the free language, with 57 duplicate titles). After duplication screening, 303 records remained. The manual search of the abstracts accepted at the EULAR and ACR meetings yielded 3 records in the EULAR and 1 in the ACR 2012 meeting. Figure 1 shows the selection process and the final result. The search also retrieved the systematic review already published (13-15). The main point arising from the reading of the papers is that a relevant degree of variability is detectable between the studies. In fact all of the studies differ in many important points (*i.e.* design, patients enrolled, drug used, etc.). For this reason, we decided to report only the most relevant studies without making any meta-analysis, while trying to give the reader most of the information available to decide whether and when to use the US-guided technique.

CS injection

Strong evidence supporting the US-guided approach or the blind approach is lacking, mainly due to the design of the studies published. In some studies, the US and blind approaches cannot be compared because of the different diseases or targets to inject in the patients enrolled.

Recently, at least three systematic reviews have investigated the field of US-guided vs. blind approach CS injections in the shoulder (13-15): one of those, a particularly exhaustive review, concluded that there were no significant differences (14), two demonstrated significant but minimal US-guided approach superiority (13, 15).

Some papers are included in all of those systematic reviews (2, 16), while some others are included in two of them (17-18) or just in a single review (19-21),

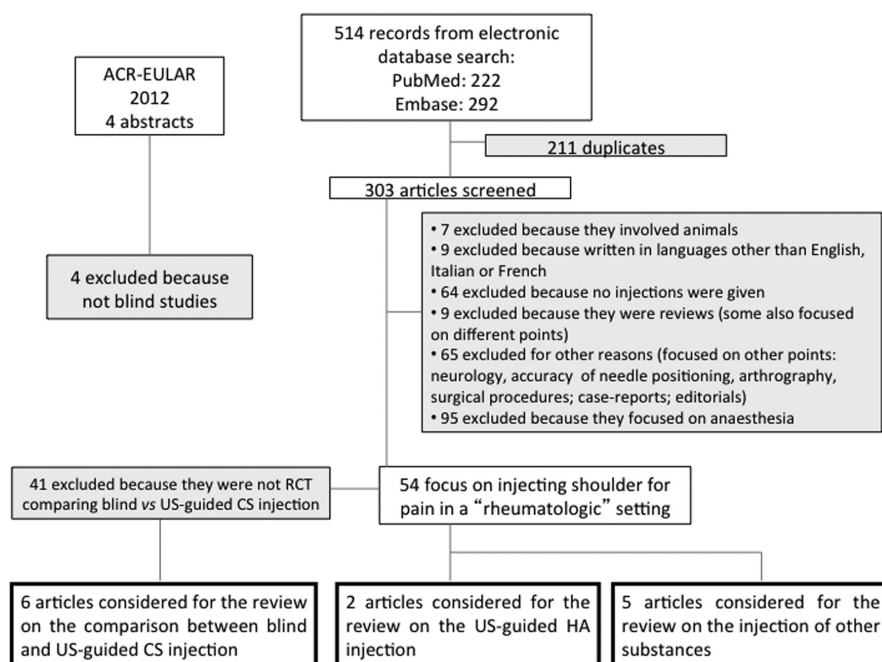


Fig. 1. flow chart showing the selection process.

irrespective of the date of publication. Given the fact that we are not making any meta-analysis, we report all of the RCTs that may give the data needed to clarify whether US-guided procedures are providing better results with respect to blind injection.

Naredo *et al.* first published an interesting paper on a RCT comparing blind injection vs. US-guided injection of local CS in patients with painful shoulder (16). They included different causes of acute pain (impingement, rotator cuff tear, subacromial-subdeltoid bursitis, biceps tenosynovitis, while previous trauma or chronic inflammatory arthritis were excluded) and different injection approaches. The lateral approach, directed at the subacromial-subdeltoid bursa, was used for the blind injection (group 1), while the US-guided procedure was both directed at the bursa and the biceps tendon (depending on where the effusion was localised) or peri or intralesional when rotator cuff calcifications were found (respectively in 14, 3 and 4 patients) (group 2). In the end, only 14/21 of the group 1 received a similar injection (at least aiming at the same point) with respect to the 20/20 of the first group. The results on pain (VAS 0–100) and function (Shoulder Function Assessment [SFA]) were given comparing the whole group

1 to the whole group 2. A significantly greater improvement in SFA and VAS scores was demonstrated at six weeks for group 2. Needle placement was accurate in all of the patients of group 2 while only in 3/20 in group 1 (plus 3 others where CS was positioned both in the bursa and deltoid muscles).

A few years later, Ucuncu *et al.* published a new RCT comparing US- to landmark-guided injections for shoulder pain (2). The authors included in the same group patients with very different shoulder pathologic conditions (acromioclavicular degeneration, rotator cuff lesions – considering full or partial rupture, tendinosis, impingement, calcification – effusion in biceps tendon, partial tear of biceps tendon, bursitis) and they were not randomised according to the real cause of the disease. Besides, again, blind injection used the lateral approach in the subacromial region, while the US-guided ones were administered perilesionally or intralesionally, so using a different anatomical approach. Thirty patients were allocated to group 1 (landmark-guided injection) and the same number to group 2 (US-guided injection), and no significant differences were found in the composition of the two groups. A significantly better improvement in Constant scale, in ROM and a decrease

in pain (VAS score) was demonstrated in group 2.

In 2006, Chen *et al.* published a two-arm controlled clinical trial in 40 patients with subacromial bursitis (17). In this study, all the patients had a US examination performed prior to the procedure and effusion in the bursa was assessed. The needle was moved trying to aspirate the effusion before the injection in both groups. The shoulder abduction range after one week was the primary outcome of the study and it was demonstrated to be significantly improved only in the US-guided injection group, with a significant statistical difference between the two groups.

Lee *et al.* studied the efficacy of US-guided intra-articular injections compared with the blind approach for the treatment of adhesive capsulitis (18). In this RCT, forty-three patients were enrolled after clinical radiologic examinations and US study confirming the presence of adhesive capsulitis. Forty patients completed the study. All the patients received a CS intra-articular injection mixed with lidocaine and normal saline, followed by 5 weekly injections of HA. The main outcome measures were: pain intensity (VAS), ROM (shoulder flexion, abduction, external rotation, and internal rotation) and general shoulder function during daily activities at every week after injection for 6 weeks. Injections were made using a posterior approach in both groups. A statistically significant improvement was demonstrated in pain intensity in the first two weeks in the US-guided injection group; no further significant differences were noted beyond the third week. Internal rotation ROM improved significantly in the US-guided group up to the fourth week, after which no differences were noted between the groups. Shoulder function score improvement was significantly higher in the US-guided group for the first three weeks. So, apparently, the US-guided group had significantly better results than the other one in all of the three outcomes at the first week, when only CS were used.

More recently, Zufferey *et al.* compared US-guided with standard injection for the management of acute painful shoul-

Table 1. The most important paper examined in the text.

Author (reference)	Type of study	Participants	Disease / location of pain	Interventions	Main outcomes	Results	Main problems in the study
Naredo (16)	RCT (parallel group, two-arm randomised controlled trial)	US-guided group = 21 Blind injection group = 20	shoulder pain	triamcinolone 20 mg lateral approach, (to the subacromial-subdeltoid bursa) was used for the blind injection, while the US-guided procedure was both directed at the bursa and the biceps tendon (depending on where the effusion was localised) or peri or intralesional when rotator cuff calcifications were found	pain (VAS 0-100) and Function (Shoulder Assessment - SFA)	significantly greater improvement in SFA and VAS scores at weeks 6 for US-guided group needle placement was accurate in all of the patients of US-guided group, while only in 3/20 in blind group	patients with different causes of acute pain (impingement, rotator cuff tear, subacromial-subdeltoid bursitis, biceps tenosynovitis, while previous trauma or chronic inflammatory arthritis were excluded) were included different injection approaches were used
Ucuncu (2)	RCT (parallel group, two-arm randomised controlled clinical trial)	US-guided group = 30 Blind injection group = 30	shoulder pain	Triamcinolone 40 mg + 1 mL of 1% lidocaine lateral approach for the blind injection in the subacromial region, while the US-guided ones were administered perilesionally or intralesionally	pain (VAS score), shoulder function (Constant scale) and active and passive shoulder flexion and abduction (ROM)	significant improvement in Constant scale, ROM and VAS score in US-guided group	patients with different shoulder pathologic conditions (acromioclavicular degeneration, rotator cuff lesions - full or partial rupture, tendinosis, impingement, calcification - effusion in biceps tendon, partial tear of biceps tendon, bursitis) were enrolled and they were not randomised according to the real cause of the disease different injection approaches were used
Chen (17)	RCT (parallel group, two-arm controlled clinical trial)	US-guided group = 20 Blind injection group = 20	subacromial bursitis	1 mL of betamethasone + 1 mL of 1% lidocaine lateral approach in both groups	shoulder abduction (ROM) at one week	significantly improved only in the US-guided injection group	
Lee (18)	RCT (parallel group, two-arm controlled clinical trial)	US-guided group = 20 Blind injection group = 20 (Randomised = 42; 40 completed the study)	adhesive capsulitis	triamcinolone 20 mg + 1.5 mL of 2% lidocaine + 3 mL of normal saline (1 st week), followed by 5 hyaluronate injections (once a week) posterior approach in both groups	pain intensity (VAS), ROM (shoulder) flexion, abduction, external rotation, and internal rotation) and general shoulder function during daily activities at every week after injection for 6 weeks	significant improvement in pain intensity (in the first two weeks) and shoulder function score (in the first three weeks) in the US-guided group which had significantly better results in all of the three outcomes at the first week, when only CS were used	results (for CS injections alone) available only for the first week
Zuffray (20)	RCT (parallel group, two-arm randomised controlled clinical trial)	US-guided group = 32 Blind injection group = 33 (Randomised = 70; 67 completed the study and 2 more were lost to follow-up)	shoulder pain	2 mL of Diprophos® blind injections were directed to the bursa while US-guided injections were directed into the location assessed by US to be the cause of shoulder pain	pain (NRS) at 2 and 6 weeks, and function (shoulder ROM and Constant score) at 6 weeks	US injection group showed a significant reduction in night pain at 2 and 6 weeks	the patients were screened and enrolled in different centers, using different US machines the US scanning protocol could be not optimal (a minimum of six different views was allowed) Patients with different causes of pain were included (inflammatory arthritis and radiological gleno-humeral osteoarthritis were excluded)
Dogu (22)	RCT (parallel group, two-arm randomised controlled clinical trial)	US-guided group = 23 Blind injection group = 23 (Randomised = 50; 46 completed the study)	subacromial impingement syndrome	1 mL of 5 mg/mL betamethasone dipropionate + 9 mL of 10 mg/mL prilocaine hydrochloride posterior approach for the blind group and lateral for the US guided group	Function (ROM, ADLs score and Shoulder Disability Questionnaire) and pain (VAS) after 6 weeks	no difference in the main outcomes	different injection approaches were used the approach of the injection was different in the two groups the diagnosis of bursitis and tenosynovitis were given even in the presence of a tear of the rotator cuff blind injections were not really blind

der (20). Seventy patients were assessed clinically and by US. Blind approach was directed to the subacromial bursa while US-guided injections were directed into the location assessed by US as the cause of shoulder pain. The primary outcome was pain (assessed as vocal numerical rating scale (NRS) ranging from 0 to 10) at 2 and 6 weeks, and function (shoulder ROM and Constant score) at 6 weeks. The US injection group showed a significant reduction in night pain at 2 and 6 weeks (and it was the same for the number of good responders). In this study, the patients were screened and enrolled at two different centres, using different US machines, and using a scanning protocol that could be not optimal (minimum of six different views).

Short-term response to CS injection in subacromial impingement syndrome has been investigated by Dogu *et al.* (21), who compared the efficacy of a blind or US-guided approach. Forty-six patients were enrolled in this RCT to US-guided (group 1) or blind CS injections (group 2). MRI was used to assess whether the injection reached the subacromial space (every injection also contained gadolinium). No statistically significant difference was found in the accuracy of the injection location between the two groups (accurate injections were performed in 65% of patients in group 1 and 70% in group 2), nor were there any differences in improvement of the pain and functional status of the patients between the two groups. The problem with this study is that the approach of the injection was different (posterior for the blind group and lateral for the US guided group) and, in any case, the blind injections were not completely blind, but US-assisted. Besides, the diagnosis leaves some doubts: the definitions of bursitis and tenosynovitis were given even in the presence of a tear of the rotator cuff and, obviously, the efficacy of CS could be different with respect to the presence of an inflammation or a tendon tear.

Is a US-guided approach useful when injecting CS in the shoulder?

The published literature does not pro-

vide enough data to assess whether US-guided injections are more efficient in controlling shoulder pain with respect to the landmark approach. The two techniques are frequently not really comparable in the studies because not all of the anatomical structures can be reached using a lateral approach so, using different approaches (due to the different diseases) might not be appropriate from a methodological point of view. At the same time, effusion in the subacromial bursa could be due to either inflammation or secondary to rotator cuff disease; in this case, the effectiveness of CS injection could be different not only because of the different approach, but also because of the different pathogenesis.

What is likely to be true is the fact that US-guided technique shows a more rapid improvement, at least in some specific diseases (*i.e.* adhesive capsulitis). A possible explanation is that a greater anti-inflammatory effect may be achieved using the US-guided approach because of the higher CS volume injected right where it is needed. In 1997, Eustace *et al.* (11) demonstrated that an accurate injection improved shoulder function in patients with impingement syndrome. It is also true that, after a few days/weeks, CS may diffuse in the soft tissue and provide a beneficial effect independently of the initial location.

Finally, Sibbit *et al.* (22) found that US-guided injections not only improved clinical outcomes, but were also more cost-effective in inflammatory arthritis.

HA injection

Few papers have been published on the use of HA in the viscosupplementation of the shoulder for osteoarthritis (23-27), however, only a few authors have explored the field of HA shoulder injection using a US-guided approach (29).

Tagliafico *et al.* (28) first assessed whether US-guided viscosupplementation plus capsular distension could reduce pain and improve function in elderly patients with cuff tear arthropathy. A group of ninety-three patients aged over 65 years old, with massive rotator cuff tear were included in the prospective open-label non-randomised trial. Thirty-three patients

received one US-guided intra-articular injection of high molecular weight HA a week for two weeks, while the rest of the patients were considered as a control group. The Constant scores (for function) and VAS (for pain) were monthly outcomes up to six months. Patients treated with HA reported a significant decrease in VAS and Constant score every month, up to the fourth. After five months there were no differences between the two groups.

More recently, Park *et al.* in a prospective RCT, investigated the efficacy of US-guided intra-articular HA injection plus capsular distension, comparing it to the CS injection alone in patients with adhesive capsulitis of the shoulder. Ninety patients were assigned to the two groups: 45 patients in group A (treated with lidocaine + CS) and 45 patients in group B (treated with lidocaine plus HA and capsular distension) (29). All injections were performed every 2 weeks for a total of 3 times, using a posterior approach. The main outcomes were pain relief (VNS), functional improvement (Shoulder Pain and Disability Index (SPADI)) and passive ROM of the shoulder (flexion, abduction, external rotation) at 2 and 6 weeks after the last injections. All of the outcomes improved in both groups, however, only shoulder passive external rotation was significantly more improved in group B (both at 2 and 6 weeks).

Is US-guided approach useful when injecting HA in the shoulder?

Intra-articular HA injection represents a treatment option in the management of adhesive capsulitis of the shoulder, however its effect remains controversial. We know that, unlike steroids, HA cannot spread in the anatomic area providing efficacy when the target is not completely reached (30). Besides, incorrect placement can cause discomfort (24) so a more accurate injection using US guidance (and concurrent capsular distension) might be useful to improve the efficacy of such treatment. Unfortunately, nowadays, there are no studies comparing the blind approach to the US-guided one. However, we suppose that the US-guided technique has to become more and more used.

Injection of other substances

In 2010 Hashiuchi *et al.* (31), compared the efficacy of lidocaine injection when performed US-guided or blind. The study was carried out on 16 patients (20 shoulder), treated firstly using the US-guided technique and, one week later, the blind approach. To inject the subacromial bursa an antero-lateral approach was used for all the injections. Pain score, registered every 5 minutes for half an hour after the injection, was the primary outcome and significant differences, in favour of the US-guided injection, were registered at all time points. Fifteen out of the sixteen patients preferred the US-guided technique.

In the chronic stage of the impingement syndrome, tendons present changes described as tendinosis, similar to what is found in chronic painful Achilles and patellar tendons. A vasculo-neural ingrowth has been shown in those disorders and it seems to be related to pain. Previous studies demonstrated good short-term clinical effects with injections of the sclerosing substance polidocanol in chronic painful Achilles and patellar tendinopathy (32-34). Based on those data, Alfredson *et al.* treated 15 patients with a long duration of shoulder pain due to chronic painful shoulder impingement syndrome (35). Vascularity (neovessels) was found only in chronic painful supraspinatus tendons, and a US-guided injection of polidocanol was made, targeting the area with neovessels. The outcome was shoulder pain (VAS) after the injection and the patient's satisfaction was also assessed. Two (median; range 1-5) polidocanol treatments (with an interval of 4-8 weeks) were given. At follow-up, 8 (median; range 4-17) months after treatment, 14 patients were satisfied with the result and VAS was significantly reduced.

Another treatment proposed for the rotator cuff disease treatment is platelet-rich plasma (PRP) injection. This substance is expected to facilitate the healing of structures with poor vascularisation. Rha *et al.* (36) compared the efficacy of two PRP injections to two dry needling (or percutaneous microtenotomy) techniques; the last one is used to treat a chronic tendon injury

trying to change a chronic non-healing injury into an acute lesion with a potentially greater healing possibility. Thirty-nine patients with chronic pain due to supraspinatus tendon disease (tendinosis or little partial-thickness tear) were enrolled in the study and allocated to PRP injection or dry needle technique. The main outcome was the Shoulder Pain and Disability Index score (SPDI), which decreased in both arms of the study. For two weeks after the second injection, up to 6 months, the PRP group had a significantly better improvement of SPDI; internal rotation and flexion were also significantly improved in the PRP group at the three-month (both) and six-month (flexion only) follow-up visit.

Finally, we report the use of botulinum toxin type B (BT) for subacromial bursitis or impingement syndrome. Lee *et al.* recently compared BT to CS. Sixty-one patients were divided into 2 groups and treated with BT type B (BT group) or triamcinolone injection (TA group) using a US-guided approach (37). The outcomes considered were pain (NRS), active shoulder abduction angle, and the Disability of Arm, Shoulder, and Hand (DASH) score at 1 and 3 months after the treatment. Both groups improved in all of the outcomes and the BT group showed significantly better results on NRS and DASH at 3 months with respect to the TA group. No differences between the two groups were found after 1 month.

A similar study has recently been made by Joo *et al.*, but the use of BT type A failed to be superior with respect to CS, demonstrating similar efficacy (38).

Is US-guided approach useful when injecting other substances in the shoulder?

The few patients treated and the methodology of the studies preclude reaching any final conclusion, however, these new treatments for shoulder pain could be interesting but still need future validation in more appropriate RCTs.

Key messages

- The literature is not unequivocal in supporting the fact that the US-guided approach provides better results

than the blinded procedures (especially for soluble drugs such as CS)

- US-guided technique could represent an improvement in efficacy of injections for shoulder pain, mainly because it is more accurate in reaching the target, particularly for some specific sites and using specific medications (*i.e.* HA)
- US-guided technique provides the most suitable insertion for both the patient and the operator, determines a greater safety, and could reduce the risks (*i.e.* neuro-vascular bundle contact or intramuscular injections) and the patient's discomfort

References

1. POPE DP, CROFT PR, PRITCHARD CM *et al.*: The frequency of restricted range of movement in individuals with self-reported shoulder pain: results from a population-based survey. *Br J Rheumatol* 1996; 35: 1137-41.
2. UCUNCU F, CAPKIN E, KARKUCAK M *et al.*: A comparison of the effectiveness of landmark-guided injections and ultrasonography guided injections for shoulder pain. *Clin J Pain* 2009; 25: 786-9.
3. BUCHBINDER R, GREEN S, YOUND JM: Corticosteroid injections for shoulder pain. *Cochrane Database Syst Rev* 2003; CD004016.
4. KOESTER MC, DUNN WR, KUHN JE *et al.*: The efficacy of subacromial corticosteroid injection in the treatment of rotator cuff disease: a systematic review. *J Am Acad Orthop Surg* 2007; 15: 3-11.
5. MAMAN E, HARRIS C, WHITE L *et al.*: Outcome of non-operative treatment of symptomatic rotator cuff tears monitored by magnetic resonance imaging. *J Bone Joint Surg Am* 2009; 91: 1898-906.
6. ADEBAJO AO, NASH P, HAZLEMAN BL: A prospective double blind dummy placebo controlled study comparing triamcinolone hexacetomide injection with oral diclofenac 50mg TDS in patients with rotator cuff tendinitis. *J Rheumatol* 1990; 17: 207-10.
7. BLAIR B, ROKITO AS, CUOMO F *et al.*: Efficacy of injections of corticosteroids for subacromial impingement syndrome. *J Bone Joint Surg Am* 1996; 78: 1685-9.
8. VECCHIO P, KAVANAGH R, HAZLEMAN BL *et al.*: Shoulder pain in a community-based rheumatology clinic. *Br J Rheumatol* 1995; 34: 440-2.
9. HONG JY, YOON SH, MOON DO J, KWACK KS, JOEN B, LEE HY: Comparison of high- and low-dose corticosteroid in subacromial injection for periarticular shoulder disorder: a randomized, triple-blind, placebo-controlled trial. *Arch Phys Med Rehabil* 2011; 92: 1951-60.
10. OM EKEBERG, E BAUTZ-HOLTER, EK TVEIT, NG JUEL, S KVALHEIM, JI BROX: Subacromial ultrasound guided or systemic steroid injection for rotator cuff disease: randomised

- double blind study. *BMJ* 2009; 338: a3112.
11. EUSTACE JA, BROPHY DP, GIBNEY RP, BRESNIHAN B, FITZGERALD O: Comparison of the accuracy of steroid placement with clinical outcome in patients with shoulder symptoms. *Ann Rheum Dis* 1997; 56: 59-63.
 12. HEGEDUS EJ, ZAVALA J, KISSENBERTH M *et al.*: Positive outcomes with intra-articular glenohumeral injections are independent of accuracy. *J Shoulder Elbow Surg* 2010; 19: 795-801.
 13. SOH E, LI W, ONG KO, CHEN W, BAUTISTA D: Image-guided versus blind corticosteroid injections in adults with shoulder pain: a systematic review. *BMC Musculoskelet Disord* 2011; 12: 137.
 14. BLOOM JE, RISCHIN A, JOHNSTON RV, BUCHBINDER R: Image-guided versus blind glucocorticoid injection for shoulder pain. *Cochrane Database Syst Rev* 2012; 8: CD009147.
 15. SAGE W, PICKUP L, SMITH TO, DENTON ER, TOMS AP: The clinical and functional outcomes of ultrasound-guided vs landmark-guided injections for adults with shoulder pathology—a systematic review and meta-analysis. *Rheumatology (Oxford)* 2013; 52: 743-51.
 16. NAREDO E, CABERO F, BENEYTO P *et al.*: A randomized comparative study of short term response to blind injection versus sonographic-guided injection of local corticosteroids in patients with painful shoulder. *J Rheumatol* 2004; 31: 308-14.
 17. CHEN MJ, LEW HL, HSU TC *et al.*: Ultrasound-guided shoulder injections in the treatment of subacromial bursitis. *Am J Phys Med Rehabil* 2006; 85: 31-5.
 18. LEE HJ, LIM KB, KIM DY, LEE KT: Randomized controlled trial for efficacy of intra-articular injection for adhesive capsulitis: ultrasonography-guided versus blind technique. *Arch Phys Med Rehabil* 2009; 90: 1997-2002.
 19. EKEBERG OM, BAUTZ-HOLTER E, TVEITÅ EK, JUEL NG, KVALHEIM S, BROX JI: Subacromial ultrasound guided or systemic steroid injection for rotator cuff disease: randomised double blind study. *BMJ* 2009; 338: a3112.
 20. ZUFFEREY P, REVAZ S, DEGAILLER X, BALAGUE F, SO A: A controlled trial of the benefits of ultrasound-guided steroid injection for shoulder pain. *Joint Bone Spine* 2012; 79: 166-9.
 21. DOGU B, YUCEL SD, SAG SY, BANKAOGU M, KURAN B: Blind or ultrasound-guided corticosteroid injections and short-term response in subacromial impingement syndrome: a randomized, double-blind, prospective study. *Am J Phys Med Rehabil* 2012; 91: 658-65.
 22. SIBBIT WL, BAND PA, CHAVEZ-CHIANG NR *et al.*: A randomized controlled trial of the cost-effectiveness of ultrasound-guided intra-articular injection of inflammatory arthritis. *J Rheumatol* 2010; 38: 252-63.
 23. SILVERSTEIN E, LEGER R, SHEA KP: The use of intra-articular hylan G-F 20 in the treatment of symptomatic osteoarthritis of the shoulder: a preliminary study. *Am J Sports Med* 2008; 35: 979-85.
 24. LUSSIER A, CIVIDINO AA, MCFARLANE CA, OLSZYNSKI WP, POTASHNER WJ, DE MÉDICIS R: Viscosupplementation with hylan for the treatment of osteoarthritis: findings from clinical practice in Canada. *J Rheumatol* 1996; 23: 1579-85.
 25. NOËL E, HARDY P, HAGENA FW *et al.*: Efficacy and safety of Hylan G-F 20 in shoulder osteoarthritis with an intact rotator cuff. Open-label prospective multicenter study. *Joint Bone Spine* 2006; 76: 670-3.
 26. LEARDINI G, PERBELLINI A, FRANCESCHINI M *et al.*: Intra-articular injections of hyaluronic acid in the treatment of painful shoulder. *Clin Ther* 1998; 10: 521-6.
 27. BLAINE T, MOSKOWITZ R, UDELL J *et al.*: Treatment of persistent shoulder pain with sodium hyaluronate: a randomized, controlled trial. A multicenter study. *J Bone Joint Surg* 2008; 90: 970-9.
 28. TAGLIAFICO A, SERAFINI G, SCONFIENZA LM *et al.*: Ultrasound-guided viscosupplementation of subacromial space in elderly patients with cuff tear arthropathy using a high weight hyaluronic acid: prospective open-label non-randomized trial. *Eur Radiol* 2011; 21: 182-7.
 29. PARK KD, NAM HS, LEE JK, KIM YJ, PARK Y: Treatment effects of ultrasound-guided capsular distension with hyaluronic acid in adhesive capsulitis of the shoulder. *Arch Phys Med Rehabil* 2013; 94: 264-70.
 30. LUSSIER A, CIVIDINO AA, MCFARLANE CA, OLSZYNSKI WP, POTASHNER WJ, DE MÉDICIS R: Viscosupplementation with hylan for the treatment of osteoarthritis: findings from clinical practice in Canada. *J Rheumatol* 1996; 23: 1579-85.
 31. HASHIUCHI T, SAKURAI G, SAKAMOTO Y, TAKAKURA Y, TANAKA Y: Comparative survey of pain-alleviating effects between ultrasound-guided injection and blind injection of lidocaine alone in patients with painful shoulder. *Arch Orthop Trauma Surg* 2010; 130: 847-52.
 32. ALFREDSON H, OHBERG L: Sclerosing injections to areas of neovascularisation reduce pain in chronic Achilles tendinopathy: a double-blind randomized controlled trial. *Knee Surg Sports Traumatol Arthrosc* 2005; 13: 338-44.
 33. OHBERG L, ALFREDSON H: Ultrasound guided sclerosis of neovessels in painful chronic Achilles tendinosis: pilot study of a new treatment. *Br J Sports Med* 2002; 36: 173-7.
 34. OHBERG L, ALFREDSON H: Sclerosing therapy in chronic Achilles tendon insertional pain—results of a pilot study. *Knee Surg Sports Traumatol Arthrosc* 2003; 11: 339-43.
 35. ALFREDSON H, HARSTAD H, HAUGEN S, OHBERG L: Sclerosing polidocanol injections to treat chronic painful shoulder impingement syndrome—results of a two-centre collaborative pilot study. *Knee Surg Sports Traumatol Arthrosc* 2006; 14: 1321-6.
 36. RHA DW, PARK GY, KIM YK, KIM MT, LEE SC: Comparison of the therapeutic effects of ultrasound-guided platelet-rich plasma injection and dry needling in rotator cuff disease: a randomized controlled trial. *Clin Rehabil* 2013; 27: 113-22.
 37. LEE JH, LEE SH, SONG SH: Clinical effectiveness of botulinum toxin type B in the treatment of subacromial bursitis or shoulder impingement syndrome. *Clin J Pain* 2011; 27: 523-8.
 38. JOO YJ, YOON SJ, KIM CW *et al.*: A comparison of the short-term effects of a botulinum toxin type a and triamcinolone acetate injection on adhesive capsulitis of the shoulder. *Ann Rehabil Med* 2013; 37: 208-14.